
Etanercept therapy for toxic epidermal necrolysis

Andrea Paradisi, MD,^a Damiano Abeni, MD,^a Fabio Bergamo, MD,^b Francesco Ricci, MD,^c
Dario Didona, MD,^d and Biagio Didona, MD^b
Rome, Italy

Background: Toxic epidermal necrolysis (TEN) is a severe and potentially lethal drug reaction for which no standard treatment is available.

Objective: To describe a case series of patients with TEN treated with a single dose of etanercept.

Methods: We observed 10 consecutive patients with TEN. For each patient, we recorded the presence of comorbidities and all the drugs recently started (ie, in the last month). In all cases, 50 mg of etanercept was administered in a single subcutaneous injection. The clinical severity of disease was computed using the SCORe of Toxic Epidermal Necrosis (SCORTEN) scale. Using the probabilities of death linked to each level of SCORTEN score, we calculated the expected probability of death in our patients. Healing was defined as complete reepithelialization, and a time to healing curve was then obtained using the Kaplan–Meier method.

Results: All patients promptly responded to treatment, reaching complete reepithelialization without complications or side effects. The median time to healing was 8.5 days.

Limitations: This is a small, uncontrolled case series.

Conclusion: These preliminary results suggest the possibility that tumor necrosis factor–alpha may be an effective target for control of TEN, a dangerous skin condition for which no effective cure has yet been found. (*J Am Acad Dermatol* 2014;71:278-83.)

Key words: adverse drug reaction; etanercept; therapy; toxic epidermal necrolysis.

Toxic epidermal necrolysis (TEN), also known as Lyell syndrome, is a severe adverse drug reaction that is characterized by extensive skin necrosis and detachment of the epidermis and mucous membranes.¹ TEN is considered a medical emergency; its estimated incidence is 0.4 to 1.2 cases per million persons per year, and mortality rates range from 25% to 35%.²⁻⁴ Early symptoms can be nonspecific (eg, fever, stinging eyes, and dysphagia) and are followed by a widespread erythematous rash and livid macules that have a tendency to coalesce rapidly. In the next phase, symptoms include flaccid bullae, epidermal detachment over large

areas (>30% of the body surface area [BSA]), and painful hemorrhagic erosions of the mucous membranes in >90% of patients.⁵ TEN is an idiosyncratic drug reaction: allopurinol, antibiotics, anticonvulsants, and nonsteroidal antiinflammatory drugs seem to be the most common triggers.⁶ No treatment—including systemic steroids,⁷ which have been the standard therapy for TEN for about 20 years—has yet been shown to be effective in controlled clinical trials. Recently, encouraging but sporadic results of treatment with tumor necrosis factor–alpha (TNF- α) antagonists have been described in the international literature.⁸⁻¹⁸

From the Health Services Research Unit^a and the I Division of Dermatology,^b IDI-IRCCS, and the Departments of Dermatology, Catholic University of the Sacred Heart^c and “La Sapienza” University,^d Rome.

Supported in part by the “Progetto Ricerca Corrente 2014” given by the Italian Ministry of Health to the Health Services Research Unit of the IDI-IRCCS, Rome, Italy (grant number Progetto Ricerca Corrente 2012: 5.3 [Strumenti e misure per la descrizione e la valutazione della gravità delle malattie dermatologiche]).

Conflicts of interest: None declared.

Accepted for publication April 15, 2014.

Correspondence to: Andrea Paradisi, MD, Health Services Research Unit, IDI-IRCCS, Via dei Monti di Creta 104, 00168 Rome, Italy.

E-mail: aparad@tin.it.

Published online June 10, 2014.

0190-9622/\$36.00

© 2014 by the American Academy of Dermatology, Inc.

<http://dx.doi.org/10.1016/j.jaad.2014.04.044>

The aim of this study was to evaluate the efficacy and safety of etanercept in a series of TEN patients.

METHODS

We observed 10 consecutive patients who were hospitalized with TEN at the IDI-IRCCS dermatologic institute in Rome, Italy, between 2011 and 2012. We obtained written informed consent from all patients for treatment with etanercept. The compassionate use of etanercept for TEN had been approved by the Ethical Committee of the IDI-IRCCS.

On admission, when a diagnosis of TEN was hypothesized, information on all probable causative medications was collected, and such treatments were immediately stopped.

All patients underwent the following examinations:

routine blood tests, immunologic tests (ie, antinuclear antibodies, anti-extractable nuclear antigen antibodies, antiskin antibodies [ASA-IIF], antidesmogleins 1 and 3, anti-BPs 180 and 230, serology for hepatitis C and B viruses, and HIV infection, Quantiferon test), chest radiographs, electrocardiography, and cardiologic evaluation.

For each patient, we recorded the presence of comorbidities and all of the drugs recently started (ie, in the last month).

TEN was diagnosed clinically according to the following criteria: denudation of the epidermis in sheets during the acute phase, with blisters and erosions covering >30% of the BSA, often with a positive Nikolsky sign.⁴ Moreover, other common clinical features of TEN have been evaluated, such as painful inflammation and ulceration of the mucosal surfaces and ocular and genital involvement. When the clinical features were not clear-cut characteristics of TEN, the suspected diagnosis was confirmed histologically.

All patients were given intravenous fluid replacement, aseptic handling, and nutritional support. However, given the great diversity of the problems posed by each case, no standard approach was adopted; rather, supportive therapy was tailored to the needs of each patient. In all cases, 50 mg of etanercept was administered in a single subcutaneous injection. All patients were treated as soon as possible, and invariably within 6 hours from hospitalization. The time from symptom onset is not known precisely, but patients

were usually referred to our center within 72 hours of symptom onset.

The clinical severity of disease was computed using the SCORE of Toxic Epidermal Necrosis (SCORTEN) scale.¹⁹ The scale ranges from 0 to 7 and attributes 1 point for the presence of each of the following 7 items: age >40 years; heart rate >120

beats per minute; the presence of malignancies; BSA involvement >10%; serum urea >10 mmol/L; serum bicarbonate <20 mmol/L; and serum glucose >14 mmol/L.

Using the probabilities of death linked to each level of SCORTEN score, published in the original validation study, we calculated the expected probability of death in our patients.

Healing was defined as complete reepithelialization (ie, the complete absence of erosions), and time to heal-

ing was recorded for each patient. A time to healing curve was then obtained using the Kaplan–Meier product-limit estimates method.²⁰

RESULTS

The single components of the SCORTEN for each patient are shown in [Table I](#). Three patients were in the higher category of SCORTEN severity (ie, a score ≥ 5), while no patient was in the lower category (ie, a score of 0-1).

Other important characteristics of the patients (ie, sex, age, comorbidities, culprit drugs, and time to healing) are summarized in [Table II](#).

Nine patients presented with comorbidities, which were considered severe in 8 cases. Three patients had malignancies: 2 had a primary cerebral neoplasm and 1 had a brain metastasis from breast cancer. The drug most frequently involved in triggering TEN was carbamazepine, which is used to prevent epileptic seizures.

All patients promptly responded to treatment, reaching complete reepithelialization without complications or side effects ([Fig 1](#)). The exact binomial 95% confidence interval for the observed proportion of deaths (ie, 0) ranges from 0% to 30.8%, which does not contain the expected probability of death in our sample, computed on the basis of patients' SCORTEN scores (46.9%).

Time to healing ranged from 7 to 20 days (median, 8.5 days). The Kaplan–Meier curve for all observations is shown in [Fig 2](#).

CAPSULE SUMMARY

- Toxic epidermal necrolysis is a severe, potentially lethal drug reaction for which no effective cure has yet been found.
- Ten patients with toxic epidermal necrolysis treated with a single dose of etanercept (50 mg) showed complete healing without complications or side effects.
- Tumor necrosis factor– α may be an effective new therapeutic approach for toxic epidermal necrolysis.

Table I. Detail of the SCORTEN components and SCORTEN scores in 10 patients with toxic epidermal necrolysis treated with etanercept

SCORTEN components	Patient no.									
	1	2	3	4	5	6	7	8	9	10
Age >40 y	1	1	0	1	1	1	1	1	1	1
Heart rate >120 beats/min	1	0	1	1	1	1	0	0	0	0
Cancer or hematologic malignancy	1	0	0	0	0	1	0	1	0	0
>10% body surface area involvement	1	1	1	1	1	1	1	1	1	1
Serum urea level >10 mmol/L	1	1	0	0	0	0	0	1	0	0
Serum bicarbonate level <20 mmol/L	1	0	0	0	0	0	0	1	0	0
Serum glucose level >14 mmol/L	0	0	0	0	1	1	0	1	0	1
SCORTEN score	6	3	2	3	4	5	2	6	2	3

SCORTEN, SCORe of Toxic Epidermal Necrosis.

DISCUSSION

In our series of TEN patients treated with a single dose of etanercept, healing was obtained in all cases without severe side effects.

Findings reporting increased levels of TNF- α in skin biopsy specimens²¹ or in blister fluid and serum²² of TEN patients encouraged the adoption of biologic therapy with anti-TNF- α monoclonal antibodies (infliximab) or with a soluble fusion protein binding to human TNF- α (etanercept). Although reports of TEN managed with biologic agents are scarce, the present study confirms the reported effectiveness of anti-TNA- α drugs.⁸⁻¹⁸

Only 2 patients with TEN treated with 2 doses of etanercept (25 mg/day on days 4 and 8¹⁶ and at an interval of 1 day,¹⁷ respectively) have been described. In the first patient,¹⁶ who had previously been treated with corticosteroids without benefit, epidermal detachment ceased within 24 hours of the first dose. Unfortunately, he then died of disseminated intravascular coagulation 10 days after admission. The other patient¹⁷ was given corticosteroids both previously and simultaneously with etanercept, and epidermal detachment stopped 2 days after the first etanercept injection. A patient with acute generalized exanthematous pustulosis/TEN overlap syndrome¹⁸ was successfully treated with etanercept 25 mg (twice in a week), with disease arrest being achieved within 48 hours of the first injection.

Although these case reports describe promising outcomes, none were controlled studies, and the overall patient number is still small. Nonetheless, such outcomes are much more favorable than those obtained with “standard” approaches.²³⁻³⁹

Table II. Patients with toxic epidermal necrolysis treated with etanercept: Sex, age, comorbidities, culprit drugs, and time to healing

	Patient no.									
	1	2	3	4	5	6	7	8	9	10
Gender	F	M	F	F	M	M	F	F	M	F
Age, y	57	70	28	62	73	78	72	50	71	55
Culprit drug	Carbamazepine	Ofloxacin	Lansoprazole, azathioprine	Methylprednisolone	Ciprofloxacin	Carbamazepine	Phytotherapy product	Carbamazepine	Carbamazepine	Diclofenac
Time to healing (days)	12	8	8	12	8	7	8	20	9	9
Comorbidities	Cerebral neoplasm	Bronchopneumonia	Systemic lupus erythematosus	Pemphigus vulgaris	Bronchopneumonia	Cerebral neoplasm	—	Cerebral metastases (breast cancer)	Intracranial hemorrhage (head trauma)	Periarthritis

F, Female; M, male.

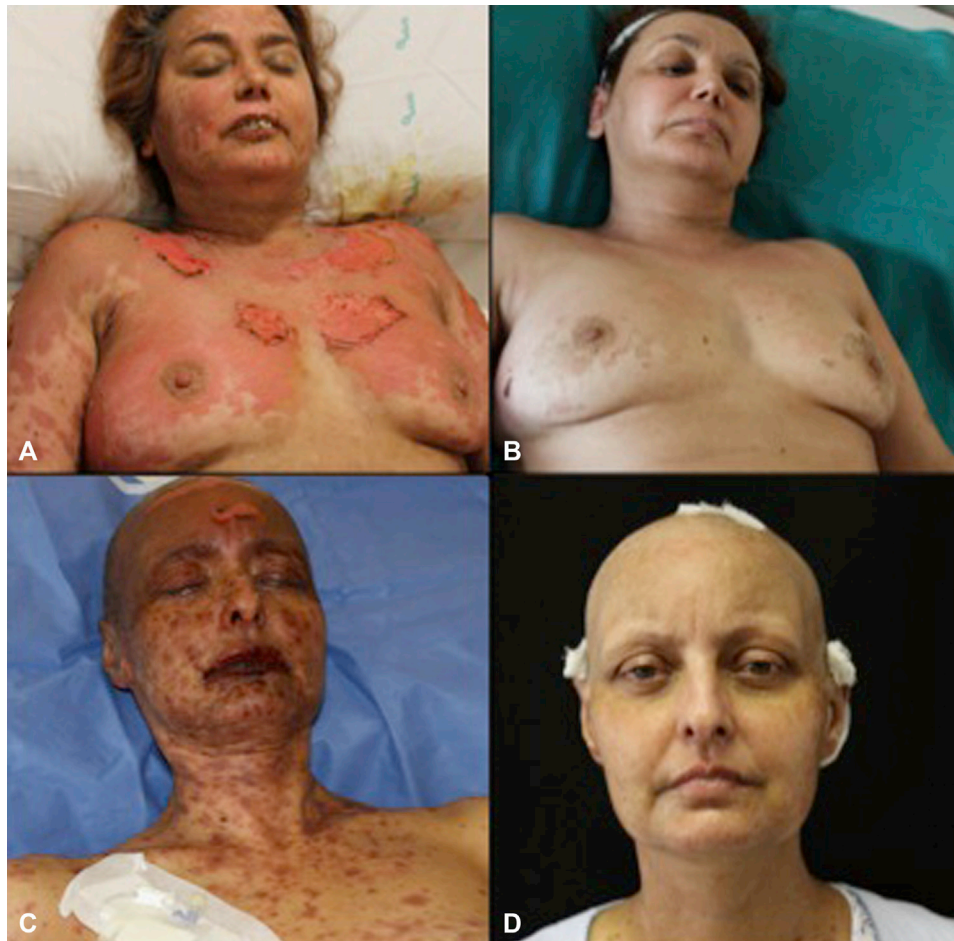

Fig 1. Two patients with toxic epidermal necrolysis before (**A** and **C**) and after treatment with a 50 mg single-dose subcutaneous injection of etanercept (**B** and **D**), respectively.

The pathogenesis of TEN is unclear. The observations that TEN recurrence is faster and more severe if the patient is reexposed to the culprit drug⁴⁰; that drug-specific T cells are found in the skin of TEN patients⁴¹; and that patients with certain human leukocyte antigen haplotypes are at a greater risk of developing TEN when exposed to certain drugs^{42,43} strongly support a role for T cell-mediated immune responses in its pathogenesis. However, the immune cell infiltration (including cytotoxic T cells) found in the skin of TEN patients seems insufficient to induce massive keratinocyte apoptosis, suggesting that some cytotoxic proteins and/or cytokines may amplify the process. The upregulation of FasL expression on the surface of keratinocytes from TEN patients has been shown to induce keratinocyte apoptosis by engaging constitutively expressed Fas.⁴⁴ A recent study⁴⁵ has advanced the hypothesis of a link between the drug-specific immune response and the induction of target cell death by apoptotic molecules (including FasL) by positing a role for inducible nitric oxide synthase

(iNOS). iNOS is significantly increased in the epidermis of TEN patients,⁴⁶ and in keratinocytes it is regulated by interferon-gamma and TNF- α , whose levels in blister fluid from TEN patients are increased.^{47,48} According to the aforementioned construct, an iNOS/nitric oxide/FasL pathway might link the immune activation and the widespread keratinocyte apoptosis seen in TEN: the authors⁴⁵ noted that activated T cells secrete large amounts of TNF- α and interferon-gamma, which have the ability to induce iNOS expression and nitric oxide production by keratinocytes, resulting in FasL upregulation and Fas-mediated keratinocyte apoptosis. Etanercept therapy would act by blocking this inflammatory pathway via TNF- α inhibition.

It is also noteworthy that etanercept, in addition to TNF- α , also blocks lymphotoxin α (LFT- α), which has been recently reported to play an important role in the pathogenesis of graft-versus-host disease,⁴⁹ which shares clinical,⁵⁰ histologic, and pathogenetic^{51,52} resemblances to TEN. We therefore believe that LFT- α could play a role in TEN pathogenesis,

Time-to-healing in 10 patients with toxic epidermal necrolysis treated with etanercept

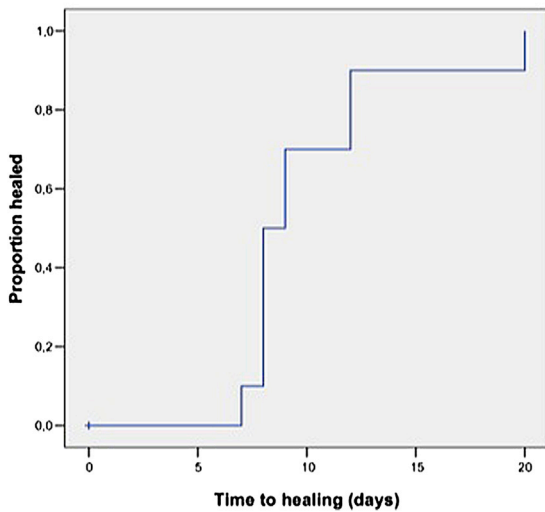


Fig 2. Kaplan-Meier curve for time to healing (days) in 10 patients with toxic epidermal necrolysis treated with Etanercept.

and its block, together with that of TNF- α , may be at least partially linked to the robust and rapid therapeutic effect of etanercept seen in our patients.

The present study is small and lacks a control group. However, to the best of our knowledge, this is the largest series of TEN patients to have been treated with a biologic agent. Moreover, despite the small sample size, the upper 95% confidence interval for the 0 observed deaths (30.8%) is well below the expected probability of death computed in our sample on the basis of patients' SCORTEN scores (46.9%). In addition, given the high expected probability of death among patients undergoing the "standard" treatments, it may actually be unethical to assign patients to a control group.

The present study is also characterized by a number of advantages, because it was not only carried out at a single institution, but also in a single clinical unit; this entails that all patients were seen by the same dermatologists, observed in the same environmental conditions, and treated in a standardized manner consisting of a single dose of etanercept, while all other TEN medications were withdrawn.

We hope that these results may encourage other clinicians to test this therapeutic approach, which may provide a breakthrough for a dangerous skin condition for which no effective cure has yet been found.

We thank Moira Egan for editing the final version of the manuscript.

REFERENCES

1. Lyell A. Toxic epidermal necrolysis: an eruption resembling scalding of the skin. *Br J Dermatol* 1956;68:355-61.
2. Roujeau JC, Chosidow O, Saiag P, Guillaume JC. Toxic epidermal necrolysis (Lyell syndrome). *J Am Acad Dermatol* 1990;23:1039-58.
3. Roujeau JC, Guillaume JC, Fabre JP, Penso D, Fléchet ML, Girre JP. Toxic epidermal necrolysis (Lyell syndrome). Incidence and drug etiology in France, 1981-1985. *Arch Dermatol* 1990;126:37-42.
4. Schwartz RA, McDonough PH, Lee BW. Toxic epidermal necrolysis. Part I. *J Am Acad Dermatol* 2013;173:e1-13.
5. Harr T, French LE. Stevens-Johnson syndrome and toxic epidermal necrolysis. *Chem Immunol Allergy* 2012;97:149-66.
6. Mockenhaupt M. Epidemiology of cutaneous adverse drug reactions. *Chem Immunol Allergy* 2012;97:1-17.
7. Fernando SL. The management of toxic epidermal necrolysis. *Australas J Dermatol* 2012;53:165-71.
8. Fischer M, Fiedler E, Marsch WC, Wohlrab J. Antitumour necrosis factor-alpha antibodies (infliximab) in the treatment of a patient with toxic epidermal necrolysis. *Br J Dermatol* 2002;146:707-9.
9. Hunger RE, Hunziker T, Buettiker U, Braathen LR, Yawalkar N. Rapid resolution of toxic epidermal necrolysis with anti-TNF-alpha treatment. *J Allergy Clin Immunol* 2005;116:923-4.
10. Wojtkiewicz A, Wysocki M, Fortuna J, Chrupek M, Matczuk M, Koltan A. Beneficial and rapid effect of infliximab on the course of toxic epidermal necrolysis. *Acta Derm Venereol* 2008;88:420-1.
11. Kreft B, Wohlrab J, Bramsiepe I, Eismann R, Winkler M, Marsch WC. Etoricoxib-induced toxic epidermal necrolysis: successful treatment with infliximab. *J Dermatol* 2010;37:904-6.
12. Worsnop F, Wee J, Natkunarajah J, Moosa Y, Marsden R. Reaction to biological drugs: infliximab for the treatment of toxic epidermal necrolysis subsequently triggering erosive lichen planus. *Clin Exp Dermatol* 2012;37:879-81.
13. Al-Shouli S, Abouchala N, Bogusz MJ, Al Tufail M, Thestrup-Pedersen K. Toxic epidermal necrolysis associated with high intake of sildenafil and its response to infliximab. *Acta Derm Venereol* 2005;85:534-5.
14. Meiss F, Helmbold P, Meykadeh N, Gaber G, Marsch WC, Fischer M. Overlap of acute generalized exanthematous pustulosis and toxic epidermal necrolysis: response to antitumour necrosis factor-alpha antibody infliximab: report of three cases. *J Eur Acad Dermatol Venereol* 2007;21:717-9.
15. Gaitanis G, Spyridonos P, Patmanidis K, Koulouras V, Nakos G, Tzaphlidou M, et al. Treatment of toxic epidermal necrolysis with the combination of infliximab and high-dose intravenous immunoglobulin. *Dermatology* 2012;224:134-9.
16. Famularo G, Di Dona B, Canzona F, Girardelli CR, Cruciani G. Etanercept for toxic epidermal necrolysis. *Ann Pharmacother* 2007;41:1083-4.
17. Gubinelli E, Canzona F, Tonanzi T, Raskovic D, Didona B. Toxic epidermal necrolysis successfully treated with etanercept. *J Dermatol* 2009;36:150-3.
18. Sadighha A. Etanercept in the treatment of a patient with acute generalized exanthematous pustulosis/toxic epidermal necrolysis: definition of a new model based on translational research. *Int J Dermatol* 2009;48:913-4.
19. Bastuji-Garin S, Fouchar N, Bertocchi M, Roujeau JC, Revuz J, Wolkenstein P. SCORTEN: a severity-of-illness score for toxic epidermal necrolysis. *J Invest Dermatol* 2000;115:149-53.

20. Kaplan EL, Meier P. Nonparametric estimation from incomplete observations. *J Am Stat Assoc* 1958;53:457-81.
21. Paquet P, Paquet F, Al Saleh W, Reper P, Vanderkelen A, Piérard GE. Immunoregulatory effector cells in drug-induced toxic epidermal necrolysis. *Am J Dermatopathol* 2000;22:413-7.
22. Posadas SJ, Padial A, Torres MJ, Mayorga C, Leyva L, Sanchez E, et al. Delayed reactions to drugs show levels of perforin, granzyme B, and Fas-L to be related to disease severity. *J Allergy Clin Immunol* 2002;109:155-61.
23. Lee HY, Dunant A, Sekula P, Mockenhaupt M, Wolkenstein P, Valeyrie-Allanore L, et al. The role of prior corticosteroid use on the clinical course of Stevens-Johnson syndrome and toxic epidermal necrolysis: a case-control analysis of patients selected from the multinational EuroSCAR and RegiSCAR studies. *Br J Dermatol* 2012;167:555-62.
24. Yamane Y, Aihara M, Tatewaki S, Matsukura S, Kanbara T, Yamakawa Y, et al. Analysis of treatments and deceased cases of severe adverse drug reactions—analysis of 46 cases of Stevens-Johnson syndrome and toxic epidermal necrolysis. *Arerugi* 2009;58:537-47.
25. Mockenhaupt M. Severe drug-induced skin reactions: clinical pattern, diagnostics and therapy. *J Dtsch Dermatol Ges* 2009;7:142-60.
26. Ghislain PD, Roujeau JC. Treatment of severe drug reactions: Stevens—Johnson syndrome, toxic epidermal necrolysis and hypersensitivity syndrome. *Dermatol Online J* 2002;8:5.
27. Valeyrie-Allanore L, Wolkenstein P, Brochard L, Ortonne N, Maitre B, Revuz J, et al. Open trial of ciclosporin treatment for Stevens-Johnson syndrome and toxic epidermal necrolysis. *Br J Dermatol* 2010;163:847-53.
28. Ballow M. The IgG molecule as a biological immune response modifier: mechanisms of action of intravenous immune serum globulin in autoimmune and inflammatory disorders. *J Allergy Clin Immunol* 2011;127:315-23.
29. Campione E, Marulli GC, Carrozzo AM, Chimenti MS, Costanzo A, Bianchi L. High-dose intravenous immunoglobulin for severe drug reactions: efficacy in toxic epidermal necrolysis. *Acta Derm Venereol* 2003;83:430-2.
30. Prins C, Vittorio C, Padilla RS, Hunziker T, Itin P, Förster J, et al. Effect of high-dose intravenous immunoglobulin therapy in Stevens-Johnson syndrome: a retrospective, multicenter study. *Dermatology* 2003;207:96-9.
31. Trent JT, Kirsner RS, Romanelli P, Kerdel FA. Use of SCORTEN to accurately predict mortality in patients with toxic epidermal necrolysis in the United States. *Arch Dermatol* 2004;140:890-2.
32. French LE, Trent JT, Kerdel FA. Use of intravenous immunoglobulin in toxic epidermal necrolysis and Stevens-Johnson syndrome: our current understanding. *Int Immunopharmacol* 2006;6:543-9.
33. Al-Mutairi N, Arun J, Osama NE, Amr Z, Mazen AS, Ibtisam el-A, et al. Prospective, noncomparative open study from Kuwait of the role of intravenous immunoglobulin in the treatment of toxic epidermal necrolysis. *Int J Dermatol* 2004;43:847-51.
34. Schneck J, Fagot JP, Sekula P, Sassolas B, Roujeau JC, Mockenhaupt M. Effects of treatments on the mortality of Stevens-Johnson syndrome and toxic epidermal necrolysis: a retrospective study on patients included in the prospective EuroSCAR Study. *J Am Acad Dermatol* 2008;58:33-40.
35. Bachot N, Revuz J, Roujeau JC. Intravenous immunoglobulin treatment for Stevens-Johnson syndrome and toxic epidermal necrolysis: a prospective noncomparative study showing no benefit on mortality or progression. *Arch Dermatol* 2003;139:33-6.
36. Brown KM, Silver GM, Halerz M, Walaszek P, Sandroni A, Gamelli RL. Toxic epidermal necrolysis: does immunoglobulin make a difference? *J Burn Care Rehabil* 2004;25:81-8.
37. Shortt R, Gomez M, Mittman N, Cartotto R. Intravenous immunoglobulin does not improve outcome in toxic epidermal necrolysis. *J Burn Care Rehabil* 2004;25:246-55.
38. Pasic S. Intravenous immunoglobulin in toxic epidermal necrolysis. *Int J Dermatol* 2006;45:1117-8.
39. Faye O, Roujeau JC. Treatment of epidermal necrolysis with high-dose intravenous immunoglobulins (IV Ig): clinical experience to date. *Drugs* 2005;65:2085-90.
40. Paquet P, Jacob E, Damas P, Piérard GE. Recurrent fatal drug-induced toxic epidermal necrolysis (Lyell's syndrome) after putative beta-lactam cross-reactivity: case report and scrutiny of antibiotic imputability. *Crit Care Med* 2002;30:2580-3.
41. Nassif A, Bensussan A, Boumsell L, Deniaud A, Moslehi H, Wolkenstein P, et al. Toxic epidermal necrolysis: effector cells are drug-specific cytotoxic T cells. *J Allergy Clin Immunol* 2004;114:1209-15.
42. Chung WH, Hung SI, Hong HS, Hsieh MS, Yang LC, Ho HC, et al. Medical genetics: a marker for Stevens-Johnson syndrome. *Nature* 2004;428:486.
43. Hung SI, Chung WH, Liou LB, Chu CC, Lin M, Huang HP, et al. HLA-B*5801 allele as a genetic marker for severe cutaneous adverse reactions caused by allopurinol. *Proc Natl Acad Sci U S A* 2005;102:4134-9.
44. Viard-Leveugle I, Bullani RR, Meda P, Micheau O, Limat A, Saurat JH, et al. Intracellular localization of keratinocyte Fas ligand explains lack of cytolytic activity under physiological conditions. *J Biol Chem* 2003;278:16183-8.
45. Viard-Leveugle I, Gaide O, Jankovic D, Feldmeyer L, Kerl K, Pickard C, et al. TNF- α and IFN- γ are potential inducers of Fas-mediated keratinocyte apoptosis through activation of inducible nitric oxide synthase in toxic epidermal necrolysis. *J Invest Dermatol* 2013;133:489-98.
46. Lerner LH, Qureshi AA, Reddy BV, Lerner EA. Nitric oxide synthase in toxic epidermal necrolysis and Stevens-Johnson syndrome. *J Invest Dermatol* 2000;114:196-9.
47. Nassif A, Moslehi H, Le Gouvello S, Bagot M, Lyonnet L, Michel L, et al. Evaluation of the potential role of cytokines in toxic epidermal necrolysis. *J Invest Dermatol* 2004;123:850-5.
48. Gandhi M, Kowal-Vern A, An G, Hanumadass M. Blister fluid composition in a pediatric patient with toxic epidermal necrolysis. *J Burn Care Res* 2008;29:671-5.
49. Markey KA, Burman AC, Banovic T, Kuns RD, Raffelt NC, Rowe V, et al. Soluble lymphotoxin is an important effector molecule in GVHD and GVL. *Blood* 2010;115:122-32.
50. Villada G, Roujeau JC, Cordonnier C, Bagot M, Kuentz M, Wechsler J, et al. Toxic epidermal necrolysis after bone marrow transplantation: study of nine cases. *J Am Acad Dermatol* 1990;23(5 pt 1):870-5.
51. Correia O, Delgado L, Ramos JP, Resende C, Torrinha JA. Cutaneous T-cell recruitment in toxic epidermal necrolysis. Further evidence of CD8+ lymphocyte involvement. *Arch Dermatol* 1993;129:466-8.
52. French LE, Tschopp J. Fas-mediated cell death in toxic epidermal necrolysis and graft-versus-host disease: potential for therapeutic inhibition. *Schweiz Med Wochenschr* 2000;130:1656-61.