

Selected Readings in Plastic Surgery

Volume 10, Number 1

2004

SKIN GRAFTS AND SKIN SUBSTITUTES AND PRINCIPLES OF FLAPS

James F Thornton MD

Amanda A Gosman MD

SOUTHWESTERN

THE UNIVERSITY OF TEXAS
SOUTHWESTERN MEDICAL CENTER
AT DALLAS

 **BAYLOR UNIVERSITY
MEDICAL CENTER**
An Affiliate of the
Baylor Health Care System

SKIN GRAFTS AND SKIN SUBSTITUTES

James F Thornton MD

HISTORY OF SKIN GRAFTS

Ratner¹ and Hauben and colleagues² give excellent overviews of the history of skin grafting. The following highlights are excerpted from these two sources.

Grafting of skin originated among the tilemaker caste in India approximately 3000 years ago.¹ A common practice then was to punish a thief or adulterer by amputating the nose, and surgeons of their day took free grafts from the gluteal area to repair the deformity. From this modest beginning, skin grafting evolved into one of the basic clinical tools in plastic surgery.

In 1804 an Italian surgeon named Boronio successfully autografted a full-thickness skin graft on a sheep. Sir Astley Cooper grafted a full-thickness piece of skin from a man's amputated thumb onto the stump for coverage. Bunker in 1823 successfully reconstructed a nose with a skin graft. In 1869 Reverdin rekindled worldwide interest in skin grafting with his report of successful pinch grafts. Ollier in 1872 pointed out the importance of the dermis in skin grafts, and in 1886 Thiersch used thin split-thickness skin to cover large wounds. To this day the names Ollier and Thiersch are synonymous with thin (0.005–0.01-inch) split-thickness grafts.

Lawson, Le Fort, and Wolfe used full-thickness grafts to successfully treat ectropion of the lower eyelid; nevertheless, it is Wolfe whose name is generally associated with the concept of full-thickness skin grafting. Krause popularized the use of full-thickness grafts in 1893, known today as Wolfe-Krause grafts.

Brown and McDowell³ reported using thick split-thickness grafts (0.01–0.022-inch) for the treatment of burns in 1942.

In 1964 Tanner, Vandeput, and Olley⁴ gave us the technology to expand skin grafts with a machine that would cut the graft into a lattice pattern, expanding it up to 12X its original surface area.

In 1975 epithelial skin culture technology was published by Rheinwald and Green,⁵ and in 1979 cultured human keratinocytes were grown to form an epithelial layer adequate for grafting wounds.⁶

ANATOMY

The character of the skin varies greatly among individuals, and within each person it varies with age, sun exposure, and area of the body. For the first decade of life the skin is quite thin, but from age 10 to 35 it thickens progressively. At some point during the fourth decade the thickening stops and the skin once again begins to decrease in substance. From that time until the person dies there is gradual thinning of dermis, decreased skin elasticity, and progressive loss of sebaceous gland content.

The skin also varies greatly with body area. Skin from the eyelid, postauricular and supraclavicular areas, medial thigh, and upper extremity is thin, whereas skin from the back, buttocks, palms of the hands and soles of the feet is much thicker.

Approximately 95% of the skin is dermis and the other 5% is epidermis.⁷ The dermis contains sebaceous glands and the subcutaneous fat beneath the dermis contains sweat glands and hair follicles. The skin vasculature is superficial to the superficial fascia and parallels the skin surface. The cutaneous vessels branch at right angles to penetrate subcutaneous tissue and arborize in the dermis. The final destination of these blood vessels is a capillary tuft that terminates between the dermal papillae.

TERMINOLOGY

An *autograft* is a graft taken from one part of an individual's body that is transferred to a different part of the body of that same individual. An *isograft* is a graft from genetically identical donor and recipient individuals, such as litter mates of inbred rats or identical human twins. An *allograft* (previously homograft) is taken from another individual of the same species. A *xenograft* (heterograft) is a graft taken from an individual of one species that is grafted onto an individual of a different species.

A *split-thickness skin graft (STSG)* contains epidermis and a variable amount of dermis. A *full-thickness skin graft (FTSG)* includes *all* of the dermis as well as the epidermis⁸ (Fig 1). The donor site

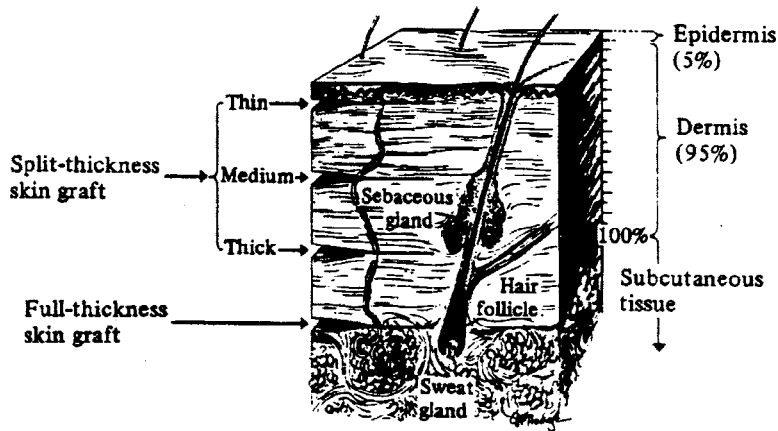


Fig 1. Split-thickness skin grafts include a variable amount of dermis. Full-thickness grafts are taken with all the dermis. (Reprinted with permission from Grabb WC: *Basic Techniques of Plastic Surgery*. In: Grabb WC and Smith JW: *Plastic Surgery*, 3rd Ed. Boston, Little Brown, 1979.)

of an FTSG must be closed by either direct suture approximation or skin graft.

PROPERTIES OF SKIN GRAFTS

Skin grafts have been used for over a century to resurface superficial defects of many kinds. Whether intended for temporary or permanent cover, the transplanted skin does not only protect the host bed from further trauma, but also provides an important barrier to infection.

Thin split-thickness skin grafts have the best “take” and can be used under unfavorable conditions that would spell failure for thicker split-skin grafts or full-thickness grafts. Thin STSGs tend to shrink considerably, pigment abnormally, and are susceptible to trauma.⁹ In contrast, full-thickness grafts require a well-vascularized recipient bed⁹ until graft perfusion has been reestablished. FTSGs contract less upon healing, resist trauma better, and generally look more natural after healing than STSGs.

Rudolph and Klein⁹ review the biologic events that take place in a skin graft and its bed. An ungrafted wound bed is essentially a healing wound which, left alone, will undergo the typical processes of granulation, contraction, and reepithelialization to seal its surface. When a skin graft is placed on a wound bed, these processes are altered by the presence of the graft.¹⁰

Marckmann¹¹ studied biochemical changes in a skin graft after placement on a wound bed and noted similarities with normal skin in its response to physical or chemical injury and aging. The changes in wound healing brought about by the skin graft

can also be described as a general adaptation of connective tissue to a diminished blood supply.¹¹

EPIDERMIS

In the mid-1940s Medawar studied the behavior and fate of healing skin autografts.¹²⁻¹⁴ His findings can be summarized as follows.

Histologic Aspects

During the first 4 days postgraft there is tremendous activity in the graft epithelium, which doubles in thickness and shows crusting and scaling of the graft surface. Three cellular processes may explain this thickening: 1) swelling of the nuclei and cytoplasm of epithelial cells; 2) epithelial cell migration toward the surface of the graft; and 3) accelerated mitosis of follicular and glandular cells.¹⁰ By the third day after grafting there is considerable mitotic activity in the epidermis of a split-thickness skin graft, whereas mitotic activity in full-thickness skin grafts is much less common and may be totally absent—a reflection of their less-efficient early circulation.

Between the fourth and eighth days after grafting there is great proliferation and thickening of the graft epithelium associated with obvious desquamation. Epithelial thickness may increase up to sevenfold, with rapid cellular turnover. At the same time the surface layer of epithelium exfoliates and is replaced by upwardly migrating cells of follicular epithelium at an accelerated rate. This heightened mitosis does not begin to regress until after the first week postgrafting. By the end of the fourth week

postgraft the epidermal thickness has returned to its normal, pregraft state.

Histochemical Aspects

The RNA content of graft epithelial cells changes little in the first few days postgraft.¹⁵ By the fourth day postgraft RNA content increases greatly in the basal layers of epithelium, paralleling the hyperactivity of epithelial cells caused by acceleration of protein synthesis during a period of rapid cellular replication. By the 10th day postgraft the RNA level returns to normal.¹⁵

Over the first 2 to 3 days enzymatic activity progressively decreases in split-thickness skin grafts, but as new blood vessels enter the dermis–epidermis junction, the enzyme levels rebound.

DERMIS

Cellular component

The source of fibroblasts in a skin graft remains obscure.¹⁶ Early investigators believed that these cells came from large mononuclear cells in the blood, while Grillo¹⁷ theorized that they originated from local perivascular mesenchymal cells. Whatever their origin, most authors are convinced that active fibroblasts in a healing skin graft do **not** come from indigenous fibrocytes.

Converse and Ballantyne¹⁸ studied cell viability in rat skin grafts by assaying levels of diphosphopyridine nucleotide diaphorase, an indicator of active electron transport. The authors noted falling fibrocyte numbers in the first 3 days after grafting. The remaining fibrocytes lay in two narrow layers, one beneath the dermis–epidermis junction and the other just above the host bed. After day 3 fibroblast-like cells began to appear, first in the graft bed and later in the graft itself. By the seventh to eighth day postgraft the fibroblast population and enzymatic activity were greater than in normal skin. After this early burst in fibroblastic activity, however, both fibroblast numbers and enzyme levels resumed their normal, pregraft states over the ensuing weeks.

Fibrous component

Medawar^{12,13} stated that most of the collagen in an autograft persists through the 40th day after grafting. Hinshaw, Miller, and Cramer,^{19,20} on the other

hand, concluded that split-thickness and full-thickness skin autografts undergo considerable collagen turnover. In their experiments the dermal collagen became hyalinized by the third or fourth day postgraft, and by the seventh day all of the collagen was replaced by new small fibers. The replacement continued through the 21st postgraft day, and by the end of the sixth week postgraft all the old dermal collagen had been completely replaced. The rates of collagen turnover and epithelial hyperplasia peaked simultaneously in the first 2–3 weeks postgraft.

Klein^{21,22} and Peacock²³ used hydroxyproline to determine the collagen content of grafted wounds. Hydroxyproline is an amino acid found exclusively in collagen at a constant proportion of 14%. Changes in hydroxyproline and monosaccharide content of grafted beds paralleled those of other healing wounds.²⁴ Independent studies by Hilgert²⁵ and Marckmann²⁶ confirmed these findings and documented plunging levels of hydroxyproline soon after grafting. The hydroxyproline (collagen) level eventually rebounded and finally returned to the normal levels of unwounded skin. Although Hilgert's cycle lasted 10 days and Marckmann's 14–21 days, it is now well established that most of the collagen in a graft is ultimately replaced.

On the basis of studies involving tritiated proline-labeled mature collagen, Udenfriend²⁷ and Rudolph and Klein²⁸ agreed that 85% of the original collagen in a graft is replaced within 5 months postgraft. The collagen turnover rate of grafts is 3X to 4X faster than that of unwounded skin.²⁹ In addition, although equal amounts of collagen are lost from full- and split-thickness grafts, STSGs replace only half as much of their original collagen as do FTSGs of equal size.

Elastin fibers in the dermis account for the resilience of skin. While the elastin content of the dermis is small, the elastin turnover rate in a healing graft is considerable, and most of the elastin in a graft is replaced within a short time. Elastin fiber integrity is maintained through the third postgraft day, but by postgraft day 7 the fibers are short, stubby, and have begun to fragment.¹⁹ Elastin degeneration continues through the third postgraft week until new fibers can be seen beginning to grow at 4–6 weeks postgraft. This replacement process is the same in full- and split-thickness skin grafts.

Extracellular Matrix

Far from simply supporting cells passively, the extracellular matrix (ECM) plays a vital role in cell-to-cell communication.³⁰ Through specific arrangements of protein sequences within, the ECM influences cellular behavior in adjacent tissues with regard to proliferation, differentiation, migration, and attachment.

The extracellular matrix in the skin consists of large insoluble proteins of fibroblast origin and smaller soluble proteins produced by either fibroblasts or keratinocytes. Both kinds of proteins appear to be involved in directing the behavior of keratinocytes and in promoting appropriate communication between keratinocytes and fibroblasts.

Epithelial Appendages

The sweating capability of grafted skin is a function of the number of sweat glands transplanted during grafting and of the extent of sympathetic reinnervation to the graft. A skin graft will sweat much like its recipient site due to ingrowing sympathetic nerve fibers from the graft bed. Thus a graft that is placed on the abdomen will sweat in response to physical activity, whereas an identical graft placed on the palm will sweat in response to emotional stimuli.

Although both full- and split-thickness skin grafts demonstrate sebaceous gland activity, thin split-thickness grafts do not contain functional sebaceous glands and typically appear dry and brittle after take.

Hair follicles are subjected to the same hyperplastic stimuli as the rest of the graft. On the fourth day postgraft the original hair sloughs off and the graft becomes hairless. Soon after the graft follicles begin to produce new hair, and by the 14th postgraft day very fine, baby-like hair is seen growing out of the graft.¹²

Full-thickness skin grafts produce hair while split-thickness skin grafts produce little or no hair. Full-thickness skin grafts that take well grow normal hair in terms of orientation, pigmentation, and follicular clustering.¹³ Inadequate revascularization will damage the graft hair follicles and result in decreased hair density. Similarly, when graft take is interrupted for any reason, subsequent hair growth will be sparse, random, and lacking in pigment.¹⁴

In summary, unlike STSGs, FTSGs contain sweat glands, sebaceous glands, and hair follicles.⁸ Only full-thickness grafts, therefore, are capable of sweating, oil secretion, and hair growth.

GRAFT TAKE

The large array of physiologic events usually seen in a healing skin wound are altered and modified by placement of a graft. The graft becomes incorporated in the host bed through the process of graft "take". The success of a graft depends primarily on the extent and speed at which vascular perfusion is restored to this parasitic, ischemic tissue.

Given equal clinical and technical conditions, two qualities of a skin graft influence its fate. The first determinant is the blood supply of the skin from which the graft was obtained. A graft harvested from a highly vascular donor site will predictably heal better than a graft taken from a poorly perfused area. The second factor in graft take is the metabolic activity of the skin graft at the time of application, which will dictate its tolerance to the inevitable period of ischemia.

Skin graft take occurs in three phases. The first phase consists of plasmatic imbibition and lasts 24–48 hours. This is followed by an inosculatory phase and a process of capillary ingrowth that occur essentially simultaneously until generalized blood flow has been established by the fifth or sixth postgraft day.

Plasmatic Imbibition

The exact significance of plasmatic imbibition to the healing of a skin graft is not clear. Hinshaw and Miller¹⁹ and Pepper³¹ believed that plasmatic imbibition is nutritionally important, while Clemmesen,^{32,33} Converse,^{34,35} and Peer^{36,37} thought that it merely prevents the graft from drying out and keeps the graft vessels patent in the early postgraft period. Regardless of whose theory is correct, all concur in the following:

- The graft is ischemic for an undetermined period of time that varies according to the wound bed: 24 hours for a graft placed on a bed that is already proliferative; 48 hours for a graft covering a fresh wound.

- Grafts placed on poorly vascularized beds will be ischemic for a longer time than those placed on wounds with good blood supply. Exactly how long a graft will tolerate this ischemic interval is unclear, but thick FTSGs seem to tolerate ischemia for up to 3 days while thin FTSGs survive for up to 5 days.^{32,37} Split-thickness grafts take well even after 4 days of ischemia.³⁷
- Plasmatic imbibition allows a graft to survive this immediate postgraft ischemic period until such time as graft vasculature is reestablished.⁹
- Grafts gain weight during the phase of plasmatic imbibition,³³⁻³⁵ adding as much as 40% to their pregraft weight through fluid movement from bed to graft.³⁵ The origin of graft edema is believed to be the same as that of inflammatory edema—ie, from disaggregation and depolymerization of proteoglycans, accumulation of osmotically active metabolites, and increased vascular permeability.³⁸⁻⁴¹

Inosculation and Capillary Ingrowth

At the end of 48 hours, a fine vascular network is established in the fibrin layer between the graft and its recipient bed. Capillary buds from the blood vessels in the recipient bed make contact with the graft vessels and open channels are formed. Blood flow is established and the skin graft becomes pink.

Revascularization

Three theories have been put forth to explain how a skin graft is revascularized.

Connection of graft and host vessels. The first theory holds that after the inosculatory event, the definitive vasculature of a graft consists of the blood vessels originally present within the graft. According to this theory, circulation is restored in a graft via the original skin graft vessels by anastomoses formed between the recipient bed and the skin graft through inosculation. Peer and Walker,³⁶ Clemmesen,^{32,33} Haller and Billingham,⁴² and Birch and Branemark,³⁸⁻⁴⁰ among others, endorse this line of thinking.

Clemmesen,³³ working on a porcine model, injected India ink into the host vessels of the autograft. No ink was seen within the graft on the

first postgraft day, but on day 2 a number of graft vessels contained India ink, suggesting communication between the host and graft vessels. After the second day many graft vessels contained India ink, indicating patent connections between vessels of the graft and its bed. Initially a fine fibrin mesh linked the graft to the bed, but over the first 4 days this meshwork became lined with endothelial cells and linked up with the vessels of the graft.

Haller and Billingham⁴² reached a similar conclusion in a study involving the hamster cheek pouch model. They too noted that the pattern of vessels in the healed graft was the same as the pattern before grafting.

Formation of new vascular channels. The second theory of graft revascularization holds that the graft is perfused through new vessels going from the recipient bed into the transplanted graft. Converse,^{18,35,43-45} Zarem,⁴⁶ Ljungvist and Almgard,⁴⁷ and Wolff and Schellander⁴⁸ espouse this theory.

Converse and Rapaport⁴³ studied skin grafts in humans and noted an early connection of graft and host vessels—the inosculatory event—after which there was active invasion of the graft by host vessels to produce the definitive vasculature of the graft.

On the basis of a later study in a rat model involving diaphorase,¹⁸ Converse concluded that the final vasculature of a graft stemmed from ingrown vessels from the host bed. Degenerative changes in the original graft vasculature were apparent in the first 4 days postgraft, as evidenced by progressive loss of diaphorase activity during this time. With subsequent vessel ingrowth there was return of diaphorase activity.

Wolff and Schellander⁴⁸ measured cellular enzymes to evaluate return of circulation in porcine skin grafts. ATP activity correlated well with the pattern of new vessel ingrowth, leading the authors to conclude that the new graft vasculature consisted entirely of ingrown vessels.

Working on mice, Zarem et al⁴⁶ theorized that preexisting graft vessels served only as nonviable conduits through which the endothelium of the ingrowing vessels progressed. The rate of vessel ingrowth was measured at approximately 5 microns per hour. The original graft vessels degenerated concomitantly and at the same rate, leaving only those vessels growing from the recipient bed as the graft's definitive vasculature.

Combined old and new vessels. Smahel¹⁰ and Tsukada⁴⁹ proposed a third (and much less popular) hypothesis of graft revascularization: a compromise between the two above theories. The authors speculated that circulation in a graft is reestablished in various ways; that is, in any graft old vessels may be recycled and new ones may grow to variable degrees. These two pathways to restore circulation to ischemic tissue may occur simultaneously or as consecutive stages in the interaction between the graft and its bed.

There are two methods of skin graft revascularization: primary and secondary.

Primary revascularization. Under the scanning electron microscope it can be seen that no real circulation to the graft exists for the first 6 to 7 days postgrafting. Whatever flow there is within the graft is sluggish, shifting direction, and with attendant pooling and pendulum-like movement.⁵⁰ Clinically this manifests as cyanotic discoloration and is particularly noticeable in full-thickness skin grafts.^{18,38,43}

In the normal course of events circulation in a skin graft is reestablished through vascular anastomoses between budding neovessels from the bed and those already present in the graft (inosculation). Blood enters the graft via these newly formed vascular connections and the graft turns pink. A pink color is generally considered a sign of probable graft survival, although the intensity of coloration does not allow any conclusions regarding the graft's circulatory status.

Inside the graft the hemodynamic situation is complex. The old vessels of the graft are dilated and denervated and some of the circulatory routes are severed during graft harvest. Blood vessels from the recipient bed attach to both arteries and veins of the graft, yet all these connections are afferent with respect to the graft. Blood and tissue fluids moving into the graft are trapped there and unable to return to the bed because of inadequate reverse circulation.

Sometime between days 4 and 7 postgraft, the newly formed vascular connections differentiate into afferent and efferent vessels, and other vessels retain their capillary-like character or simply disappear.⁵¹ At this point the proper vascular system within the graft is reestablished and blood flow is restored.

Secondary revascularization. When vascular connections between the bed and the graft are delayed, secondary revascularization occurs. Under normal graft conditions, the vasoactive agent directing the ingrowth of new blood vessels ceases to function and capillary proliferation stops as good blood flow is established by neovascularization. However, the longer a graft remains ischemic, the longer the vasoactive substance remains in the tissue. As a result, great numbers of new capillaries grow into the graft and granulation tissue accumulates under the graft. This phenomenon is known as secondary revascularization.

The mechanism of secondary revascularization is as follows. Vascular connections between the graft bed and the graft inhibit the formation of capillary buds. If the graft is not well applied to the bed and vascular connections are not established early—eg, in the periphery of large grafts—the inhibiting effect does not take place. Within the graft itself the vessels may be functionally deficient or the vascular ingrowth may not reach the required level of biologic activity for the inosculatory event. If anastomoses fail to develop in time, the ischemic period is extended and capillary proliferation in the bed continues. Degenerative processes in the graft and exuberant granulation tissue in the host bed go hand in hand with prolonged ischemia. If blood vessels reach the graft in time, the graft will survive; if not, the graft will fail.

In the host bed, insufficient vascular proliferation and wound contamination are the two common causes of delayed inosculation. Anastomoses may not form at the right time because of the increased distance between the graft and its bed from interposed necrotic material, a thick fibrin layer, hematoma, seroma, or air bubbles.

Grafts that heal by secondary intention are smooth, fibrotic, tight, and have a slick, silvery sheen on the surface reflecting the large amount of cicatrix within the graft. Large grafts often heal both by primary and secondary revascularization, and certain areas show the typical appearance and desquamation where the secondary process occurs.

Histologically the epidermis and papillary dermis are destroyed by necrosis in the full-thickness graft that heals by secondary revascularization. The papillary dermis is replaced by a thin layer of connective tissue, which in turn is covered by a flattened epidermis. The reticular dermis is normal histologi-

cally, but beneath the graft there is a layer of newly formed connective tissue that infiltrates the dermis, resulting in graft fibrosis. Hinshaw and Miller¹⁹ noted accelerated collagen turnover in pig autografts that had healed by secondary revascularization.

SKIN GRAFTING TECHNIQUES

Donor Site Selection and Graft Harvest

The selection of a graft donor site is based on three factors: 1) whether a full-thickness skin graft or a split-thickness skin graft is to be used; 2) whether the intended donor site matches the recipient bed in color; and 3) potential morbidity of graft harvest at that site.

An appropriate color match is particularly important in head and neck reconstruction with skin grafts. Any skin graft taken below the clavicles and applied above the clavicle will result in a lifelong color mismatch that is extremely difficult, if not impossible, to correct.⁵² Both full- and split-thickness skin grafts can be harvested above the clavicle; STSGs obtained from a shaved scalp, in particular, often yield very good results. Figure 2 illustrates two patterns of skin graft harvested from the submental, "turkey gobbler" area, which is another good source of graft skin.⁵³ For large, full-thickness defects above the clavicle, tissue expansion is recommended to recruit an adequate volume of FTSG.

Graft reconstruction of the nasal tip requires specialized skin of similar thickness and pore size. The glabella provides just such skin.⁵⁴ Historically, donor sites for nasal tip grafting have included the concha, nasolabial fold, pre- and postauricular skin, the neck, and supraclavicular areas.⁵⁴

To minimize morbidity from graft harvest, donor sites should be carefully chosen to avoid hair-bearing skin and to camouflage the resulting scar.⁵² Tiem⁵⁵ advocates a bilaminar harvest whereby an epithelial flap is raised, a dermal graft is taken, and the superficial layer is replaced in its original site. This is known as the trapdoor or dermatome technique. Tiem reports improved donor site management and fewer pigmentary changes with this method than with conventional harvest.

Beck and colleagues⁵⁶ compared the trapdoor technique with standard elliptical excision in 52 patients (60 graft sites). Although both techniques were successful and had minimal complications,

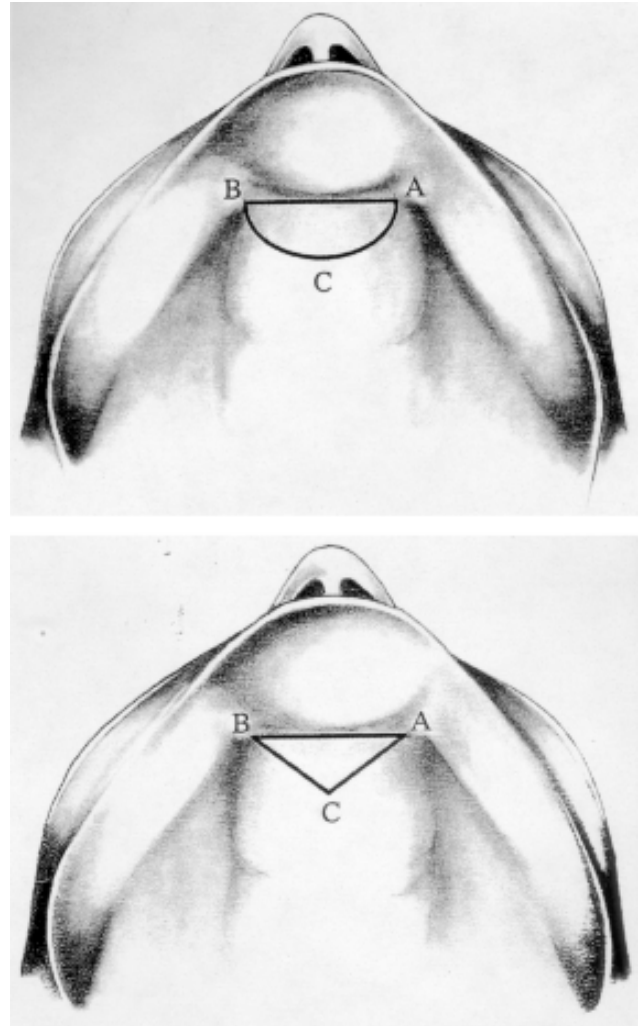


Fig 2. The turkey gobbler deformity as a source of skin grafts. A U-shaped excision results in dogears that may be visible laterally. A triangular excision eliminates the dogear problem but yields less skin. (With permission from Shiffman MA: Re: Cervicomenthal "turkey gobbler": a new source for full-thickness grafts (letter). *Dermatol Surg* 28:1099, 2002.)

"the elliptical method [was associated with] less discomfort, texture change, numbness, and itching. The scars were concealed better and less noticeable."⁵⁶

Common full-thickness graft donor sites are the groin, postauricular area, and clavicular region.⁵⁷ Yildirim and coworkers⁵⁷ also recommend the preputium as a source of graft skin in children. Split-skin grafts are usually harvested from the outer thigh because surgeons prefer this site for its technical ease and convenience of intraoperative positioning and postoperative dressings. The public, on the

other hand, would prefer that grafts be taken from their buttocks to avoid visible scars.⁵⁸

Graft Sizing and Expansion

Techniques for sizing skin grafts usually involve preformed templates of easily available materials, such as cardboard and latex.^{59,60} A simple and reproducible technique consists of placing cardboard in the wound to develop a blotter pattern⁶¹ (Fig 3). The cutout is then applied over the donor site, traced with a marking pen, and a graft of the outlined area is resected.⁶¹

A wound is reepithelialized from the edges toward the center, therefore the perimeter of the graft is the only part that contributes to the epithelialization process. An expanded graft presents a larger perimeter through which epithelial outgrowth can proceed. With graft expansion, larger areas can be covered with smaller sections of skin.

Various techniques to expand skin for grafting have been described, including pinch grafts,⁶² relay transplantation,⁶³ meshing,⁶⁴⁻⁶⁷ Meek island grafts,⁶⁸ microskin grafts,⁶⁹⁻⁷⁴ and the Chinese technique of intermingling autografts and allografts.^{75,76}

A *pinch graft* breaks up a whole graft of skin into tiny pieces to increase the edge area. Pinch grafts are reported to be effective in treating small- to medium-size venous leg ulcers,^{77,78} radiodermatitis, pressure sores, and small burns.⁶²

Relay transplantation consists of cutting a graft into strips 3–6 mm wide and 5–10 mm apart. When the epithelial growth becomes clinically obvious 5 to 7 days later, the original strips are removed and transplanted, leaving the epithelial explants in place. This process may be repeated up to 4 times.⁶³

Meshing is the term used for cutting slits into a sheet graft and stretching it open prior to transplantation. Meshed grafts have a number of advantages over sheet grafts: (1) meshed grafts will cover a larger area with less morbidity than non-meshed grafts; (2) the contour of the meshed graft can be adapted to fit in a regular recipient bed; (3) blood and exudate can drain freely through the interstices of a meshed graft; (4) in the event of localized bacterial contamination, only a small area of meshed graft will be jeopardized; (5) a meshed graft offers multiple areas of potential reepithelialization.⁶⁴⁻⁶⁶ The main disadvantages of meshed grafts are the considerable surface area

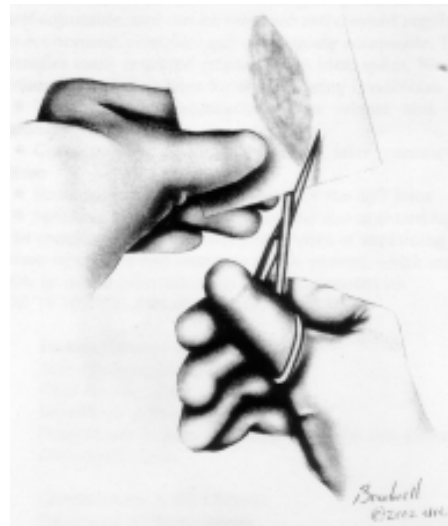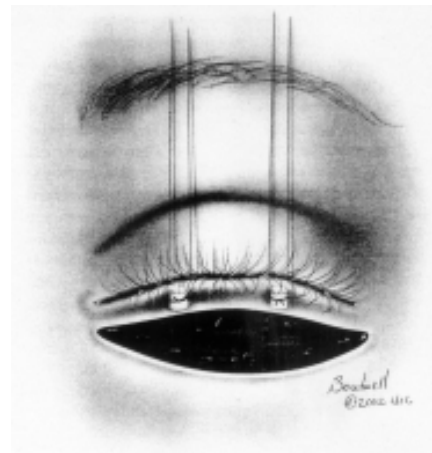
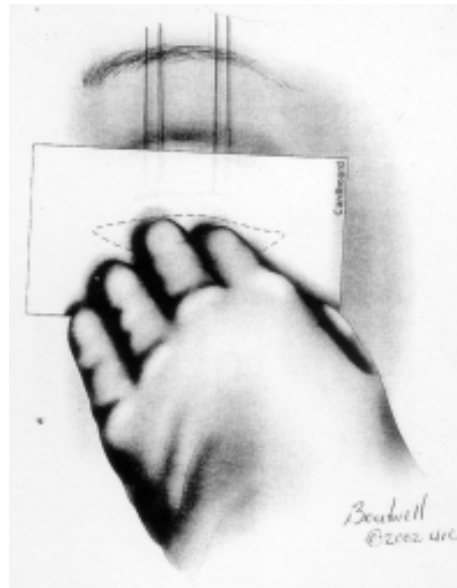


Fig 3. A piece of cardboard is placed on the defect and the moisture blot is traced. The cutout pattern is then placed on the skin graft donor site and outlined. (With permission from Putterman AM: *Blotter technique to determine the size of skin grafts* (letter). *Plast Reconstr Surg* 112:335, 2003.)

that must heal by secondary intention and the less-than-ideal cosmetic result. A small ratio of expansion—1:1.5—and pulling the graft lengthwise to narrow the skin perforations to slits before transplantation lessens these problems.⁶⁵

Richard and colleagues⁶⁷ compared the Tanner and Bioplasty skin graft meshing systems with respect to their respective expansion ratios and predicted versus actual expansion. Both systems delivered approximately 50% of the anticipated skin expansion, leading the authors to recommend harvesting skin grafts larger than needed to compensate for the eventual shortage.

Ingenious ways to mesh skin grafts when a mesher is not available have been reported.^{79,80} Kirsner and associates conclude that meshed STSGs are safe and effective therapy for recalcitrant leg ulcers.⁸¹

The *Meek technique* involves a special dermatome and prefolded gauzes for expanding small pieces of split skin.⁶⁸ The expansion ratio obtained with the Meek technique is almost 1:9. In contrast, the expansion ratio of allograft meshed with the Zimmer II dermatome set at 1:6 is actually 1:4. Meek grafts are useful alternatives to meshed grafts when donor sites are limited, and are particularly well suited for grafting granulating wounds and unstable beds.

Several authors report successful coverage of burn wounds with *microskin grafts*.⁶⁹⁻⁷⁴ These are sheet grafts that are minced with a Tanner-Vandeput dermatome to achieve an expansion ratio of 1:10. Graft take is said to be excellent even in difficult beds.

Intermingled transplantation of autograft and allograft has been practiced successfully in China since at least 1973,^{75,76} mostly in the treatment of large burns. Yeh and colleagues⁸² compared this technique with the microskin method in a rat model, and noted significantly less scar contracture with the former. Other healing parameters were similar between the two groups.

Graft Fixation

Adherence of the graft to its bed is essential for skin graft take. A thin fibrin layer holds the graft to the bed and forms a barrier against potential infection.⁸³ Factors such as bleeding, infection, and shear force tend to work against graft take.

Two distinct phases of graft adherence occur. Phase 1 begins immediately after grafting and lasts about 72 hours.⁸⁴ During this time the graft remains adherent to the bed through the bond formed by the fibrin layer. Phase 2 coincides with the onset of fibrovascular ingrowth and vascular anastomoses between the graft and the host.

Novel methods of graft fixation abound. When dealing with skin grafts to the penis and scrotum, which are particularly difficult to immobilize and dress, Netscher and associates⁸⁵ suggest wrapping the graft area in nonadherent gauze mesh over which Reston self-adhering foam is secured. The foam maintains penile length and gently but firmly compresses the skin graft during the crucial first week. The authors cite ease of application and removal, sterility, and effectiveness in wound coverage as advantages of this method.

Saltz and Bowles⁸⁶ and Caldwell and colleagues⁸⁷ also advocate the use of Reston foam applied over Xeroform gauze for securing skin grafts to wounds on the shoulder and face, respectively. Balakrishnan⁸⁸ prefers Lyofoam, a semipermeable, nonwoven polyurethane foam dressing. The foam is easy to apply directly on the graft and is biologically inert. Its hydrophobic outer surface is said to retard bacterial colonization.

Johnson, Fleming, and Avery⁸⁹ opt for a simple, versatile, and rapid technique consisting of staples and latex foam dressing to secure skin grafts. Wolf and coworkers⁹⁰ confirmed the effectiveness of rubber foam with staple fixation in various patterns to provide even pressure distribution on skin grafts.

Smoot⁹¹ uses a Xeroform sandwich filled with molded cotton balls stapled in place, while Amir et al⁹² modify a cutoff disposable syringe to affix the silk threads of their graft dressings. Cheng and colleagues⁹³ use a disk cut from the bottom of an IV infusion bottle on which multiple radial slits are made in the perimeter for tying the sutures holding the graft.

Other suggested fixation methods for grafts include silicone rubber dressings⁹⁴ and silicone gel sheets,⁹⁵ rubber band stents,⁹⁶ transparent gasbag tie-over dressings,⁹⁷ Coban self-adherent wrap,⁹⁸ thin hydrocolloid dressings,⁹⁹ and assorted Silastic and foam dressings for grafts to the neck or hand.¹⁰⁰⁻¹⁰²

Dressings for specific applications include a dorsal and ventral sandwich bolster for grafts on the tongue;¹⁰³ a cutout tie-over dressing of elastic tape with silk threads on which a bolster is placed;¹⁰⁴ and malleable ear dressings constructed of silicone-lined bandage with thin metal backing.¹⁰⁵

Modern bolster technologies of skin graft fixation replace sutures and staples with either fibrin glue¹⁰⁶⁻¹¹¹ or octyl-2-cyanoacrylate ("super glue") on the edges of the graft.^{112,113} Fibrin glue is strong, transparent, hemostatic, does not interfere with healing, and does not promote wound infection. Proponents of fibrin glue say that it improves graft survival, reduces blood loss, speeds reconstruction by allowing large sheet-graft coverage, and produces better esthetic results.¹¹¹ Our experience at The University of Texas Southwestern Medical Center bears out this assertion: A thin layer of fibrin glue improves graft take considerably, particularly in the head and neck and mobile body parts.

Negative-pressure dressings (VAC device [KCI, San Antonio, Texas]) also enhance graft adherence and survival,¹¹⁴⁻¹¹⁷ and are a good option in difficult-to-bolster areas such as the hand and axilla. The total time of bolster application can be reduced from 5 to 3 days while the patient maintains mobility of the extremity.

Donor Site Management

Open Wound Technique

The open-wound technique of donor site management is associated with prolonged healing time, more pain, and a higher risk of complications than if the wound is covered. Most authors recommend dressing the donor site of a skin graft to protect it from trauma and infection.

Allen and coworkers¹¹⁸ compared bacterial counts of wounds left open to granulate and of wounds covered by skin dressings. They found 12.5% of open wounds were sterile, but all the dressed wounds showed some microbial flora. When antibiotics were added, however, there was a dramatic decrease in bacterial colonization, leading the authors to conclude that it was the antibiotic, not the dressing, that had a sterilizing influence. Skin grafts have no intrinsic bactericidal properties.¹¹⁹

Biologic Dressings

Autografts

Feldman¹²⁰ recommends returning unused skin to the donor site as an autologous biologic dressing on the grounds that this is logical in terms of wound healing, tissue conservation, and expense. Wood¹²¹ agrees that this is a good idea in immunocompromised or steroid-dependent patients, but unnecessary in the general population. Careful planning before surgery to harvest only the required amount of skin is the ultimate solution, in Wood's opinion.

Allografts

Traditionally cadaver allografts have been the choice for resurfacing large denuded areas. Cadaver skin serves as temporary wound cover, reduces pain and fever, restores function, increases appetite, controls fluid loss, and promotes wound healing. As the grafts revascularize, they form a barrier against bacterial invasion and prevent further loss of water, electrolytes, and protein from the wound. Allografts decrease bacterial counts of underlying tissues and facilitate future grafting by promoting a sterile wound bed.¹²²

Glycerol-treated cryopreserved allografts have a number of applications such as in the treatment of scald burns in children,^{123,124} extensive burns in both children and adults,¹²⁵ and deep burns down to muscle fascia or fat (when combined with allogeneic cultured epithelial grafts).^{126,127} The main drawback of glycerol-preserved allografts is their expense.

As discussed above, Chinese investigators have successfully used combinations of allografts and autografts for coverage of open wounds.⁷⁵⁻⁷⁷ The autograft is cut into small pieces and placed in the slits of meshed allografts, or is laid down in alternating strips of auto- and allograft. As rejection unfolds, epidermal cells in the autograft gradually replace the allograft.¹²⁸

Xenografts

Xenografts (collagen-elastin prostheses) adhere to a wound bed via fibrin bonding. The advantages of xenografts are relatively low cost, ready availability, easy storage, and easy sterilization. Disadvantages are lack of antimicrobial activity, no proof that they promote reepithelialization, potential for absorption of toxic breakdown products, and poor

performance with respect to healing time and pain when measured against other donor site dressings.

Synthetic Materials

Feldman¹²⁰ lists methods for dressing the donor site of a skin graft (Table 1).

TABLE 1
Dressings for Skin Graft Donor Sites

<i>Semiopen</i>	Fine mesh gauze Scarlet Red Vaseline Gauze Xeroform Biobrane
<i>Occlusive</i>	DuoDERM
<i>Semiocclusive</i>	Op-Site Tegaderm
<i>Biologic</i>	Autograft Excess skin graft Allograft Human cadaver skin Xenograft Pigskin Amniotic membrane Cultured keratinocyte grafts

(Annotated with permission from Feldman DL: Which dressing for split-thickness skin graft donor sites? *Ann Plast Surg* 27:288, 1991.)

Synthetic wound dressings can be semiopen, semiocclusive, or occlusive. Semiopen dressings include Xeroform, Biobrane, and fine mesh gauze impregnated with Scarlet Red or Vaseline. Semiocclusive dressings include Op-Site, Tegaderm, and DuoDERM. Semiocclusive dressings are impermeable to bacteria and liquids, so fluid tends to collect beneath the dressing and must be drained frequently.

Feldman and colleagues¹²⁹ evaluated the effectiveness of various donor site dressings in 30 patients with respect to healing, pain, infection, and expense. Xeroform had an average healing time of 10.46 days, no infections, and a low cost per patient (\$1.16). The healing time for Biobrane was 19 days; for DuoDERM, it was 15.3 days. Biobrane was more comfortable than Xeroform, but was associated with 29% more infections and very high cost (\$102.50/patient).

In another study, donor site wounds dressed with Op-Site and Tegaderm showed rapid, relatively painless healing and low infection rates.¹³⁰ Brady et al¹³¹ compared Op-Site, Vaseline gauze, Jelonet, Scarlet Red, and exposure in terms of healing time, pain, infection, and cost. (Pig skin was initially included in the study but was soon eliminated because of *Pseudomonas* infection and hypertrophic scarring.) Wounds dressed with Jelonet healed quickly, followed closely by Vaseline gauze. The interval to healing was longest with the open method. Op-Site was the most comfortable dressing and the most expensive. Vaseline gauze was second to exposure in low cost. Recommendations from the authors were for Op-Site or Jelonet for dressing small donor areas and for Vaseline gauze to cover large wounds.¹³¹

Barnett and coworkers¹³² compared synthetic adhesive, moisture-vapor-permeable and fine mesh gauze dressings for STSG donor sites with respect to pain, rate of healing, adherence, and infection. Op-Site and Tegaderm promoted fast healing (mean 6.8 days) and were basically painless. Wounds covered with fine mesh gauze healed in 10.5 days but were 3X as painful.

In a study comparing Op-Site with simple polyvinyl film and tulle gauze, the authors note that Op-Site was associated with low discomfort, but PVC film was also well tolerated and was very inexpensive.¹³³

Dressings that promote a moist wound environment are associated with faster healing. Zapata-Sirvent¹³⁴ compared Biobrane and Scarlet Red and found Biobrane to be better at controlling pain and exudate accumulation, with shorter healing times. Tavis et al¹³⁵ agree that Biobrane reduces pain, limits infection and desiccation, and optimizes healing times, although its expense is considerable.

Poulsen and colleagues¹³⁶ found Jelonet superior to Op-Site in the treatment of partial-thickness burns both in terms of speed of healing (7 vs 10 days) and residual scars (8% vs 21%). A large comparison study of STSG donor site healing under Xeroform and Jelonet dressings showed no difference in mean time from harvest to healing, similar cost and ease of use, and less discomfort with Xeroform, particularly with movement.¹³⁷ Nemeth et al¹³⁸ note much less discomfort and faster healing by nearly 4 days of shave biopsy sites treated with DuoDERM over

conventional therapy consisting of cleansing, bacitracin, and band-aids.

Lawrence and Blake¹³⁹ and Porter¹⁴⁰ evaluated Kaltostat, a calcium alginate dressing, in the healing of STSG donor sites. The rate of epithelialization, degree of pain, and convenience of use were measured and compared with the same parameters in two other groups of patients treated with Scarlet Red and DuoDERM. The Kaltostat-treated patients had slower healing times (15.5 days) than other patients (10 days). On the other hand, the alginate was easier to apply and could be used on an outpatient basis.

The topical application of anesthetic agents relieves the pain of skin donor sites. Goodacre et al¹⁴¹ studied the effectiveness of topical local anesthesia (EMLA) versus infiltrated anesthesia in an open parallel group comparison in 80 patients. During graft cutting and after harvest, patients who received EMLA reported no discomfort. Owen and Dye¹⁴² report that topical application of 2% lignocaine gel to graft donor sites controlled discomfort during the first week postgrafting and did not impair healing. Azad and Sacks¹⁴³ recommend topical bupivacaine on graft donor sites under calcium alginate dressings to enhance comfort and improve hemostasis.

Others recommend honey-impregnated gauze for dressing donor sites and report no significant difference in time of reepithelialization or patient comfort between this inexpensive material and the more costly hydrocolloid dressings.¹⁴⁴

GRAFT HEALING

In his classic work on skin grafts in the mid-1940s, Medawar¹²⁻¹⁴ described the appearance of healing grafts as follows:

Immediately after removal from the donor area the skin graft is white, but once applied to the recipient area it becomes pink over the next few days. There is blanching on pressure with prompt capillary refill. At first the graft surface is depressed below the level of the surrounding skin, but by the 14th to 21st postgraft day it becomes level with the surrounding surface.¹⁹

Collagen replacement begins by the seventh postgraft day and is complete in about 6 weeks. There is an abundance of polymorphonuclear lymphocytes and monocytes. The mononuclear infiltrate persists in the dermis for an extended period of time.

Vascular remodeling in the graft may take many months.¹⁴⁵ Host vessel ingrowth is perpendicular to the dermis–epidermis junction and forms a characteristic vascular pattern. The new vessels in the graft are more numerous and show greater arborization than those in normal skin.

Lymphatic drainage is present through connections between the graft and host lymphatics by the fifth or sixth postgraft day, and subsequently the graft loses weight until pregraft weight level is attained by the ninth day.¹⁴⁶

GRAFT CONTRACTION

A skin graft begins to shrink immediately after harvest. *Primary contraction* is passive and probably due to the recoil of the dermal elastic fibers. A full-thickness graft loses about 40% of its original area as a result of primary contraction; a medium-thickness graft, about 20%; and a thin split-thickness graft, about 10%. True Thiersch grafts do not undergo primary contraction.

After transfer to a recipient site, the skin graft will shrink as it heals—*secondary contraction*. Full-thickness grafts tend to remain the same size (after primary contraction) and do not show secondary contraction. Split-thickness grafts, on the other hand, contract whenever circumstances allow. Unless split-thickness skin grafts are fixed to underlying rigid structures and cannot move, they will contract secondarily. Once wound contraction ends, full-thickness grafts are able to grow, whereas split-thickness grafts remain fixed, contracted, and grow minimally, if at all.^{147,148}

Wound contraction is a critical part of wound healing and is clinically useful because it reduces wound size. A contracted wound is often tight and immobile and there is distortion of surrounding normal tissue. The degree of graft contraction can be manipulated somewhat by adjusting the thickness and proportion of dermis in the graft. The contraction-inhibiting effect of dermis depends more on the percentage of dermis included in the graft than in overall thickness of the graft: the greater the proportion of dermis, the greater the inhibition and the less the graft will contract. FTSGs therefore inhibit wound contraction better than STSGs;¹⁴⁷⁻¹⁴⁹ thin FTSGs inhibit wound contraction better than thick STSGs, and thick STSGs contract less than thin STSGs.^{8,150,151}

Brown, Garner, and Young¹⁵² concluded that the capacity of a skin graft to inhibit wound contraction is directly proportional to the amount of structurally intact dermal collagen present in the graft. The rate of wound contraction is not affected by graft orientation, amount of epidermis, or noncollagenous protein.

Various hypotheses have been proposed to explain the mechanism of this inhibition, including a mass effect, cellular interactions between graft cells and host bed, epidermal interaction, mechanical restriction, etc.¹⁵² Rudolph^{153,154} explains the interaction between a graft and its bed in terms of the lifecycle of a myofibroblast. In this hypothesis a graft does not prevent the formation of myofibroblasts, but rather speeds up completion of their lifecycle and eventual disappearance.¹⁵⁵ Split-thickness grafts cause a rapid decline in the number of myofibroblasts, and wounds contract less than comparable nongrafted sites. Full-thickness grafts trigger an even faster decrease in the myofibroblast population, and wounds show minimal contraction.

Bertolami and Donoff^{150,151} studied the effect of dermis on the actinomycin content of granulating wounds and suggest that the mechanism of wound contraction is not simply the result of myofibroblast activity;¹⁵⁵ the active role of collagen cannot be ignored. Substances that inhibit wound contraction also inhibit prolyl hydroxylase activity (an indicator of collagen synthesis). Lower levels of this enzyme beneath a full-thickness graft may reflect decreased collagen synthesis, which in turn may be involved in preventing wound contraction.¹⁵⁰

Oliver and associates^{156,157} highlight the importance of the collagen matrix in inhibiting wound contraction. The matrix was prepared for grafting by adding azide to destroy the cells and trypsin to remove noncollagenous protein. These grafts, cell-free and noncollagenous-protein-free, resist wound contraction as well as full-thickness skin grafts, suggesting that dermal cells and noncollagenous proteins are not part of the inhibitory process. Grafts free of dermal cells but possessing a collagen matrix in fact behave much like FTSGs. It may be possible, therefore, to store nonantigenic dermal substitutes produced from banked cadaveric skin or xenogeneic sources by adding trypsin or azide to remove noncollagenous protein and cells. This would increase dramatically the clinical availability of substitute dermis as a potential source of grafts.

In a porcine study, Walden and coworkers¹⁵⁸ report minimal contraction at 14 days when epidermal autografts were immediately placed over acellular dermis, presumably by reducing early inflammation. By day 30, however, these wounds had contracted more than conventional autografts.

GRAFT REINNERVATION

Nerves grow into skin grafts from wound margins and the graft bed.¹⁵⁹ The timing of neural invasion and disposition of nerves within a skin graft vary according to the graft thickness and recipient site. Human skin grafts begin to show sensory recovery at 4–5 weeks postgrafting, but occasionally sensation is delayed for up to 5 months. The return of normal sensation is usually complete by 12–24 months. The extent of reinnervation depends on how accessible the neurilemmal sheaths are to the invading nerve fibers—ie, most accessible in full-thickness grafts and least accessible in thin split-thickness grafts.

Skin grafts are initially hyperalgesic and slowly regain normal sensation.⁸ If skin graft healing is uneventful, the results of two-point discrimination testing will be very close to those of normal skin. Other sensations do not recover so well. Waris and associates¹⁵⁹ measured the thermal sensitivity of 22 split skin grafts transplanted 1–4 years earlier. Cold sensitivity was present in 14, warmth in 6, and heat–pain in 8 grafts. If the warmth sensitivity had recovered, the threshold was lower than for cold. Seven grafts showed no thermal sensitivity at all.

Haro and colleagues¹⁶⁰ confirmed poor return of sensitivity in grafts by means of immunohistochemical methods. Grafts less than 7 months old showed no sensitivity whatsoever, and pain sensation had developed only in the 15-month-old grafts. Although deep and superficial nerve plexuses regenerated, no sensory corpuscles were detected in grafted skin at any time.

Stella et al¹⁶¹ independently verified these findings and speculate that the failure of regeneration of sensory corpuscles may be related to the degeneration of periaxonal corpuscular elements.

Ponten¹⁶² stated that grafts assume the sensory pattern of the host tissue, but Adeymo and Wyburn¹⁶³ and later Fitzgerald, Martin, and Paletta¹⁶⁴ noted that nerves entering the graft fol-

low the evacuated neurilemmal sheaths and reestablish the innervation pattern of the donor skin.

Weis-Becker and coworkers¹⁶⁵ note better reinnervation of split skin grafts placed on intact muscle fascia than if the fascia had been removed. Sensory functions on grafted skin were generally reduced.

GRAFT PIGMENTATION

Immediately after harvesting, a skin graft blanches from circulatory interruption. The consequent loss of melanoblast content causes profound alteration in the ratio of pigment-producing to nonpigment-producing cells in the graft.¹⁶⁶ After transplantation and graft revascularization there is inflow of erythrocytes and the normal equilibrium of the melanocyte population is restored. The graft resumes a pink color which over time fades to a normal skin tone. Mir y Mir¹⁶⁷ reviews melanogenesis, its peripheral nervous system control, the hyperpigmentation state that follows cutaneous grafting, and the effects of ultraviolet radiation on the skin.

Skin grafts change color during healing.¹⁰ Grafts harvested from the abdomen, buttocks, and thigh become darker as they heal, while grafts taken from the palm tend to lighten. Grafts taken from brunettes progressively darken, while those from blondes usually lighten. Full-thickness grafts from the eyelid, postauricular and supraclavicular areas are usually good color match for the face, although they may remain red for many months. In general, grafts taken from below the clavicle assume a yellowish-brown hue, while grafts taken from above the clavicle provide a better color match for facial skin. Thin split-thickness skin grafts from the same donor site are usually darker than thick ones.¹⁶²

The best treatment for hyperpigmented grafts is dermabrasion. For dermabrasion to be effective, however, it must be done at the appropriate time. If it is performed too soon after skin graft, the blanching will not last and the dark pigment will reappear. The best results are seen when dermabrasion follows biologic reinnervation of the graft. Generally, the later the dermabrasion is done after grafting, the more effective it is in removing unwanted pigment.

Skin depigmentation states and their treatment are reviewed by Taki et al.¹⁶⁸ Vitiligo, senile leukoderma, dyschromatosis symmetrica hereditaria, and second- or third-degree burns can produce significant cosmetic deformity, particularly in dark-skinned patients. Corticosteroids and oral psoralen may, with exposure to sunlight, be successful in the treatment of vitiligo provided that dopa-positive melanocytes are present in the skin.¹⁶⁹ Burns that invade the dermis (second- and third-degree) decrease the number of dopa-positive melanocytes, so that appropriate treatment consists of removing the depigmented skin and replacing it with very thin STSGs of normal color. This protocol is also successful in treating leukoderma.

A number of authors report successful repigmentation in leukoderma or vitiligo after treatment with ultra-thin, melanocyte-containing epidermal sheet grafts¹⁷⁰⁻¹⁷⁷ or in-vitro cultured melanocytes.¹⁷⁸ Hosokawa and colleagues¹⁷⁹ report a novel method of tattoo elimination in which the pigment-containing dermis is chemically removed and the epidermis is replaced. Wound healing time was much shorter than for typical skin grafts.

OVERGRAFTING

Dermal overgrafting consists of applying a split-thickness skin graft to a recipient bed or dermis or denuded scar tissue.¹⁸⁰ Overgrafting preserves subcutaneous tissues, is a relatively simple procedure, and the tissue consequences of graft failure are minimal. Rees and Casson¹⁸¹ offer technical details of skin removal and bed preparation and list the best donor sites. Their indications for overgrafting are as follows:

- unstable, depressed, corrugated, or hypertrophic scars
- unstable or hyperpigmented skin grafts
- large pigmented nevi
- radiation damage
- tattoos

Pigmented lesions should be excised deep enough to remove all the pigment before the graft is applied. A potential complication of the technique is the formation of cysts and granulomas from retained epithelial remnants.¹⁸¹

GRAFT FAILURE

A meticulous surgical technique contributes greatly to the survival of a skin graft. Particular attention should be paid to ensuring

- atraumatic graft handling
- a well-vascularized, scar-free bed
- careful hemostasis and removal of accumulated blood before dressing the wound
- postoperative immobilization of the graft recipient site
- use of a tourniquet during graft harvest and transfer
- no proximal constricting bandages

Flowers¹⁸² reviews the usual complications associated with graft failure and recommends steps to avoid them. The graft bed should be as clean as possible, free of dead tissue, and have an appropriate substrate (eg, bone should have periosteum, tendon should have peritenon). A clean area with endothelium is all that is required in the bed of a successful skin graft.

The most common cause of autologous skin graft failure is hematoma. The clot isolates the undersurface of the graft from the endothelial buds of the recipient site so that revascularization cannot take place.¹⁸²

The second most common cause of graft loss is infection. Infection can be avoided by carefully preparing the wound bed, using quilting sutures, meshing or pie-crusting the graft surface to allow free egress of subjacent fluids, and applying wet saline dressings that are changed every 4 hours.¹⁸²

Fluid beneath the graft can also cause graft necrosis. Areas rich in lymphatics such as the supraclavicular, inguinal, and axillary regions are particularly prone to develop seromas. Atraumatic tissue handling, cauterization of lymphatic vessels, limited use of electrocautery in the graft bed, and a light pressure dressing or VAC technique minimizes the risk of fluid accumulation under the graft.¹⁸²

Excessive pressure on a fresh graft may also cause it to die. The applied pressure should never exceed 30 mmHg. Tie-over dressings immobilize the graft, reduce dead space, and prevent hematoma formation, but exert no significant pressure on the wound.¹⁸³ Other causes of graft failure include gravitational dependency, movement of the area,

arterial insufficiency, venous congestion, lymphatic stasis, and surgeon error.

Teh¹⁸⁴ studied 21 patients with stasis ulcers in an attempt to pinpoint the causes of graft failure. Wound exudates were assayed for fibrin degradation products, fibrinogen, available plasminogen, and active plasmin. All wounds showed granulation tissue and were classified as clean or dirty. Clean wounds had low bacterial counts and showed no detectable plasmin activity. Dirty wounds had high bacterial counts and increased levels of active plasmin. High plasmin and proteolytic enzyme activity was generally seen in wounds contaminated with beta-hemolytic streptococci and various species of *Pseudomonas*. The presence of fibrin under autografts was associated with success in 17 of 21 ulcers, and the absence of fibrin was associated with graft failure. This finding suggested to the author that dissolution of fibrin by plasmin and proteolytic enzymes is the probable mechanism in graft failure secondary to microorganisms.¹⁸⁴

In conclusion, a grafted wound is rendered sterile through the blocking action of fibrin in the interface between graft and bed. Fibrin plays a central role in graft survival and is responsible for the antibacterial character of adherent dressings and autografts. This bacteriostatic effect of grafts has proved invaluable in the management of large burns.¹⁸⁴

Thourani and colleagues¹⁸⁵ assessed the effect of various recipient beds on the success of STSGs in a burn unit, and found it to be negligible at 14 days postgrafting. The exception were patients under 18 years of age, in whom STSG success was higher on granulation tissue than on fat.

Hill¹⁸⁶ recommends a number of measures to enhance the survival of full-thickness grafts. Because streptococci produce streptokinase and other enzymes that break down the fibrin clot and decrease adherence of the graft to its bed, he proposes the administration of low-dose erythromycin for the first 5 days after grafting to combat potential strep and staph colonization. Patients should also take vitamin C and zinc for a week to 10 days to promote healing, and should abstain from using alcohol for at least 2 days before and 5 days after surgery. Ethanol in the bloodstream decreases the initial phase of wound healing (the PMN clean-up phase) and can result in infection and decreased graft adherence.¹⁸⁶

Wolfort and colleagues,¹⁸⁷ working on rabbits, found that epinephrine added to local anesthetic solutions decreased inosculation in full-thickness grafts but had no effect on ultimate survival of split-thickness skin grafts. Subsequently Fazio and Zitelli¹⁸⁸ assessed the clinical effects of epinephrine in local anesthesia of the donor site. The authors found an increased risk of graft complications at 1 week and no effect on the 6-week cosmetic outcome. They do not recommend using plain lidocaine for harvesting full-thickness grafts unless the vascular supply of the donor area is compromised.

Robson and Krizek¹⁸⁹ predict skin survival on the basis of successful homograft take prior to autografting. Perry¹⁹⁰ notes a direct correlation between skin graft survival and bacterial counts of $<10^5$ in the recipient bed.

SKIN SUBSTITUTES

Unlike temporary wound dressings, skin substitutes are designed to be left in place for long periods of time. Fifteen years ago Pruitt and Levine¹⁹¹ listed attributes of the ideal skin substitute which are still current today:

- little or no antigenicity
- tissue compatibility
- lack of toxicity, either local or systemic
- permeability to water vapor just like normal skin
- impenetrability to microorganisms
- rapid and persistent adherence to a wound surface
- porosity for ingrowth of fibrovascular tissue from the wound bed
- malleability to conform to an irregular wound surface
- elasticity for motion of underlying tissues
- structural stability to resist linear and shear stresses
- a smooth surface to discourage bacterial proliferation
- sufficient tensile strength to resist fragmentation
- biodegradability
- low cost
- ease of storage
- indefinite shelf life

Classification

Skin substitutes may be classified according to their origin—autologous, allogeneic, xenogeneic, or recombinant¹⁹²—or whether they are used for wound cover or wound closure.¹⁹³ Materials used for *wound cover* are primarily indicated for superficial burns, where they provide a barrier against infection, control water loss, and create an environment suitable for epidermal regeneration. Examples of skin substitutes for wound cover are Biobrane, Transcyte (formerly Dermagraft-TC), cultured epidermal allogeneic keratinocytes, Dermagraft, and Apligraf (Graftskin). Materials intended for *wound closure* restore the epidermal barrier and become incorporated into the healing wound. Skin substitutes for wound closure include Alloderm, Integra, cloned autologous keratinocytes (Epicel), and composites of epidermal–dermal components, allograft–xenograft skin, or collagen–glycosaminoglycan matrix with a cultured epidermal autograft (CEA) surface (Table 2).

Wound Cover










Biobrane

Biobrane is a bilaminar material consisting of nylon mesh bonded to thin, semipermeable silicone membrane. It provides a barrier function against fluid loss as well as protection from environmental bacterial invasion. The product is often used as a temporary skin replacement for superficial partial-thickness burns as well as for skin graft donor sites. When applied to clean wounds, Biobrane eliminates the need for dressing changes and reduces the length of inpatient treatment.^{192,193}

Transcyte

Transcyte is Biobrane with the addition of neonatal fibroblasts seeded to the collagen-coated nylon mesh. The fibroblasts are nonviable at application and the nylon mesh is not biodegradable, so the material is designed for use as a temporary cover. Transcyte for preliminary coverage of partial thickness burns results in fewer dressing changes and less hypertrophic scarring than conventional treatment with topical silver sulfadiazine.¹⁹⁴ Transcyte is considerably more expensive than Biobrane.^{192,193}

TABLE 2
A Guide to Biological Skin Substitutes

Trade Name	Schematic Representation	Layers	Cost	Cost per cm ²
Biobrane™ (Dow Hickam/Bertek Pharmaceuticals, Sugar Land, TX)		<ol style="list-style-type: none"> 1. Silicone 2. Nylon Mesh 3. Collagen 	5x5cm £12.00	£0.48
Transcyte® (Advanced Tissue Sciences, Inc, La Jolla, CA)		<ol style="list-style-type: none"> 1. Silicone 2. Nylon Mesh 3. Collagen seeded with neonatal fibroblasts 	13x9cm £921.15	£7.87
Apligraf® (Organogenesis, Inc, Canton MA and Novartis Pharmaceuticals Corporation, East Hanover, NJ)		<ol style="list-style-type: none"> 1. Neonatal keratinocytes 2. Collagen seeded with neonatal fibroblasts 	7.5 cm diam disc £626.00	£14.20
Dermagraft® (Advanced Tissue Sciences, Inc, La Jolla CA)		<ol style="list-style-type: none"> 1. Polyglycolic acid (Dexon™) or polyglactin-910 (Vicryl™) seeded with neonatal fibroblasts 	5x7.5cm £267.80	£7.14
Integra® (Integra Life Science Corporation, Plainsboro, NJ)		<ol style="list-style-type: none"> 1. Silicone 2. Collagen and glycosaminoglycan 	10x25cm £830.00	£3.32
Alloderm® (LifeCell, The Woodlands, TX)		<ol style="list-style-type: none"> 1. Acellular de-epithelialised cadaver dermis 	4x12cm £283.00	£5.90
Epice ™ (Genzyme Corporation, Cambridge, MA)		<ol style="list-style-type: none"> 1. Cultured autologous keratinocytes 	Not yet licensed in UK	
Laserskin™ (Fidia Advanced Biopolymers, Italy. Also marketed as Vivoderm™ by ER Squibb & Sons, Inc)		<ol style="list-style-type: none"> 1. Cultured autologous keratinocytes 2. Hyaluronic acid with laser perforations 	Not yet licensed in UK	
Cadaveric allograft (from not for profit skin banks)		<ul style="list-style-type: none"> • cryopreserved in order to retain viability • lyophilised • glycerolised 	similar price for all three various sizes	£0.60

(Reprinted with permission from Jones I, Currie L, Martin R: A guide to biological skin substitutes. *Br J Plast Surg* 55:185, 2002.)

Cultured Allogeneic Keratinocytes

The delay in growing sheets of confluent autologous keratinocytes led to the development of pregrown allogeneic keratinocytes. Epidermal grafts are obtained from neonatal foreskin or elective surgical skin specimens and are cultured. Cultured allogeneic keratinocytes have been used to cover burn wounds, chronic ulcers, and as donor site dressings for split-thickness skin grafts. They will not in themselves achieve wound closure, but may survive for up to 30 months. Allogeneic keratinocytes do produce growth factors that facilitate the proliferation and differentiation of the host dermal and epidermal cells. The main disadvantage is that the cultured epithelial cell sheets are thin and fragile, requiring meticulous wound care if they are to survive.

Apligraf/Dermagraft

These are multilaminar materials designed to overcome the fragility of cultured allogeneic keratinocytes by improved ease of handling and healing characteristics. Apligraf is a type I bovine collagen gel with living neonatal allogeneic fibroblasts overlaid by a cornified epidermal layer of neonatal allogeneic keratinocytes. Apligraf is available in a ready-to-use form with a 5-day shelf life. It has wide application in treating chronic ulcers as well as in pediatric burn coverage, for coverage of widespread skin defects such as epidermolysis bullosa, and to cover full-thickness wounds resulting from Mohs' micrographic surgery pending definitive repair.^{192,193,195-199} Apligraf is the most sophisticated tissue-engineered product available for wound coverage, and is also the most expensive.¹⁹³

Dermagraft is a cryopreserved dermal material consisting of neonatal allogeneic fibroblasts on a polymer (Dexon or Vicryl mesh) scaffold. Dermagraft stimulates the ingrowth of fibrovascular tissue from the wound bed and reepithelialization from the wound edges, and as such promotes the healing of chronic lesions.¹⁹³ Dermagraft has been used to replace lost dermal tissue beneath meshed split-skin grafts on full-thickness wounds.²⁰⁰

Wound Closure

Alloderm

Alloderm is processed human cadaveric skin from which the epidermis has been removed and the

dermal cells extracted. Alloderm functions as a dermal graft, but has no barrier function because it has no epidermal component. Alloderm is similar to Dermagraft in many respects. A split-thickness skin graft can be placed over Alloderm after tissue ingrowth, or an ultra-thin graft can be placed at the time of Alloderm application in a single-stage procedure. The indications for Alloderm are as dermal replacement in full-thickness or deep partial-thickness wounds.^{193,201}

Integra

Integra is a bilaminar skin substitute consisting of a cross-linked bovine collagen-glycosaminoglycan matrix coated on one side with silicone elastomer for a barrier function. Integra is applied in a two-stage procedure much like a split- or full-thickness skin graft. As the host tissue grows into the wound, the silicone "epidermis" separates and sloughs off in 3-4 weeks, after which the integrated matrix is covered with a thin STSG.

Integra has widespread applications in burn and full-thickness wound closure. Its reliability is good on long clinical follow-up. Advantages of Integra include off-the-shelf availability; improved elasticity and cosmesis compared with thin STSG; and no risk of cross infection. Disadvantages are a somewhat steep learning curve for application; the necessity for a two-stage procedure, and its high cost.^{192,199,201}

Cultured Epithelial Autografts

Rheinwald and Green⁵ pioneered a method to clone human epidermal cells in vitro in 1975. In 1979, Green et al⁶ perfected a technique for growing cultured epithelial keratinocytes into confluent sheets suitable for grafting. Clinical experience with epidermal cells grown in vitro include burns, chronic leg ulcers, giant pigmented nevi, epidermolysis bullosa, and large areas of skin necrosis. Like STSGs, cultured epithelial autografts must be applied on a wound bed with early granulation tissue or muscle fascia for proper take.¹⁹³

Sheets of cultured epithelial cells (Epichel) are expensive and require a fair degree of expertise for application. These sheets are fragile, often resulting in a friable, unstable epithelium that may spontaneously blister, break down, and contract long after application.¹⁹³ Cultured epithelial cells used for grafting have an expansion capability of 10,000X

the original surface area.^{202–204} When cultured cells and allografts are combined, they tend to be more stable than either component alone, yet many prefer to use CEAs alone on large burns.^{205,206}

Many burn centers continue to use cultured epidermal autografts. The following conclusions regarding grafts of cultured keratinocytes derive from their combined experiences.

- Tissue cultured grafts are commercially available.
- CEAs are very expensive: a 2x2-inch graft cost approximately \$550 in 1996.

- Sheets of cultured keratinocytes are very fragile and must be handled with extreme care.
- CEAs require well-vascularized beds.
- Once the CEA takes, the cells will spread peripherally to join other grafts or surrounding skin.
- CEAs are extremely sensitive to infection, tolerating maximum bacterial counts of 10^2 to 10^3 /cm³ (compared with 10^4 – 10^5 /cm³ for standard STSG).²⁰⁷

BIBLIOGRAPHY

1. Ratner D: Skin grafting. From here to there. *Dermatol Clin* 16(1):75, 1998.
2. Hauben DJ, Baruchin A, Mahler D: On the history of the free skin graft. *Ann Plast Surg* 9:242, 1982.
3. Brown JB, McDowell F: Massive repairs with thick split-skin grafts; emergency “dressing” with homografts in burns. *Ann Surg* 115:658, 1942.
4. Tanner JC Jr, Vandeput J, Olley JF: The mesh skin graft. *Plast Reconstr Surg* 34:287, 1964.
5. Rheinwald JG, Green H: Serial cultivation of strains of human epidermal keratinocytes: the formation of keratinizing colonies from single cells. *Cell* 6:331, 1975.
6. Green H, Kehinde O, Thomas J: Growth of cultured epidermal cells into multiple epithelia suitable for grafting. *PNAS* 76:5665, 1979.
7. Vistnes LM: Grafting of skin. *Surg Clin North Am* 57:939, 1977.
8. Grabb WC: Basic techniques in plastic surgery (skin grafts). In: *Grabb and Smith’s Plastic Surgery*, 3rd ed, Boston, Little Brown, 1979.
9. Rudolph R, Klein L: Healing processes in skin grafts. *Surg Gynecol Obstet* 136:641, 1973.
10. Smahel J: The healing of skin grafts. *Clin Plast Surg* 4:409, 1977.
11. Marckmann A: Reaction of skin to autotransplantation. Studies on the microcirculation and the biochemical composition in dermis (thesis). *Copenhagen, Munksgaard*, 1966.
12. Medawar PB: The behaviour and fate of skin autografts and skin homografts in rabbits. *J Anat* 78:176, 1944.
13. Medawar PB: A second study in the behaviour and fate of skin homografts in rabbits. *J Anat* 79:157, 1945.
14. Medawar PB: The experimental study of skin grafts. *Br Med Bull* 3:79, 1945.
15. Scothorne RJ, Tough JS: Histochemical studies of human skin autografts and homografts. *Br J Plast Surg* 5:161, 1952.
16. Van Winkle W: The fibroblast in wound healing. *Surg Gynecol Obstet* 124:369, 1967.
17. Grillo HC: Derivation of fibroblasts in the healing wound. *Arch Surg* 88:218, 1964.
18. Converse JM, Ballantyne DL Jr: Distribution of diphosphopyridine nucleotide diaphorase in rat skin autografts and homografts. *Plast Reconstr Surg* 30:415, 1962.
19. Hinshaw JR, Miller ER: Histology of healing split-thickness, full-thickness autogenous skin grafts and donor sites. *Arch Surg* 91:658, 1965.
20. Cramer L, Hinshaw J: Autograft rejection induced by homografting. *Plast Reconstr Surg* 35:572, 1965.
21. Klein L: Reversible transformation of fibrous collagen to a soluble state in vivo. *PNAS* 62:920, 1969.
22. Klein L, Vessely JC, Heiple KG: Quantification of 3-H collagen loss of rat allografted and isografted tendon. *J Bone Joint Surg* 51:891, 1969.
23. Peacock EE Jr: Dynamic aspects of collagen biology. *J Surg Res* 7:433, 1967.
24. Dunphy JE, Udupa KN: Chemical and histochemical sequences in the normal healing of wounds. *N Engl J Med* 253:847, 1955.
25. Hilgert I: Changes in the hydroxyproline and hexosamine content of grafts after transplantation. *Folia Biol (Praha)* 91:136, 1963.
26. Marckmann A: Autologous skin grafts in the rat. Uptake of 3-5-S-sulfate. *Proc Soc Exp Biol Med* 119:557, 1965.
27. Udenfriend S: Formation of hydroxyproline in collagen. *Science* 152:1335, 1966.
28. Rudolph R, Klein L: Isotopic quantification of collagen turnover in skin grafts. *Surg Forum* 22:489, 1971.
29. Ohuchi K, Tsurufugi F: Degradation and turnover of collagen in the mouse skin and the effect of whole body x-irradiation. *Biochem Biophysiol Acta* 208:475, 1970.
30. Mac Neil S: What role does the extracellular matrix serve in skin grafting and wound healing? *Burns* 20:S67, 1994.
31. Pepper FJ: Studies on the viability of mammalian skin autografts after storage at different temperatures. *Br J Plast Surg* 6:250, 1954.
32. Clemmesen T: The early circulation in split skin grafts. *Acta Chir Scand* 124:11, 1962.

33. Clemmesen T: Experimental studies on the healing of free skin autografts. *Danish Med Bull* 14, Suppl 11, 1967.
34. Converse JM, Uhlenschmid GK, Ballantyne DL Jr: "Plasmatic circulation" in skin grafts. *Plast Reconstr Surg* 43:495, 1969.
35. Converse JM, Smahel J, Ballantyne DL Jr, Harper AD: Inosculation of vessels of skin graft and host bed: a fortuitous encounter. *Br J Plast Surg* 28:274, 1975.
36. Peer LA, Walker JC: The behaviour of autogenous human tissue grafts, I. *Plast Reconstr Surg* 7:6, 1951.
37. Peer LA: **Transplantation of Tissues**, Vol 2. Baltimore, Williams & Wilkins, 1955.
38. Birch J, Branemark PI: The vascularization of a free full-thickness skin graft. I. A vital microscopic study. *Scand J Plast Reconstr Surg* 3:1, 1969.
39. Birch J, Branemark PI, Lundskog J: The vascularization of a free full-thickness skin graft. II. A microangiographic study. *Scand J Plast Reconstr Surg* 3:11, 1969.
40. Birch J, Branemark PI, Nilsson K: The vascularization of a free full-thickness skin graft. III. An infrared thermographic study. *Scand J Plast Reconstr Surg* 3:18, 1969.
41. Psillakis JM, de Jorge FB, Villardo R, et al: Water and electrolyte changes in autogenous skin grafts. Discussion of the so-called "plasmatic circulation." *Plast Reconstr Surg* 43:500, 1969.
42. Haller JA, Billingham RE: Studies of the origin of the vasculature in free skin grafts. *Ann Surg* 166:896, 1967.
43. Converse JM, Rapaport FT: The vascularization of skin autografts and homografts; an experimental study in man. *Ann Surg* 143:306, 1956.
44. Converse JM, Ballantyne DL Jr, Rogers BO: A study of viable and non-viable skin grafts transplanted to the chorio-allantoic membrane of the chick embryo. *Transplant Bull* 5:108, 1958.
45. Converse JM, Filler M, Ballantyne DL: Vascularization of split-thickness skin autografts in the rat. *Transplantation* 3:22, 1965.
46. Zarem HA, Zweifach BW, McGehee JM: Development of microcirculation in full thickness autogenous skin grafts in mice. *Am J Physiol* 212:1081, 1967.
47. Ljungvist A, Almgard IE: The vascular reaction in the free skin allo- and autografts. *Acta Path Microbiol Scand* 68:553, 1966.
48. Wolff K, Schellander FG: Enzyme-histochemical studies on the healing process of split skin grafts. *J Invest Dermatol* 45:38, 1965.
49. Tsukada S: Transfer of free skin grafts with a preserved subcutaneous vascular network. *Ann Plast Surg* 4:500, 1980.
50. Eriksson G, Klingenstrom P, Nysten B, Wersall J: Electron microscopic studies on the epidermis in human split-skin autografts. *Scand J Plast Reconstr Surg* 2:83, 1968.
51. Zoltan J: Transplantationslehre. In: *Gohrbandt-Gabka-Berndorfer (eds), Handbuch der Plastischen Chirurgie, Band 1, Lieferung 3, Beitrag 12*. Berlin, Walter de Gruyter, 1965.
52. Kurul S: Is the groin region a good source for full-thickness skin graft? *J Surg Oncol* 77:281, 2001.
53. Shiffman MA: Re: Cervicomenta "turkey gobbler": a new source for full-thickness grafts (letter). *Dermatol Surg* 28:1099, 2002.
54. Lutz ME: Effective use of the glabella skin as a donor site for nasal tip grafts. *Dermatol Surg* 28:101, 2002.
55. Tiem C: Modification of split-thickness skin graft: cosmetic donor site and better recipient site. *Ann Plast Surg* 50:212, 2003.
56. Beck BW, Nagy D, Goldberg JS: Comparison of two techniques of dermal graft harvest for temporomandibular joint reconstruction. *J Oral Maxillofac Surg* 57:930, 1999.
57. Yildirim S, Akan M, Akoz T, Tanoglu B: The preputium: an overlooked skin graft donor site. *Ann Plast Surg* 46:630, 2001.
58. White N, Hettiaratchy S, Papini RPG: The choice of split-thickness skin graft donor site: patients' and surgeons' preferences (letter). *Plast Reconstr Surg* 112:933, 2003.
59. Imran D, Mandal A, Erdmann M: Using a sterilised glove as a stencil for planning grafts and flaps (letter). *Br J Plast Surg* 56:74, 2003.
60. Nagasao T, Shimada T, Nakajima T: Utilizing a surgical glove to trace skin defects on fingers (letter). *Plast Reconstr Surg* 111:1765, 2003.
61. Putterman AM: Blotter technique to determine the size of skin grafts (letter). *Plast Reconstr Surg* 112:335, 2003.
62. Wheeland RG: The technique and current status of pinch grafting. *J Dermatol Surg Oncol* 13:873, 1987.
63. Smahel J, Ganzoni N: Relay transplantation: a new method of expanding a free skin graft. *Br J Plast Surg* 28:49, 1975.
64. Knight SL, Moorghen M: Configurational changes within the dermis of meshed split skin grafts: a histological study. *Br J Plast Surg* 40:420, 1987.
65. Davison PM, Batchelor AG, Lewis-Smith PA: The properties and uses of non-expanded machine-meshed skin grafts. *Br J Plast Surg* 39:462, 1986.
66. Glogau RC, Stegman SJ, Tromovitch TA: Refinements in split-thickness skin grafting technique. *J Dermatol Surg Oncol* 13:853, 1987.
67. Richard R, Miller SF, Steinlage R, Finley RK Jr: A comparison of the Tanner and Bioplasty skin mesher systems for maximal skin graft expansion. *J Burn Care Rehabil* 14:690, 1993.
68. Kreis RW, Mackie DP, Hermans RK, Vloemans AR: Expansion techniques for skin grafts: comparison between mesh and Meek island (sandwich-) grafts. *Burns* 20:539, 1994.
69. Zhang ML, Wang CY, Chang ZD, et al: Microskin grafting. II. Clinical report. *Burns* 12:544, 1986.
70. Zhang ML, Chang ZD, Wang CY, Fang CH: Microskin grafting in the treatment of extensive burns: a preliminary report. *J Trauma* 28:804, 1988.
71. Lai C-Set al: An easy way to prepare microskin grafts. *Burns* 20:151, 1994.
72. Lin T-W: The algebraic view-point in microskin grafting in burned patients. *Burns* 20:347, 1994.
73. Lin T-W, Horng S-Y: A new method of microskin mincing. *Burns* 20:526, 1994.
74. Vandeput J, Tanner J: Easy way to prepare microskin grafts. *Burns* 20:476, 1994.
75. Wang LN, Hsu JH, Lu KH: Experimental studies on combined use of homografts and autografts. *Chin Med J* 4:221, 1973.
76. Yeh FL, Yu GS, Fang CH, et al: Comparison of scar contracture with the use of microskin and Chinese-type intermingled skin grafts on rats. *J Burn Care Rehabil* 11:221, 1990.

77. Hatchome N, Kato T, Tagami H: Therapeutic success of epidermal grafting in generalized vitiligo is limited by the Koebner phenomenon. *J Am Acad Dermatol* 22:87, 1990.
78. Christiansen J, Ek L, Tegner E: Pinch grafting of leg ulcers. A retrospective study of 412 treated ulcers in 146 patients. *Acta Derm Venereol (Stockh)* 77:471, 1997.
79. Eroglu L, Uysal OA: An easy and effective method for preparing meshed skin grafts (letter). *Plast Reconstr Surg* 108:1083, 2001.
80. Darcy CM: A technique for preparing meshed skin grafts with planned expansion ratios (letter). *Br J Plast Surg* 56:77, 2003.
81. Kirsner RS, Mata SM, Falanga V, Kerdel FA: Split-thickness skin grafting of leg ulcers. The University of Miami Department of Dermatology's experience (1990-1993). *Dermatol Surg* 21:701, 1995.
82. Yeh FL, Yu GS, Fang CH, et al: Comparison of scar contracture with the use of microskin and Chinese-type intermingled skin grafts on rats. *J Burn Care Rehabil* 11:221, 1990.
83. Burleson R, Eiseman B: Nature of the bond between partial-thickness skin and wound granulations. *Am Surg* 177:181, 1973.
84. Tavis MJ, Thornton JW, Harney JH, et al: Graft adherence to de-epithelialized surfaces: a comparative study. *Ann Surg* 184:594, 1976.
85. Netscher DT, Marchi M, Wigoda P: A method for optimizing skin graft healing and outcome of wounds of the penile shaft and scrotum. *Ann Plast Surg* 31:447, 1993.
86. Saltz R, Bowles BJ: Reston: an alternate method of skin graft fixation (letter). *Plast Reconstr Surg* 99:601, 1997.
87. Caldwell RK, Giles WC, Davis PT: Use of foam bolsters for securing facial skin grafts. *Ear Nose Throat J* 77:490, 1998.
88. Balakrishnan C: Dressing for skin grafts of the penis (letter). *Plast Reconstr Surg* 95:208, 1995.
89. Johnson PA, Fleming K, Avery CME: Latex foam and staple fixation of skin grafts. *Br J Oral Maxillofac Surg* 36:141, 1998.
90. Wolf Y, Kalish E, Badani E, et al: Rubber foam and staples: do they secure skin grafts? A model analysis and proposal of pressure enhancement techniques. *Ann Plast Surg* 40:149, 1998.
91. Smoot EC: A rapid method for splinting skin grafts and securing wound dressings (letter). *Plast Reconstr Surg* 100:1622, 1997.
92. Amir A, Sagi A, Fliss DM, Rosenberg L: A simple, rapid, reproducible tie-over dressing. *Plast Reconstr Surg* 98:1092, 1996.
93. Cheng LC, Lim TC, Tan WTL: A simple tie-over dressing (letter). *Plast Reconstr Surg* 101:246, 1998.
94. Vloemans AFPM, Kreis RW: Fixation of skin grafts with a new silicone rubber dressing (Mepitel). *Scand J Plast Reconstr Surg* 28:75, 1994.
95. Sawada Y, Yotsuyanagi T, Ara M, Sone K: Experiences using silicone gel tie-over dressings following skin grafting. *Burns* 16:353, 1990.
96. Renz BM, Stout M, Sherman R: Rubberband stents for skin grafts: how I do it. *Am Surg* 60:707, 1994.
97. Ren J, Yiang OJ, Deng B, Yiang YN: Transparent gasbag tie-over for persistent pressure and inspection in free skin grafting. *Plast Reconstr Surg* 95:396, 1995.
98. Ward RS, Reddy R, Brockway C, et al: Uses of Coban self-adherent wrap in management of postburn hand grafts: case reports. *J Burn Care Rehabil* 15:364, 1994.
99. Grabski WJ, Giandoni MB, Anderson LL: Surgical pearl: hydrocolloid dressings for full-thickness skin grafts. *J Am Acad Dermatol* 32:273, 1995.
100. Watson SB, Miller JG: Optimizing skin graft take in children's hand burns—the use of Silastic foam dressings. *Burns* 19:519, 1993.
101. Balakrishnan C: Simple method of applying pressure to skin grafts of neck with foam dressing and staples. *J Burn Care Rehabil* 15:432, 1994.
102. Wells MD, Kirn DS: A new method of skin-graft stabilization: the Reston technique. *Ann Plast Surg* 34:554, 1995.
103. Butler CE: "Tongue sandwich" bolster for skin graft immobilization. *Head Neck* 24:705, 2002.
104. Yoshitatsu S, Takagi T: A new tie-over method improves cosmetic results (letter). *Dermatol Surg* 28:542, 2002.
105. Godley FA: Experience with the malleable ear dressing, a versatile silicone-lined bandage for the auricle. *Ear Nose Throat J* 82:570, 2003.
106. Stuart JD, Morgan RF, Kenney JG: Single-donor fibrin glue for hand burns. *Ann Plast Surg* 24:524, 1990.
107. Saltz R, Sierra D, Feldman D, et al: Experimental and clinical applications of fibrin glue. *Plast Reconstr Surg* 88:1005, 1991.
108. Cederholm-Williams SA: Benefits of adjuvant fibrin glue in skin grafting. *Med J Aust* 161:575, 7 Nov 1994.
109. Dean M, Nicholls M, Wedderburn C: Benefits of adjuvant fibrin glue in skin grafting. *Med J Aust* 160:526, 18 Apr 1994.
110. Achauer BM, Miller SR, Lee TE: The hemostatic effect of fibrin glue on graft donor sites. *J Burn Care Rehabil* 15:24, 1994.
111. Currie LJ, Sharpe JR, Martin R: The use of fibrin glue in skin grafts and tissue-engineered skin replacements: a review. *Plast Reconstr Surg* 108:1713, 2001.
112. Hallock GG: Expanded applications for octyl-2-cyanoacrylate as a tissue adhesive. *Ann Plast Surg* 46:185, 2001.
113. Kilic A, Ozdengil E: Skin graft fixation by applying cyanoacrylate without any complication (letter). *Plast Reconstr Surg* 110:370, 2002.
114. Schneider AM, Morykwas MJ, Argenta LC: A new and reliable method of securing skin grafts to the difficult recipient bed. *Plast Reconstr Surg* 102:1195, 1998.
115. Hynes PJ, Earley MJ, Lawlor D: Split-thickness skin grafts and negative-pressure dressings in the treatment of axillary hidradenitis suppurativa. *Br J Plast Surg* 55:507, 2002.
116. Wallenberg L: Effect of early mobilisation after skin grafting to lower limbs. *Scand J Plast Reconstr Hand Surg* 33:411, 1999.
117. Scherer LA, Shiver S, Chang M, et al: The vacuum assisted closure device. A method of securing skin grafts and improving graft survival. *Arch Surg* 137:930, 2002.

118. Allen HE, Edgerton MT, Rodeheaver GT, et al: Skin dressings in the treatment of contaminated wounds. *Am J Surg* 126:45, 1973.
119. Szabo SE, Toomey JM, Linn BS: Does skin have antimicrobial properties? An in-vitro experiment and literature review. *Am Surg* 44:55, 1978.
120. Feldman DL: Which dressing for split-thickness skin graft donor sites? *Ann Plast Surg* 27:288, 1991.
121. Wood RJ, Peltier GL, Twomey JA: Management of the difficult split-thickness donor site. *Ann Plast Surg* 22:80, 1989.
122. Gallico GG III: Biologic skin substitutes. *Clin Plast Surg* 17:519, 1990.
123. Brans TA, Hoekstra MJ, Vloemans AFPM, Kreis RW: Long-term results of treatment of scalds in children with glycerol-preserved allografts. *Burns* 20:510, 1994.
124. Peeters R, De Caluwe D, Neetens C, Hubens A: Use of glycerolized cadaver skin for the treatment of scalds in children. *Burns* 20:532, 1994.
125. Hussman J, Russell RC, Kucan JO, et al: Use of glycerolized human allografts as temporary (and permanent) cover in adults and children. *Burns* 20(Suppl 1):S61, 1994.
126. Schiozer WA, Hartinger A, von Donnersmarck GH, Muhlbauer W: Composite grafts of autogenic cultured epidermis and glycerol-preserved allogeneic dermis for definitive coverage of full thickness burn wounds: case reports. *Burns* 20:503, 1994.
127. McKay I, Woodward B, Wood K, et al: Reconstruction of human skin from glycerol-preserved allodermis and cultured keratinocyte sheets. *Burns* 20(Suppl 1):S19, 1994.
128. Phipps AR, Clarke JA: The use of intermingled autograft and prental allograft skin in the treatment of major burns in children. *Br J Plast Surg* 44:608, 1991.
129. Feldman DL, Karpinski RHS: A prospective trial comparing Biobrane, DuoDERM, and xeroform for skin graft donor sites. *Surg Gynecol Obstet* 173:1, 1991.
130. Morris WT, Lamb AM: Painless split skin donor sites: a controlled double-blind trial of Op-Site, scarlet red, and bupivacaine. *Aust N Z J Surg* 60:617, 1990.
131. Brady SC, Snelling CFT, Chow G: Comparison of donor site dressings. *Ann Plast Surg* 5:238, 1980.
132. Barnett A, Berkowitz RL, Mills R, Vistnes LM: Comparison of synthetic adhesive moisture vapor permeable and fine mesh gauze dressings for split-thickness skin graft donor sites. *Am J Surg* 145:379, 1983.
133. Poonyakariyagorn T, Sirimaharaj W, Pinchai O, Angspatt A: Comparison among Op-site, polyvinyl chloride film and tulle gauze in the treatment of skin graft donor sites. *J Med Assoc Thai* 85:455, 2002.
134. Zapata-Sirvent R, Hansbrough JF, Carroll W, et al: Comparison of Biobrane and Scarlet Red dressings for treatment of donor site wounds. *Arch Surg* 120:743, 1985.
135. Tavis MJ, Thornton J, Danet R, Bartlett RH: A new composite skin prosthesis. *Burns* 7:123, 1981.
136. Poulsen TD, Freund KG, Arendrup K, et al: Polyurethane film (Opsite*) vs. impregnated gauze (Jelonet*) in the treatment of outpatient burns: a prospective, randomized study. *Burns* 17:59, 1991.
137. Malpass KG, Snelling CFT, Tron V: Comparison of donor-site healing under xeroform and Jelonet dressings: unexpected findings. *Plast Reconstr Surg* 112:430, 2003.
138. Nemeth AJ, Eaglstein WH, Taylor JR, et al: Faster healing and less pain in skin biopsy sites treated with an occlusive dressing. *Arch Dermatol* 127:1679, 1991.
139. Lawrence JE, Blake GB: A comparison of calcium alginate and scarlet red dressings in the healing of split thickness skin graft donor sites. *Br J Plast Surg* 44:247, 1991.
140. Porter JM: A comparative investigation of reepithelialisation of split skin graft donor areas after application of hydrocolloid and alginate dressings. *Br J Plast Surg* 44:333, 1991.
141. Sawada Y, Yotsuyanagi T, Sone K: A silicone gel sheet dressing containing an antimicrobial agent for split thickness donor site wounds. *Br J Plast Surg* 43:88, 1990.
142. Owen TD, Dye D: The value of topical lignocaine gel in pain relief on skin graft donor sites. *Br J Plast Surg* 43:480, 1990.
143. Azad S, Sacks L: Modified application of alginate dressings on graft donor sites (letter). *Br J Plast Surg* 55:177, 2002.
144. Misirlioglu A, Eroglu S, Karacaoglan N, et al: Use of honey as an adjunct in the healing of split-thickness skin graft donor site. *Dermatol Surg* 29:168, 2003.
145. Gloor M, Ludwig G: Revascularization of free full-thickness skin autografts. *Arch Dermatol Forsch* 246:211, 1973.
146. McGregor IA, Conway H: Development of lymph flow from autografts and homografts of skin. *Transplant Bull* 3:46, 1956.
147. Corps BVM: The effect of graft thickness, donor site and graft bed on graft shrinkage in the hooded rat. *Br J Plast Surg* 22:125, 1969.
148. Padgett EC: Calibrated intermediate skin grafts. *Plast Reconstr Surg* 39:195, 1967.
149. Rudolph R: The effect of skin graft preparation on wound contraction. *Surg Gynecol Obstet* 142:49, 1976.
150. Bertolami C, Donoff RB: The effect of full-thickness skin grafts on the actomyosin content of contracting wounds. *J Oral Surg* 37:471, 1979.
151. Bertolami CN, Donoff RB: The effect of skin grafting upon prolyl hydroxylase and hyaluronidase activities in mammalian wound repair. *J Surg Res* 27:359, 1979.
152. Brown D, Garner W, Young VL: Skin grafting: dermal components in inhibition of wound contraction. *South Med J* 83:789, 1990.
153. Rudolph R, Suzuki M, Guber S, Woodward M: Control of contractile fibroblasts by skin grafts. *Surg Forum* 28:524, 1977.
154. Rudolph R: Inhibition of myofibroblasts by skin grafts. *Plast Reconstr Surg* 63:473, 1979.
155. Montandon D, Gabbiani G, Ryan GB, Majno G: The contractile fibroblast: its relevance in plastic surgery. *Plast Reconstr Surg* 52:286, 1973.
156. Oliver RF, Grant RA, Kent CM: The fate of cutaneously and subcutaneously implanted trypsin purified dermal collagen in the pig. *Br J Exp Pathol* 53:540, 1972.
157. Oliver RF, Grant RA, Hulme MJ, Mudie A: Incorporation of stored cell-free dermal collagen allografts into skin wounds: a short term study. *Br J Plast Surg* 30:88, 1977.
158. Walden JL, Garcia H, Hawkins H, et al: Both dermal matrix and epidermis contribute to an inhibition of wound contraction. *Ann Plast Surg* 45:162, 2000.
159. Waris T, Astrand K, Hamalainen H, et al: Regeneration of cold, warmth and heat-pain sensibility in human skin grafts. *Br J Plast Surg* 42:576, 1989.
160. Haro JJ, Del Valle ME, Calzada B, et al: Human glabrous skin autografts partially reinnervated without sensory corpuscles. An immunohistochemical study. *Scand J Plast Reconstr Hand Surg* 28:25, 1994.

161. Stella M, Calcagni M, Teich-Alasia S, et al: Sensory endings in skin grafts and scars after extensive burns. *Burns* 20:491, 1994.
162. Ponten B: Grafted skin. Observations on innervation and other qualities. *Acta Chir Scand Suppl* 257, 1960.
163. Adeymo O, Wyburn G: Innervation of skin grafts. *Transplantation* 4:152, 1957.
164. Fitzgerald MJT, Martin F, Paletta FX: Innervation of skin grafts. *Surg Gynecol Obstet* 124:808, 1967.
165. Weis-Becker C, Fruhstorfer H, Friederich H-C, Winter H: Reinnervation of split skin grafts in humans: comparison of two different methods of operation. *Scand J Plast Reconstr Hand Surg* 32:157, 1998.
166. Conway H, Sedar J: Report of the loss of pigment in full thickness autoplasmic skin grafts in the mouse. *Plast Reconstr Surg* 18:30, 1956.
167. Mir y Mir L: The problem of pigmentation in the cutaneous graft. *Br J Plast Surg* 14:303, 1961.
168. Taki T, Kozuka S, Izawa Y, et al: Surgical treatment of skin depigmentation caused by burn injuries. *J Dermatol Surg Oncol* 11:1218, 1985.
169. Jarrett A, Szabo G: The pathologic varieties of vitiligo and their response to treatment with mladinin. *Br J Dermatol* 68:313, 1956.
170. Falabella R: Repigmentation of leukoderma by autologous epidermal grafting. *J Dermatol Surg Oncol* 10:136, 1984.
171. Hatchome N, Kato T, Tagami H: Therapeutic success of epidermal grafting in generalized vitiligo is limited by the Koebner phenomenon. *J Am Acad Dermatol* 22:87, 1990.
172. Kahn AM, Cohen MJ: Vitiligo: treatment by dermabrasion and epithelial sheet grafting—a preliminary report. *J Am Acad Dermatol* 28:773, 1993.
173. Behl PN: Vitiligo: treatment by dermabrasion and epithelial sheet grafting (letter). *J Am Acad Dermatol* 30:1044, 1994.
174. Achauer BM, Le Y, Vander Kam VM: Treatment of vitiligo with melanocytic grafting. *Ann Plast Surg* 33:644, 1994.
175. Olsson MJ, Juhlin L: Epidermal sheet grafts for repigmentation of vitiligo and piebaldism, with a review of surgical techniques. *Acta Derm Venereol (Stockh)* 77:463, 1997.
176. Yang JS, Kye YC: Treatment of vitiligo with autologous epidermal grafting by means of pulsed erbium:YAG laser. *J Am Acad Dermatol* 38(2 Pt 1):280, 1998.
177. Kahn AM, Cohen MJ: Repigmentation in vitiligo patients. Melanocyte transfer via ultra-thin grafts. *Dermatol Surg* 24:365, 1998.
178. Kaufmann R, Greiner D, Kippenberger S, Bernd A: Grafting of in vitro cultured melanocytes onto laser-ablated lesions in vitiligo. *Acta Derm Venereol (Stockh)* 78:136, 1998.
179. Hosokawa K, Hata Y, Yano K, et al: Treatment of tattoos with pure epidermal sheet grafting. *Ann Plast Surg* 24:53, 1990.
180. Webster GV: Annual report to the American Society of Plastic and Reconstructive Surgeons. Hollywood, Florida, October 1954.
181. Rees TD, Casson PR: The indications for cutaneous dermal overgrafting. *Plast Reconstr Surg* 38:522, 1966.
182. Flowers R: Unexpected postoperative problems in skin grafting. *Surg Clin North Am* 50:439, 1970.
183. Seymour FK, Giele HP: Tie-overs under pressure. *Br J Plast Surg* 56:494, 2003.
184. Teh BT: Why do skin grafts fail? *Plast Reconstr Surg* 63:323, 1979.
185. Thourani VH, Ingram WL, Feliciano DV: Factors affecting success of split-thickness skin grafts in the modern burn unit. *J Trauma* 54:562, 2003.
186. Hill TG: Enhancing the survival of full-thickness grafts. *J Dermatol Surg Oncol* 10:639, 1984.
187. Wolfort S, Rohrich RJ, Handren J, May JW Jr: The effect of epinephrine in local anesthesia on the survival of full- and split-thickness skin grafts: an experimental study. *Plast Reconstr Surg* 86:535, 1990.
188. Fazio MJ, Zitelli JA: Full-thickness skin grafts. Clinical observations on the impact of using epinephrine in local anesthesia of the donor site. *Arch Dermatol* 131:691, 1995.
189. Robson MC, Krizek TJ: Predicting skin graft survival. *J Trauma* 13:213, 1973.
190. Perry AW, Sutkin HS, Gottlieb LJ, et al: Skin graft survival—the bacterial answer. *Ann Plast Surg* 22:479, 1989.
191. Pruitt BA Jr, Levine NS: Characteristics and uses of biologic dressings and skin substitutes. *Arch Surg* 119:312, 1984.
192. Beele H: Artificial skin: past, present and future. *Int J Artif Organs* 25:163, 2002.
193. Jones I, Currie L, Martin R: A guide to biological skin substitutes. *Br J Plast Surg* 55:185, 2002.
194. Purdue GF, Hunt JL, Still JM Jr, et al: A multicenter clinical trial of a biosynthetic skin replacement, Dermagraft-TC, compared with cryopreserved human cadaver skin for temporary coverage of excised burn wounds. *J Burn Care Rehabil* 18:52, 1997.
195. Bello YM, Falabella AF: Use of skin substitutes in dermatology. *Dermatol Clin* 19:555, 2001.
196. Nanchahal J, Dover R, Otto WR: Allogeneic skin substitutes applied to burn patients. *Burns* 28:254, 2002.
197. Carucci JA, Kolenik SA III, Leffell DJ: Human cadaveric allograft for repair of nasal defects after extirpation of basal cell carcinoma by Mohs micrographic surgery. *Dermatol Surg* 28:340, 2002.
198. Gohari S, Gambla C, Healey M, et al: Evaluation of tissue-engineered skin (human skin substitute) and secondary intention healing in the treatment of full thickness wounds after Mohs micrographic or excisional surgery. *Dermatol Surg* 28:1107, 2002.
199. Ozerdem OR, Wolfe SA, Marshall D: Use of skin substitutes in pediatric patients. *J Craniofac Surg* 14:517, 2003.
200. Hansbrough JF, Dore C, Hansbrough WB: Clinical trials of a living dermal tissue replacement placed beneath meshed, split-thickness skin grafts on excised burn wounds. *J Burn Care Rehabil* 13:519, 1992.
201. Ramos-e-Silva M, Ribeiro de Castro MC: New dressings, including tissue-engineered living skin. *Clin Dermatol* 20:715, 2002.
202. Donati L, Magliacani G, Bormioli M, et al: Clinical experiences with keratinocyte grafts. *Burns (Suppl 1):S19*, 1992.
203. Latarjet J, Gangolphe M, Hezez G, et al: The grafting of burns with cultured epidermis as autografts in man. Two case reports. *Scand J Plast Reconstr Surg* 21:241, 1987.
204. Thivolet J, Faure M, Demidem A, Mauduit G: Long-term survival and immunological tolerance of human epidermal allografts produced in culture. *Transplantation* 42:274, 1986.
205. Still JM Jr, Orlet HK, Law EJ: Use of cultured epidermal autografts in the treatment of large burns. *Burns* 20:539, 1994.
206. Sheridan RL, Tompkins RG: Cultured autologous epithelium in patients with burns of ninety percent or more of the body surface. *J Trauma* 38:48, 1995.
207. Kumagi N, Nishina H, Tanabe H, et al: Clinical applications of autologous cultured epithelia for the treatment of burn wounds and burn scars. *Plast Reconstr Surg* 82:99, 1988.

PRINCIPLES OF FLAPS

Amanda A Gosman MD

DEFINITIONS

A flap is a unit of tissue that maintains its own blood supply while being transferred from a donor to a recipient site. In contrast, grafts are transferred unattached to a vascular source and rely on the blood supply at the recipient site for their survival. Flaps range from simple advancements of skin and subcutaneous tissue to composite flaps that may contain any combination of skin, muscle, bone, fat, or fascia.

HISTORY AND EVOLUTION

The origin of the term flap originated from the 16th century Dutch word “flappe”, meaning something that hung broad and loose, fastened only on one side.¹ The history of plastic surgical repair with flaps can be documented as far back as 600 BC, when Sushruta Samita described nasal reconstruction using a cheek flap. The origins of forehead rhinoplasty can be traced to India about 1440 AD, but probably was practiced long before the birth of Christ.² These surgical procedures involved the use of rotation flaps, which transport skin to an adjacent area while twisting or rotating a pedicle. The French are credited with the original description of sliding or advancement type flaps, which transfer skin from an adjacent area without torsion of the base. Distant pedicled flaps, which transfer tissue to a remote site, were initially reported in the Italian literature during the Renaissance.³

Subsequent flap evolution happened in phases. First there was an early period during the First and Second World Wars when pedicled skin flaps were used extensively. The next period occurred in the 1950s and '60s, when what we now recognize as regional axial pattern flaps were reported. A third period took place mainly during the 1970s, when a distinction was made between axial and random flaps, muscle and musculocutaneous flaps were elevated and transferred, and free tissue transfer came into being. The 1980s saw the development of fasciocutaneous flaps, osseous and osseocutaneous flaps, and specialized free flaps.^{1,4}

In 1984 Song et al⁵ introduced the free thigh flap based on perforating septocutaneous arteries in the thigh. This was the first reported description of the now very popular anterolateral thigh flap. Koshima and Soeda⁶ coined the term “perforator flap” in 1989 while reporting on inferior epigastric artery flaps based on a single musculocutaneous perforator vessel. The original perforator flaps were transfers of skin territories based on a named vascular pedicle to a muscle while preserving the muscle and its innervation.⁶⁻¹⁰ The perforator concept has evolved since the development of supermicrosurgery.¹¹ Skin flaps are now successfully transferred based on the small perforating vessel alone, without dissection of the named vascular pedicle. Supermicrosurgical techniques facilitate the anastomosis of vessels 0.5 mm in diameter.¹²⁻¹⁴

The recent innovations in perforator flap surgery represent a shift toward esthetic free flap refinements and attempts to minimize donor site morbidity. Thin, super-thin, and micro-thin perforator flaps have further advanced the esthetic reconstruction (Fig 1) of defects requiring coverage with fine pliable tissue.¹⁵⁻¹⁹ The future of perforator flaps may lie in the clinical application of angiosomes²⁰ and the creation of “free-style free flaps” in which a perforator localized by Doppler signal can be the basis for a skin flap in any anatomic region.²¹⁻²⁵

VASCULAR ANATOMY OF THE SKIN

Arterial Anatomy

In 1889 Manchot²⁶ described cutaneous vascular territories. In 1964 Seitchik and Kahn²⁷ studied the anatomy of the “intrinsic circulation” of the skin and observed that arterial branches penetrate the superficial layer of the superficial fascia and join a subdermal plexus of arteries terminating in skin capillaries. The venous drainage system paralleled the arterial system. Spalteholz²⁸ in 1893 demonstrated anatomically that the circulation to the skin via subdermal and dermal plexuses could be

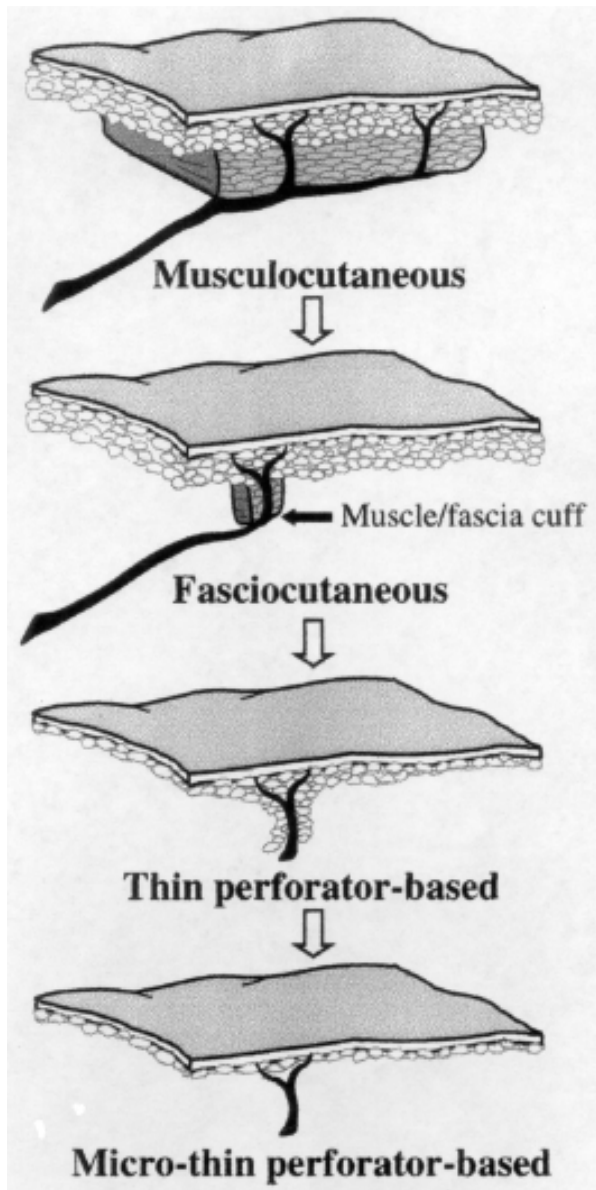


Fig 1. The evolution of the ultrathin perforator-based flap. (Reprinted with permission from Hallock GG: Discussion of "A microdissected thin tensor fasciae latae perforator flap" by N Kimura. *Plast Reconstr Surg* 109:78, 2002.)

fed by either direct or indirect branches from an underlying source vessel²⁹ (Fig 2).

Taylor and Palmer²⁰ propose two theories of the blood supply to tissues. The first defines the *angiosome* which is a composite unit of skin and its underlying deep tissue supplied by a source artery. The second defines the routes by which the integument is supplied by that source artery. The *direct* route encompasses vessels that are primarily directed towards the skin, whether they follow the

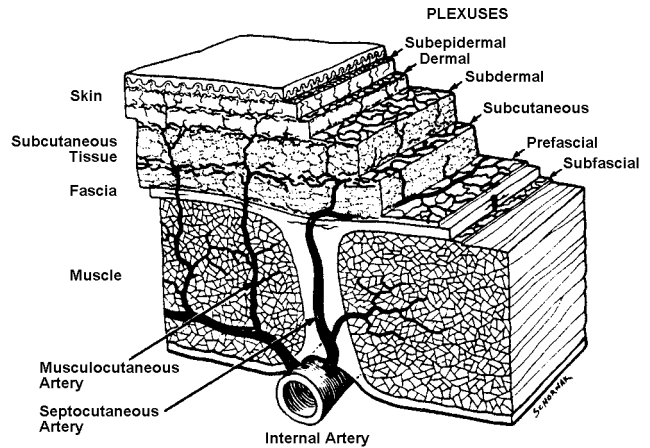


Fig 2. The cutaneous circulation. (Reprinted with permission from Daniel RK, Kerrigan CL: *Principles and Physiology of Skin Flap Surgery*. In: McCarthy JG (ed), **Plastic Surgery**. Philadelphia, Saunders, 1990. Vol 1, Ch 9.)

intermuscular septum or pierce the muscle. The *indirect* route constitutes vessels whose main supply is either to muscle or another deep tissue and only secondarily supply the skin. The following remarks are based on the results of their study.

1. The blood supply of the body courses within or adjacent to the connective tissue framework, whether it is bone, septa or fascia.
2. The vessels course from fixed loci to mobile areas.
3. The vascular outflow is a continuous system of arteries linked predominantly by reduced caliber vessels, ie, the choke arteries and arterioles.
4. The body is a three-dimensional jigsaw made up of composite blocks of tissue supplied by named source arteries. The arteries supplying these blocks of tissue are responsible for the supply of the skin and the underlying structures. These composite units we have named **ANGIOSOMES**.

Taylor and Palmer (1987)

Taylor and Palmer²⁰ described 40 angiosomes (Fig 3) that are linked to each other by "true" anastomotic arteries of similar caliber or reduced caliber "choke" anastomotic vessels.³⁰ The choke vessels can potentially dilate to the caliber of a true anastomosis after surgical delay or with a decrease in sympathetic tone. The angiosome theory has more recently been applied in detailed anatomic investigations of the forearm, lower extremity, and head and neck.³¹⁻³³ Although many important

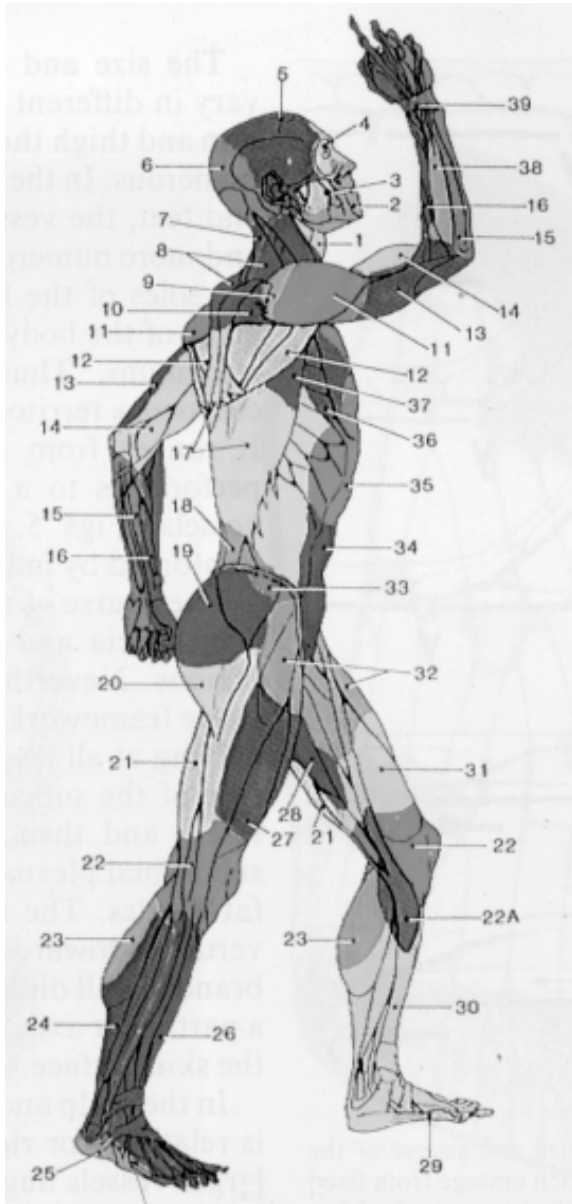


Fig 3. The angiosomes of the source arteries of the body. They are: (1) thyroid; (2) facial; (3) buccal; (4) ophthalmic; (5) superficial temporal; (6) occipital; (7) deep cervical; (8) transverse cervical; (9) acromiothoracic; (10) suprascapular; (11) posterior circumflex humeral; (12) circumflex scapular; (13) profunda brachii; (14) brachial; (15) ulnar; (16) radial; (17) posterior intercostals; (18) lumbar; (19) superior gluteal; (20) inferior gluteal; (21) profunda femoris; (22) popliteal; (22a) descendin geniculate (saphenous); (23) sural; (24) peroneal; (25) lateral plantar; (26) anterior tibial; (27) lateral femoral circumflex; (28) adductor (profunda); (29) medial plantar; (30) posterior tibial; (31) superficial femoral; (32) common femoral; (33) deep circumflex iliac; (34) deep inferior epigastric; (35) internal thoracic; (36) lateral thoracic; (37) thoracodorsal; (38) posterior interosseous; (39) anterior interosseous; (40) internal pudendal. (Reprinted with permission from Taylor GI, Palmer JH: *The vascular territories (angiosomes) of the body: experimental study and clinical applications.* *Br J Plast Surg* 40:113, 1987.)

regional differences were identified, the authors confirmed that in most cases connections between adjacent angiosomes occurred within tissues and not between them.

McGregor³⁴ acknowledges that Taylor and Palmer's findings have practical application in the design of skin flaps, but stress the limitations in their conclusions due to the static nature of the specimens used. To determine skin perfusion patterns, McGregor performed intraarterial fluorescein injection studies on 23 patients undergoing abdominal reduction. In 78.3% of patients the distribution of fluorescein was over a much smaller region than would be expected from Taylor and Palmer's study. McGregor notes that unlike the Taylor injections, which were performed in fresh cadavers, his study was performed in living patients whose vascular resistance is physiologic rather than anatomic. He also found that "the watershed between adjacent territories does not correspond to the choke arteries described at the periphery of the angiosome," and suggested that the term "choke artery" be abandoned.

Nakajima³⁵ conceptualized the vascular supply to the skin as an epifascial vascular network which is fed by different configurations of inflow vessels. The network is present throughout the subcutaneous layer between the subdermal plexus and the deep fascia. The architecture of this network varies according to anatomic region but, like the subdermal plexus, it extends throughout the body as a continuous system. This epifascial vascular network is present throughout the superficial fascia and is called the fasciocutaneous plexus.

Nakajima³⁵ identified six vessel types that perforate the deep fascia to supply the fasciocutaneous plexus: A) direct cutaneous; B) direct septocutaneous; C) direct cutaneous branch of muscular vessel; D) perforating cutaneous branch of muscular vessel; E) septocutaneous perforator; F) musculocutaneous perforator (Fig 4). Types A and B arise from the source vessel and supply a large axial territory above the deep fascia. Types C and D arise from the muscular vessel and supply the fasciocutaneous plexus and skin axially over the muscle. Types E and F arborize under, in, and above the deep fascia. These perforators supply a small vascular territory and cannot support axial skin patterns.

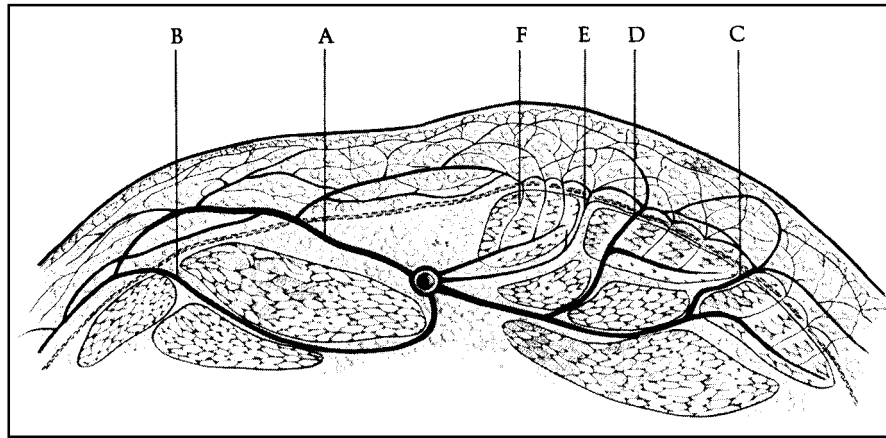


Fig 4. Six patterns of blood supply to the fasciocutaneous plexus: A, direct cutaneous vessel; B, direct septocutaneous vessel; C, direct cutaneous branch of muscular vessel; D, perforating cutaneous branch of muscular vessel; E, septocutaneous perforator; F, musculocutaneous perforator. (Reprinted with permission from Nakajima H, Fujino T, Adachi S: A new concept of vascular supply to the skin and classification of skin flaps according to their vascularization. *Ann Plast Surg* 16:1, 1986.)

Nakajima and coauthors³⁶ studied the 3-dimensional structure of the blood supply to the skin and subcutaneous tissue. Computer images of angiograms performed on 28 segmental arteries of the body were analyzed according to the tissue layer in which they were dominant (whether dermal, superficial, or deep adipofascial layers), their axiality, and their size. After perforating the deep fascia, the arteries were assigned to one of six different types (Fig 5). The arteries were localized on a whole body map and the relationship between the type of artery and the mobility of the tissue it supplied was considered.

Nakajima's six types of arterial configuration evolved from his previous perforator classification.³⁵ Types I and II are continuations of direct cutaneous and direct septocutaneous perforators (Types A and B), respectively. Types I and II are mobile vascular types that show axiality and are located in the deep adipofascial layer. Types III and IV are peripheral continuations of either the direct cutaneous branch or perforating cutaneous branch of a muscular vessel (Types C and D). Types II and IV are of medium size and of moderate axiality, but have diverging branch points. Type III is dominant in the deep adipofascial layer and IV is dominant in the superficial layer, resulting in a reciprocal relationship. Types V and VI (Types E and F) are fixed vascular types of little axiality and are continuations of small septocutaneous and musculocutaneous perforators, respectively (Fig 6). In the torso types I, III, and IV are localized in the

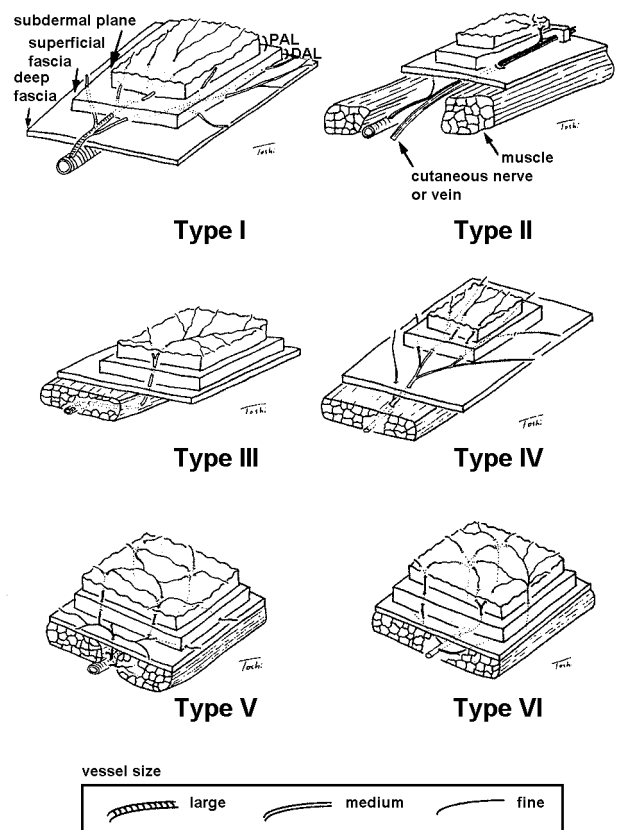


Fig 5. Six types of 3-dimensional arterial structure. See text for details. (Reprinted with permission from Nakajima H, Minabe T, Imanishi N: Three-dimensional analysis and classification of arteries in the skin and subcutaneous adipofascial tissue by computer graphics imaging. *Plast Reconstr Surg* 102:748, 1998.)

mobile tissue at or around joints. Type VI vessels are more common in fixed skin areas, such as the center of the back. Types II, V, and VI are dominant in the extremities. Type II accompanies cutaneous nerves and veins that run in the deep adipofascial layer. It is important to know the subcutaneous depth of a pedicle's plexus when elevating thin flaps and adipofascial flaps.

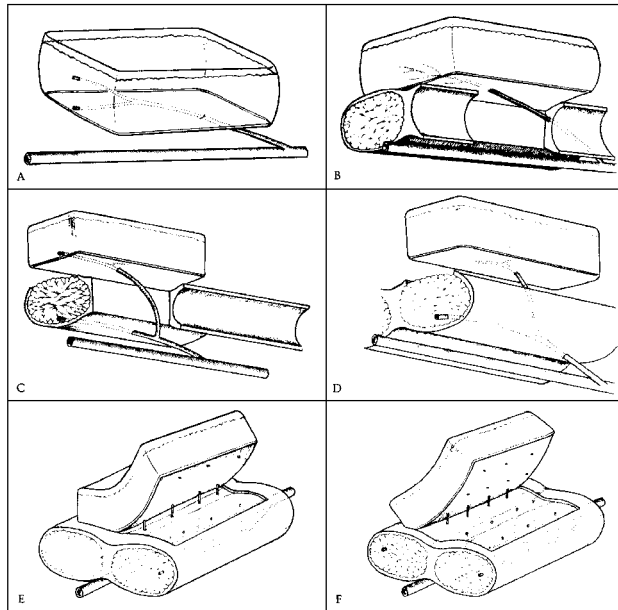


Fig 6. Classification of fasciocutaneous flaps. A, Type I is supplied by the direct cutaneous vessel. B, Type II is supplied by the direct septocutaneous vessel. C, Type III is supplied by the direct cutaneous branch of the muscular vessel. D, Type IV is supplied by the perforating cutaneous branch of the muscular vessels. E, Type V is supplied by the septocutaneous perforator. F, Type VI is supplied by the musculocutaneous perforator. (Reprinted with permission from Nakajima H, Fujino T, Adachi S: A new concept of vascular supply to the skin and classification of skin flaps according to their vascularization. *Ann Plast Surg* 16:1, 1986.)

Venous Anatomy

There are two systems of venous drainage of the skin and subcutaneous tissue. Taylor and colleagues³⁷ studied the venous territories (venosomes) of the body and showed that the cutaneous venous plexus is composed of valvular superficial and deep cutaneous veins that parallel the course of adjacent arteries, and of oscillating avaluular veins that permit bidirectional flow between adjacent venous territories (Fig 7).

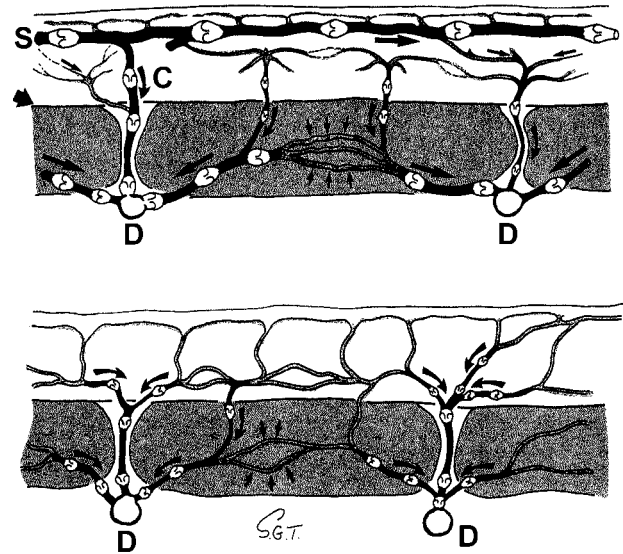
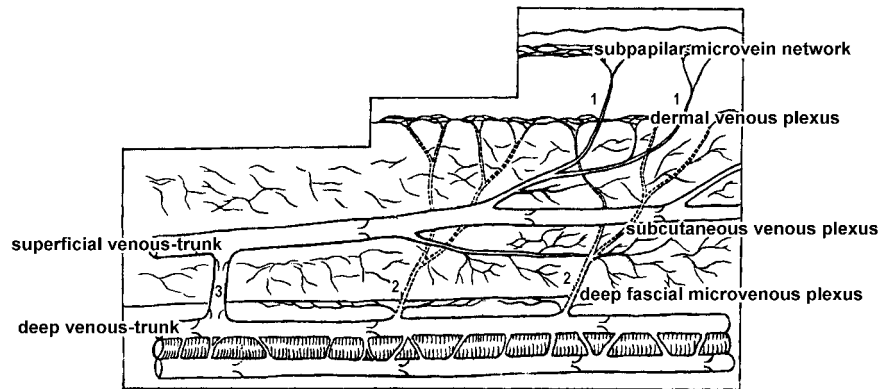


Fig 7. Above, The superficial (S) and deep (D) venous systems in an extremity. A large vena comunicans (C) connects these systems, and the alternative pathways of four venae comitantes are shown. Below, Other regions where the predominant venous drainage is by means of the venae comitantes. (Reprinted with permission from Taylor GI, Caddy CM, Watterson PA, Crock JG: The venous territories (venosomes) of the human body: experimental study and clinical implications. *Plast Reconstr Surg* 86:185, 1990.)

Zhong and coworkers³⁸ classified the venous architecture of the skin and subcutaneous tissue into four superimposed layers that are drained by two large venous trunks, a superficial and a deep (Fig 8). The superficial venous trunks are located in the subcutaneous tissue and do not accompany arteries. The deep venous trunks are the venae comitantes of the source artery. The authors propose that the main venous drainage of an anatomic region can be primarily via the deep venous trunk, the superficial venous trunk, or both.

Imanishi and others³⁹⁻⁴¹ described the venous drainage of the skin and subcutaneous tissue of the forearm, scapular region, and temporal and parietal regions. A similar pathway of venous drainage was identified in each anatomic region. Small epidermal and dermal branches were collected into a superficial polygonal venous network located in the deep dermis or superficial adipofascial layer. Osteal valves were identified at the anastomosis of the first draining dermal branches and the polygonal venous network to resist reflux. Dermal blood can pool in the polygonal network, which has a variable distribution of valves depending on anatomic region,

Fig 8. The venous architecture of skin flaps. (Reprinted with permission from Zhong SZ, Wang GY, Yuan L, Xu DC: *Anatomic basis of venous drainage in donor flaps. Surg Radiol Anat* 16:349, 1994.)



and which eventually drains into large cutaneous veins. The authors distinguish between a *superficial vein* that is located above the deep fascia and a *cutaneous vein* that is superficial and does not accompany an artery.⁴¹ Cutaneous venous trunks are the primary drainage of the dermis and are connected by various communicating branches to the venae comitantes of the source artery (Fig 9).

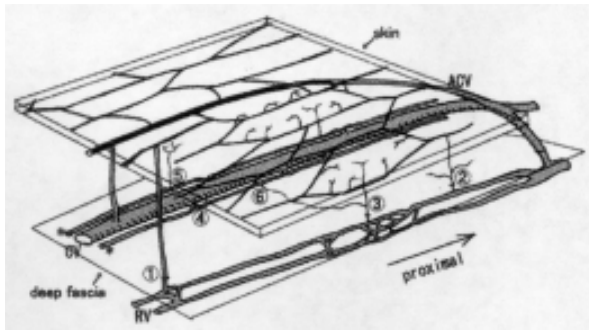


Fig 9. Polygonal venous network of the forearm. (1) Large ascending vein. (2) Small ascending vein that anastomosed with the venous network. (3) Small ascending vein that anastomosed with ascending vessels from the venous network. (4) Anastomosis of the long vein with the cephalic vein. (5 and 6) Branches that anastomosed small ascending vessels from the venous network and venae comitantes of the radial artery. ACV, accessory cephalic vein; CV, cephalic vein; RV, radial vein (venae comitantes). (Reprinted with permission from Imanishi N, Nakajima H, Aiso S: *Anatomical study of the venous drainage architecture of the scapular skin and subcutaneous tissue. Plast Reconstr Surg* 108:656, 2001.)

Between the cutaneous veins and the venae comitantes are thin parallel branches of the cutaneous veins that play clinically important roles. In areas such as the face, where the course of the named vein diverges significantly from the named

source artery (eg, superficial temporal artery and vein), these parallel branches may actually become the venae comitantes to the source artery⁴¹ and to the small arteries that supply the cutaneous vein (eg, lesser saphenous and cephalic).^{39,42} The small arteries correspond to the Nakajima type II and are the source of venocutaneous perforators to the skin. They are an important bypass to the unidirectional valves of the cutaneous veins and permit retrograde flow in distally based flaps.⁴²

Pinal and Taylor⁴³ described macrovenous and microvenous systems that bypass the valves of the venae comitantes and permit reversal of flow. Multiple venous anastomotic connections adequately drain most dermal regions via either the cutaneous vein or the venae comitantes of the source artery.

FLAP CLASSIFICATION

Flap classifications are multiple and vary according to the organizing principle. Classification schemes have historically been very confusing because they were based on an incomplete understanding of flap vascularity. As our knowledge of the vascular anatomy of skin, subcutaneous tissue, and muscle increased, new flap types were developed and classifications were proposed that were frequently incongruent with previous systems and with one another. Flaps used to be classified according to their method of movement.⁴⁴ Local skin flaps are still described by this terminology. When distant pedicled flaps became commonplace,³ they were labeled as local or distant depending on their proximity to the donor

and recipient sites. Subsequently flaps were categorized by their tissue composition: muscle, skin, musculocutaneous, fasciocutaneous, septocutaneous, and compound flaps. This classification system can be confusing because different flaps based on different blood supplies but of the same composition can be harvested from the same region.

The intrinsic blood supply of a flap is the most critical determinant of successful transfer and is therefore the most clinically valid method of classification. Numerous anatomic studies of the blood supply to the skin and fascia have contributed to our understanding and led to a simpler classification of cutaneous flaps.^{15,20,25,31-33,35-42,45,46} Unfortunately, the simplified terminology does not extend to all flap types. For example, the fasciocutaneous flap that was originally defined by the presence of deep fascia is now classified according to the pattern of cutaneous vascularity through the fasciocutaneous plexus, and frequently does not include fascia. A fasciocutaneous flap can be any flap based on the fasciocutaneous plexus and composed of any or all of the component layers between the skin and deep fascia.²⁵ The new terminology of perforator and venous flaps also reflects the trend toward vascularity-based nomenclature, and currently a confusing combination of old and new flap terminology coexists.

Daniel and Kerrigan²⁹ grouped flaps into three categories according to their method of movement, composition, and vascularity. In our discussion of specific flaps we have combined the latter two criteria because they overlap with older terminology based on composition terminology. Specific classifications within each of these flap types will also be discussed.

Method of Movement

Skin flaps can be grouped according to the technique used to transfer the tissue and the distance between the donor and recipient sites. Local skin flaps are used to close defects adjacent to the donor site, and are in turn classified based on their method of movement into flaps that advance from the base in the same direction as

the long axis of the flap (V-Y, Y-V, single-pedicle, and bipedicle flaps) and flaps that pivot on a point (rotation, transposition, and interpolation flaps). Distant flaps use donor tissue from sites that are not adjacent to the recipient bed, and can be grouped into direct flaps, tube flaps, and free flaps.^{29,47,48}

Advancement flaps are slid directly forward into a defect simply by stretching the skin, without any rotation or lateral movement.⁴⁷ The simplest example of this type of movement is direct wound closure. Variations are the single- and double-pedicle advancement, V-Y advancement (Fig 10), and its opposite, the Y-V advancement flap. Suzuki and colleagues⁴⁹ propose a variation of the traditional V-Y-plasty in which the Burow's triangles are advanced rather than excised.

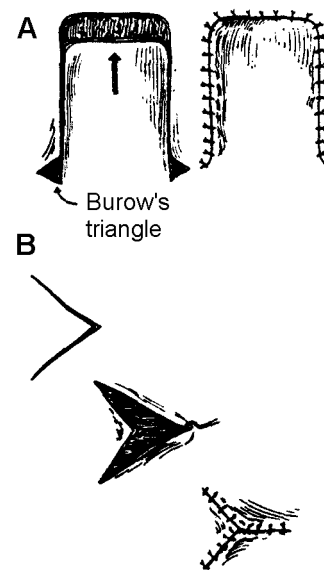


Fig 10. A, rectangular advancement flap. B, V-Y advancement flap. (Reprinted with permission from Smith JW, Aston SJ (eds), *Grabb and Smith's Plastic Surgery*, 4th ed. Boston, Little Brown, 1991.)

Rotation flaps are semicircular in design and rotate about a pivot point into the defect to be closed (Fig 11). The donor site can be closed by a skin graft or by direct suture of the wound. To facilitate rotation of the flap along its arc, the base can be back-cut at the pivot point or a triangle of skin (Burow's triangle) can be removed external to the pivot point.

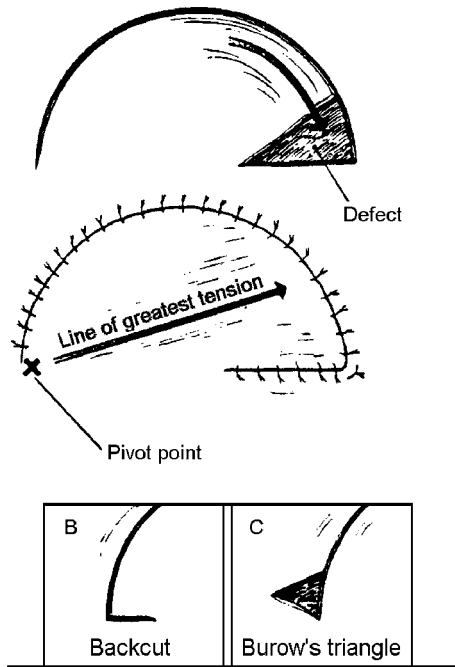


Fig 11. Rotation flap. (Reprinted with permission from Smith JW, Aston SJ (eds), *Grabb and Smith's Plastic Surgery*, 4th ed. Boston, Little Brown, 1991.)

A *transposition flap* is a (usually rectangular) flap that is rotated (laterally) about a pivot point into an immediately adjacent defect. Because the effective length of the flap becomes shorter the farther the flap is rotated, the flap must be designed longer than the defect to be covered, otherwise a back-cut may be necessary (Fig 12). The flap donor site can be closed by skin graft, direct suture, or secondary flap—eg, bilobed flap (Fig 13).

A variation of the transposition flap is the *Z-plasty* technique in which two triangular flaps are reversed and rotated 90°. The three limbs of the Z must be of equal length and the lateral limb to central limb angles should be equivalent. The gain in length is related to the angle between the central and lateral limbs (Table 1).⁵⁰ The 60° Z-plasty is most effective because it lengthens the central limb without placing too much tension laterally (Fig 14).

Furnas and Fischer⁵¹ estimate that the actual gain in central limb length is 55%–84% of predicted and varies with local skin tension. Seyhan⁵² explores the geometry of Z-plasties and reminds us that a single large Z-plasty is more effective than multiple smaller ones for lengthening the skin in a desired location.

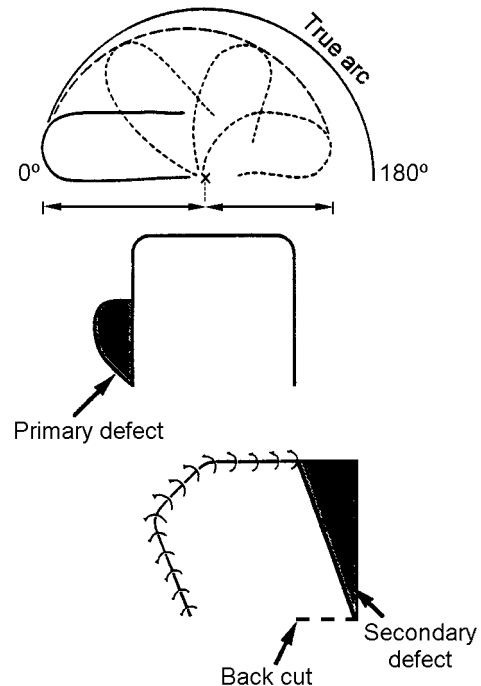


Fig 12. Transposition flap. The flap becomes shorter as it pivots and should be designed larger than the defect. A back-cut may be needed to ease tension at the base. (Reprinted with permission from Smith JW, Aston SJ (eds), *Grabb and Smith's Plastic Surgery*, 4th ed. Boston, Little Brown, 1991; and Lamberty BGH, Healy C: *Flaps: physiology, principles of design, and pitfalls*. In: Cohen M (ed), *Mastery of Plastic and Reconstructive Surgery*. Boston, Little Brown, 1994.)

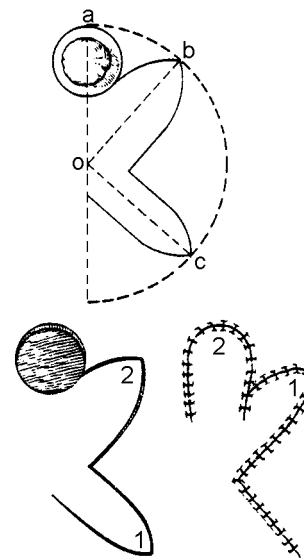


Fig 13. The bilobed flap. (Reprinted with permission from Jackson IT: *Local Flaps in Head and Neck Reconstruction*. St Louis, Mosby, 1985.)

TABLE 1
Theoretical gain in length of the central limb with various angles in Z-plasty.

Angle of Each Lateral Limb (in Degrees) of Z-Plasty	Theoretical Gain in Length of Central Limb (%)
30	25
45	50
60	75
75	100
90	120

(Reprinted with permission from Rohrich RJ, Zbar RIS: A simplified algorithm for the use of Z-plasty. *Plast Reconstr Surg* 103:1513, 1999.)

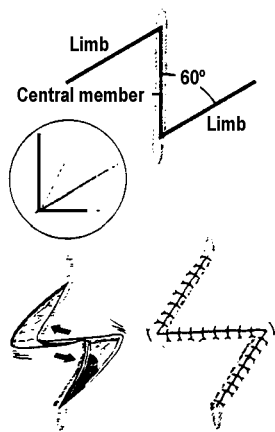


Fig 14. Z-plasty. (Reprinted with permission from Smith JW, Aston SJ (eds), *Grabb and Smith's Plastic Surgery*, 4th ed. Boston, Little Brown, 1991.)

The rhomboid (Limberg) flap is another transposition flap characterized by its geometric pattern. The longitudinal axis of the rhomboid excision parallels the line of minimal skin tension. Four different rhomboid flaps can be designed when 60° angles are used (Fig 15). This concept can be expanded to create a double or even a triple rhomboid flap; the donor sites of the flap are closed by direct suture.⁵³

The Dufourmentel flap is similar to the rhomboid flap except that it can be drawn with angles of up to 90°.

Keser and colleagues⁵⁴ described a curvilinear modification of the classical transposition flap. Their variant has double opposing semicircular flaps and is used to close circular defects (Fig 16).

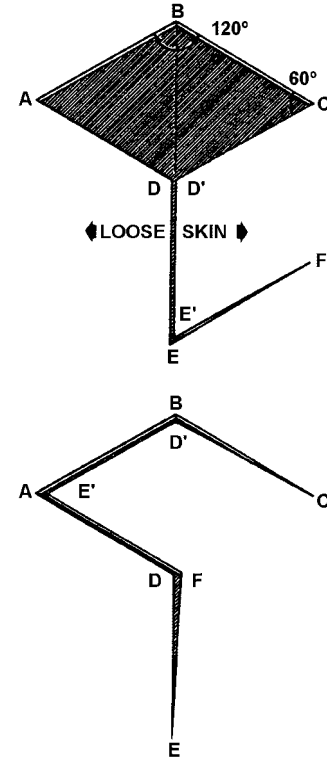


Fig 15. The rhomboid (Limberg) flap. (Reprinted with permission from Smith JW, Aston SJ (eds), *Grabb and Smith's Plastic Surgery*, 4th ed. Boston, Little Brown, 1991.)

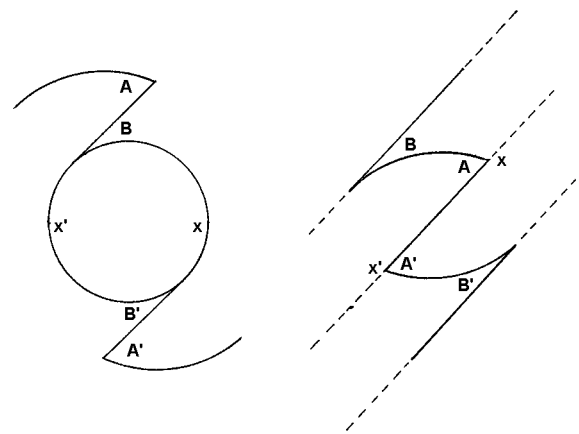


Fig 16. Double opposing semicircular flaps. After elevating the flaps and undermining the adjacent tissue, flap A is transposed with flap B and flap A' with flap B'. The angles of A and A' flaps are sutured to the marks at x and x', and B and B' flaps to D and D', respectively. (Reprinted with permission from Keser A, Sensoz O, Mengi AS: Double opposing semicircular flap: a modification of opposing Z-plasty for closing circular defects. *Plast Reconstr Surg* 102:1001, 1998.)

Interpolation flaps rotate on a pivot point into a defect that is near but not adjacent to the donor site, so that the flap pedicle must pass over or under the intervening tissue. Examples of interpolation flaps are the deltopectoral (Bakamjian) flap, island flaps such as the Littler neurovascular digital pulp flap (Fig 17), and subcutaneous-pedicle flaps.

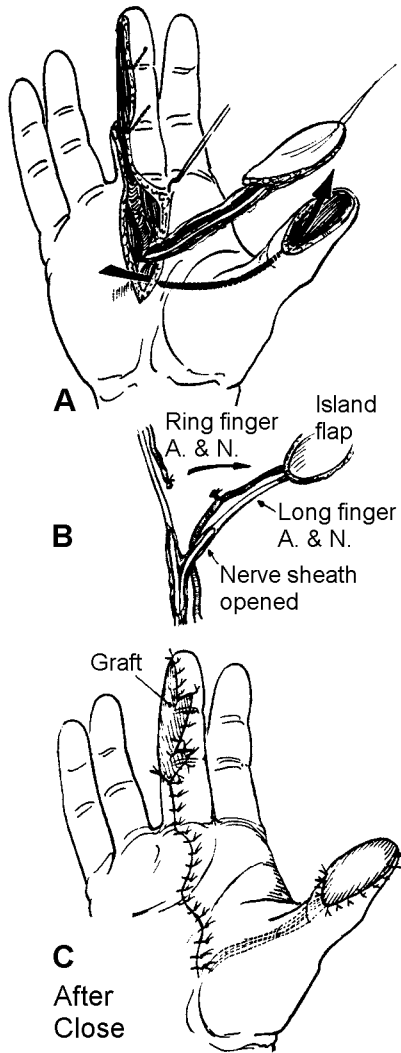


Fig 17. The neurovascular island flap (Littler). (Reprinted with permission from Daniel RK, Kerrigan CL: *Principles and physiology of skin flap surgery*. In: McCarthy JG (ed), *Plastic Surgery*. Philadelphia, Saunders, 1990. Vol 1, Ch 9, p 305.)

Distant flaps imply that the donor and recipient sites are not in close proximity to each other. Examples include direct flaps (not to be confused with direct cutaneous) such as the thenar, cross-leg, and groin flaps. When the two sites cannot be approximated, tube flaps⁵⁵ (Fig 18) or microvascular free tissue transfers are indicated.

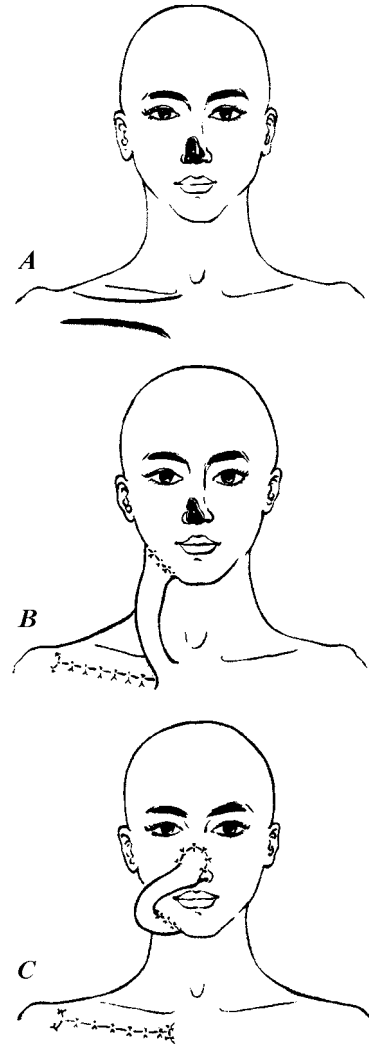


Fig 18. The clavicular tubed flap. (Reprinted with permission from Mendelson BC, Masson JK: *Cervical and clavicular tubed skin flaps*. In: Strauch B, Vasconez LO, Hall-Findlay EJ (eds), *Grabb's Encyclopedia of Flaps*. Boston, Little Brown, 1990. Vol 1, Ch 42.)

Free Tissue Transfer

In 1963 Goldwyn and colleagues⁵⁶ reported the first successful free flap transfer when they elevated an island pedicled flap from the groin of dogs and subsequently divided the pedicle and replaced the flap in its original site with microvascular anastomoses. Several reports of free flap reconstruction followed in short order. Clinical microsurgery has experienced a rapid expansion since its beginning in the early 1970s. Success rates of microvascular procedures is well over 90% in most series.⁵⁷ For a detailed overview of microsurgery and free tissue transfer, please refer to the *Selected Readings* issue on this topic.

Tissue Composition and Vascularity

Cutaneous Flaps

McGregor and Morgan⁵⁹ categorized flaps as random or axial. Random flaps are based on the subdermal plexus which is supplied by direct cutaneous, musculocutaneous, or fasciocutaneous vessels.¹ Random flaps are traditionally limited to 3:1 length-to-width ratios, and may require multiple delays to be transferred to a distant site. Milton⁶⁰ challenged the relevance of length-to-width ratios and accurately argued that the survival of a skin flap depends entirely on its means of vascularization.

Axial pattern flaps contain a specific direct cutaneous artery within the longitudinal axis of the flap. An island flap is an axial pattern flap that is raised on a pedicle devoid of skin to facilitate distant transfer.⁶¹ Since the vascular anatomy of fasciocutaneous perforators was detailed, a classification system that can be applied to all cutaneous flaps has been devised.^{35,62}

Cormack and Lamberty^{1,63} state that skin flaps can be classified as direct cutaneous, musculocutaneous, or fasciocutaneous according to their anatomic system of vascularization, not their tissue components. All skin flaps are based on the fasciocutaneous plexus, which includes the interconnected component parts of the subfascial, intrafascial, and suprafacial vascular plexuses encompassing the dermal, subdermal, superficial, and deep adipofascial layers.^{35,36,64} The fasciocutaneous plexus is supplied from perforating vessels that penetrate the deep fascia either directly, through muscle, or between muscles. Hallock²⁵ defines a perforator as any vessel that enters the suprafascial plane through a fenestration in the deep fascia, regardless of origin. Flaps based on isolated perforator(s) are defined as perforator flaps.^{65,66}

Nakajima³⁵ classified skin flaps into five types according to their vascularization: cutaneous, fasciocutaneous, adipofascial, septocutaneous, and musculocutaneous (Table 2). All skin flaps are supplied by perforating vessels to the fasciocutaneous plexus. Fasciocutaneous flaps were further grouped into six types based on the six patterns of deep fascial perforators (see Fig 6). Nakajima's definition of a direct cutaneous perforator is equivalent to the axial vessel of McGregor and Morgan.⁵⁹ Mathes and Nahai⁶⁷ defined fasciocutaneous flaps as those supplied by a direct cutaneous pedicle, septo-

cutaneous pedicle, or musculocutaneous pedicle. Nakajima³⁶ analyzed and classified the 3-dimensional structure of the skin and adipofascial tissue into six types and described their corresponding flap applications in a study that is becoming increasingly relevant from a clinical standpoint.

Taylor and Palmer²⁰ state that cutaneous arteries contributing to an angiosome can arise *directly* from the underlying source vessel to provide the primary cutaneous supply, or *indirectly* from the branches of the source artery to deeper structures.^{20,30} Hallock²⁵ differentiates direct and indirect perforators based on the structures that they traverse prior to piercing the deep fascia. *Direct perforators* pierce the deep fascia without having traversed any deeper structures. *Indirect perforators* pass through deeper tissues, usually muscle or septum, before entering the deep fascia. Hallock²⁵ applied this concept to the classification of deep fascial perforators proposed by Nakajima³⁵ whereby all cutaneous flaps could be designated as either *direct* or *indirect* perforator flaps (Fig 19).

Perforator Flaps

By the early 1980s, microsurgical techniques had been successfully integrated into the practice of reconstructive surgery and there was a quest to discover new donor flaps that would be reliable, thin, technically easy to raise and transfer, and that would produce minimal donor site morbidity. Perforator flaps and the less-successful arterialized venous flaps evolved from these efforts.^{23,68} In China and Japan the first perforator flaps were developed for head and neck reconstruction and burn scar contractures. In 1984 Song et al⁵ reported the "free thigh flap", which included a description of the anterolateral thigh flap, the andromeda thigh flap, and the posterior thigh flap. Each flap was designed over a septocutaneous perforator of the source vessel, which was dissected retrograde. In 1989 Koshima and Soeda⁶ reported the successful transfer of an inferior epigastric artery skin flap based on a rectus abdominis perforator to a groin wound (island) and to the floor of mouth. Allen and Treece⁷ and Blondeel⁸ reported the ultimate muscle-sparing TRAM flap when they published their successful series of breast reconstructions with the deep inferior epigastric perforator flap. Gluteal artery perforator flaps were first raised as pedicled flaps by

TABLE 2
Classification of Skin Flaps

	Vascular System (compartment)	Vascular Input to Fasciocutaneous Plexus	Vascular Pattern	Clinical Form
1 Cutaneous flap	D		Random	Conventional pedicled
2 Fasciocutaneous flap				
Type I	D, F	Direct cutaneous vessels (type A)	Axial	Free, island
Type II	D, F	Direct septocutaneous vessels (type B)	Axial	Free, island
Type III	D, F	Direct cutaneous branch of muscular vessels (type C)	Axial	Free, island
Type IV	D, F	Perforating cutaneous branch of muscular vessels (type D)	Axial	Free, island
Type V	D, F	Septocutaneous perforator (type E)	Random	Conventional or subcutaneous pedicled
Type VI	D, F	Musculocutaneous perforator (type F)	Random	Conventional or subcutaneous pedicled
3 Adipofascial flap	F	Same as above	Same as above	Same as above
4 Septocutaneous flap	D, F, S	Septocutaneous perforator (type E), direct septocutaneous vessels (type B)	Axial	Free, island
5 Musculocutaneous flap	D, F, M	Musculocutaneous perforator (type F), perforating cutaneous branch of muscular vessels (type D)	Axial	Free, island

(Reprinted with permission from Nakajima H, Fujino T, Adachi S: A new concept of vascular supply to the skin and classification of skin flaps according to their vascularization. *Ann Plast Surg* 16:1, 1986.)

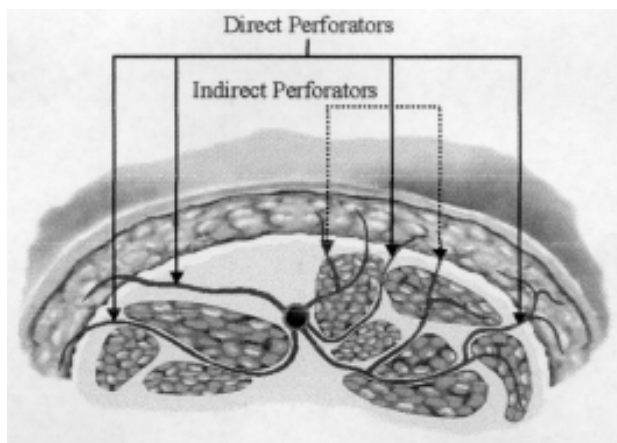


Fig 19. Modification of Nakajima’s pattern of deep fascia perforators. (Reprinted with permission from Hallock GG: *Direct and indirect perforator flaps: the history and the controversy. Plast Reconstr Surg* 111:855, 2003.)

Koshima⁶⁹ for the repair of sacral wounds, and later by Allen and Tucker¹⁰ as free flaps for breast reconstruction. Angrigiani et al⁹ developed the “latissi-

mus dorsi musculocutaneous flap without the muscle”, a flap of skin and subcutaneous tissue based on a thoracodorsal artery perforator.

The introduction of perforator flaps ushered in an era of sophistication and refinement in reconstructive microsurgery. The emphasis shifted from trying to ensure free flap survival to preserving muscle function, producing minimal donor site morbidity, and designing flaps that are highly versatile and can be tailored to the specific defect. Our understanding of cutaneous vascularity and perforator anatomy has grown tremendously in the past 10 years. Perforator flaps are typically composed of skin and subcutaneous tissue supplied by a deep fascial perforating vessel. Perforator flaps allow the surgeon to reconstruct body parts with the same tissues that are most frequently missing: skin and subcutaneous fat. Potential flap donor sites are numerous, and many also have the capacity to incorporate muscle, fat, and bone into the flap design.

The Fifth (Gent, Belgium, 2001) and Sixth International Course on Perforator Flaps (Taipei, Taiwan, 2002) were held in response to the rapid evolution of perforator flaps and confusion regarding their terminology.⁶⁵ The consensus definition of a perforator flap in 2002 was “a flap consisting of skin or subcutaneous fat. The vessels that supply blood to the flap are isolated perforator(s). These perforators may pass from their source vessel origin either through or in between the deep tissues (mostly muscle).”⁶⁵ Three different kinds of perforator vessels were recognized: 1) indirect muscle perforators; 2) indirect septal perforators; and 3) direct cutaneous perforators⁶⁵ (Fig 20). The indirect muscle and septal perforators give rise to musculocutaneous and septocutaneous perforator flaps, respectively.

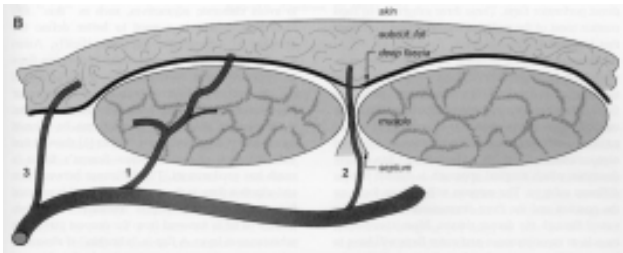


Fig 20. Simplified definitions emerging from the 2002 Sixth International Course on Perforator Flaps. (1) Indirect muscle or musculocutaneous perforators traverse muscle to pierce the outer layer of the deep fascia and supply the skin. (2) Indirect septal or septocutaneous perforators traverse through septum and supply the skin after piercing the outer layer of the deep fascia. (3) Direct perforators penetrate the deep fascia only. (Reprinted with permission from Blondeel PN, Van Landuyt K, Hamdi M, Monstrey SJ: *Perforator flap terminology: update 2002. Clin Plast Surg* 30:343, 2003.)

Wei²¹ and other purists^{70,71} continue to argue that a “true perforator” should only refer to a muscular perforator, which requires intramuscular dissection and which should therefore have a distinct identity from the more easily dissected septal perforator.^{25,65,66} Flaps such as the groin flap that were previously classified as either axial, arterial, or cutaneous are now more accurately described as direct cutaneous perforator flaps.⁷²

To lessen confusion over specific perforator flap nomenclature, a consensus was reached at the meeting to name each perforator flap after the nutrient vessel(s) and not the underlying muscle.⁶⁵ In areas where multiple perforator flaps can be raised from

a single vessel, the flap should be named after its anatomic region or muscle.⁶⁵ For example, flaps based on the lateral circumflex femoral vessels are named the anterolateral thigh flap, tensor fasciae latae perforator flap, and so on, according to location or underlying musculature.

Perforator flaps have the following advantages:⁷³

- preserve muscle function
- produce minimal donor site morbidity
- reduce postoperative recovery time and pain medication requirements
- can be designed of varying sizes and thicknesses to improve the esthetic result

Many studies comparing the deep inferior epigastric (DIEP) flap and the TRAM flap for breast reconstruction attest to the postoperative advantages of muscle-sparing flap harvest.^{74–80} Perforator flaps owe their versatility to the large cutaneous territories, long pedicles that permit conventional and free transfer, potential for being harvested as compound or sensate flaps, and ability to be thinned to the subdermal plexus.^{14,16,18,19,71,81–83} These characteristics make perforator flaps ideal soft-tissue units for reconstruction in areas that require thin, pliable tissue, such as the head and neck and the lower extremity.^{69,71,82–87}

The disadvantages of perforator flaps are 1) the time-consuming, meticulous dissection of the pedicle; 2) variation in perforator anatomy, size, and location; and 3) a higher risk of fat necrosis compared with musculocutaneous flaps.^{80,82,83,88–93}

Theoretically, a perforator flap could be designed in each of the cutaneous territories of the 374 perforators >0.5 mm in diameter identified by Taylor and Palmer.^{20,94} The most commonly used perforator flaps are the deep inferior epigastric (DIEP) flap, the anterolateral thigh (ALTP) flap, the superior gluteal artery (SGAP) flap, and the thoracodorsal artery (TAP) flap. Many other flaps have been described but have not yet gained the popularity of the DIEP and the ALTP flaps. To qualify as a potential donor source of perforator flap, a site must have a reliable blood supply, one or more large (>0.5 mm diam) perforators, pedicles of sufficient length, and (preferably) be able to be closed primarily after flap harvest.

The development of supermicrosurgical techniques has facilitated the harvest of flaps based on smaller and shorter perforators, such as the paraum-

bilical perforator flap.^{11,18} The “free-style free flap” is the ultimate application of the angiosome theory and supermicrosurgical techniques.^{21–25} A cutaneous perforator is identified by Doppler probe and a flap is designed on the skin territory. The perforator is used for the anastomosis, which is performed with supermicrosurgical techniques that eliminate the need for tedious dissection of the source vessel. The reader is encouraged to review the references on perforator flaps independently because an in-depth description of specific flaps is beyond the scope of this text.

Fasciocutaneous Flaps

In 1981 Ponten⁹⁵ described a novel way to raise a skin flap based on the vascular plexus of the deep fascia. Although Ponten made the initial clinical observations, the investigations of the anatomical vascular basis for the success of these “superflaps” was subsequently accomplished by Haertsch⁹⁶ in 1981 and Barclay et al⁹⁷ in 1982. Tolhurst and colleagues^{98,99} confirmed the usefulness of the fasciocutaneous flap and expanded the concept to encompass reconstruction in other parts of the body. Early investigations into the blood supply of the fascia^{1,63,99–103} reported that the fasciocutaneous system consists of perforating vessels that arise from regional arteries and pass along the fibrous septa between muscle bellies or muscle compartments. This vascular plexus is localized to the level of the deep fascia, which in turn gives off branches to the skin.

On the basis of anatomic studies, in 1984 Cormack and Lamberty^{63,100} classified fasciocutaneous flaps according to their vascular patterns (Fig 21).

Type A is a pedicled flap supplied by *multiple* fasciocutaneous perforators at the base of the flap and oriented with the long axis of the flap in the predominant direction of the arterial plexus at the level of the deep fascia. The flap can be proximally or distally based and the skin can be removed to create an island flap. Example: Ponten’s flap.

Type B is based on a *single* fasciocutaneous perforator of moderate size which is consistent in both its presence and its location. It may be used as

either a pedicled or free flap. Example: medial arm flap.

Type B modified is still fed by a *single* perforator but differs in that the perforator is *removed in continuity with the major vessel* from which it arises. It is intended for use as a free flap.

Type C flap supports its skin by *multiple* small perforators along its length in a ladder type configuration. These perforators reach it from a deep artery by passing along a fascial septum between muscles. Its main use is as a free flap. Example: radial forearm flap.

Type D consists of an *osteomusculofasciocutaneous* free tissue transfer.

The investigation of the fascial vascular anatomy to develop flap classification systems contributed greatly to our understanding of perforator and cutaneous blood supply. Eventually it became evident that inclusion of the deep fascia was not necessary for the survival of fasciocutaneous flaps,^{20,98} although some authors advocated its preservation for protection of the fascial plexus.¹⁰⁴ Nakajima³⁵ described the fasciocutaneous plexus as a vascular network that extended from below the deep fascia to the dermis and was perfused by deep fascial perforating vessels. Any flap based on this vascular network regardless of its tissue components is a fasciocutaneous flap.²⁵ Flaps that were previously considered fasciocutaneous and that are based on isolated perforating vessels can now be accurately classified as direct or indirect perforator flaps.^{25,35,36,65,72}

In 1992 Masquelet¹⁰⁵ described the concept of a neuroskin flap based on the arteries accompanying cutaneous nerves. Nakajima and colleagues¹⁰⁶ described the neurocutaneous and venocutaneous vascular systems and three types of pedicled fasciocutaneous flap in the extremities: venoadipofascial (VAF), neuroadipofascial (NAF), and veno-neuroadipofascial (V-NAF). These flaps are all based on type II vessels, ie, neurocutaneous and venocutaneous perforators running long in the deep adipofascial layer of the skin. The flaps are raised on a pedicle of adipofascial tissue and designed of appropriate width to include the relevant vascular system. Nakajima¹⁰⁷ reported 23 successful cases of lower extremity reconstruction with VAF and V-

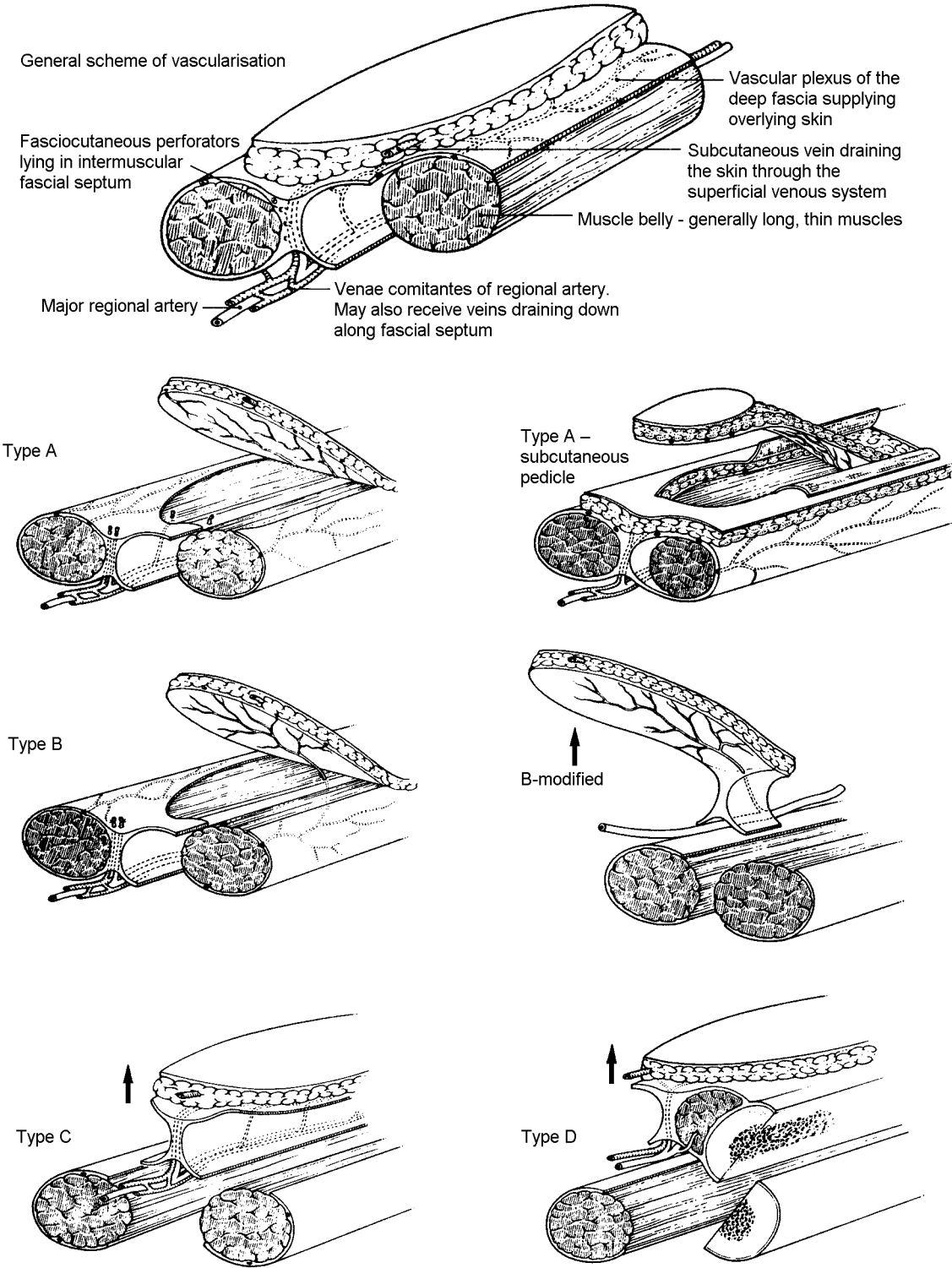


Fig 21. A classification of fasciocutaneous flaps. (Reprinted with permission from Cormack GC, Lamberty BGH: *The Arterial Anatomy of Skin Flaps*. Edinburgh, Churchill Livingstone, 1986.)

NAF flaps based on the lesser saphenous vein and sural nerve. Four distally based and four proximally based types of flap are identified (Fig 22). The lesser saphenous-sural V-NAF flap includes the nerve, the vein, and their respective vascular systems, and was recommended as the most reliable flap choice.

Imanishi⁴² evaluated the venous drainage of the distally based lesser saphenous-sural V-NAF pedicled fasciocutaneous flap in cadavers. He identified small, long veins along the course of the lesser saphenous vein that intermittently anastomosed with the larger vein, and proposed that the small veins bypass the valves in the lesser saphenous vein and are the venae comitantes to the artery that accompanies the larger vein.

Fracalvieri et al¹⁰⁸ reported a series of 18 patients treated with the distally based “superficial sural flap” for reconstruction of soft-tissue defects of the lower leg and foot. The authors reported superficial necrosis in one patient who required grafting and delayed healing in 2 patients. Baumeister and associates¹⁰⁹ published a series of “sural artery flap” reconstructions in 70 patients, 60% of whom had at least one major systemic illness. The complication rate was 59%; flap necrosis occurred in 36%. Risk factors for complications were comorbidity, osteomyelitis, and a tight subcutaneous tunnel.

Cavadas¹¹⁰ transferred large reverse-flow neurocutaneous saphenous island flaps for lower extremity reconstruction in 5 patients. In a follow-up article 6 years later, Cavadas¹¹¹ reports transferring a posterior tibial perforator-saphenous subcutaneous flap in 40 cases. The flap modification was a response to difficult transposition, poor pedicle coverage, and donor site complications with the previous flap technique.

Nakajima⁴⁵ was the first to report the arterial supply to the lesser saphenous vein and the related flap. Chen¹¹² reported a series of 21 patients who had lower extremity reconstruction with the distally based “saphenous venofasciocutaneous flap” (Fig 23).⁴⁶ Distal flap necrosis was treated with skin grafting in 2 patients. Although it can be raised as an innervated flap for coverage of plantar heel wounds, the sural nerve is usually preserved and therefore the donor morbidity is less than that of the neurocutaneous flap.

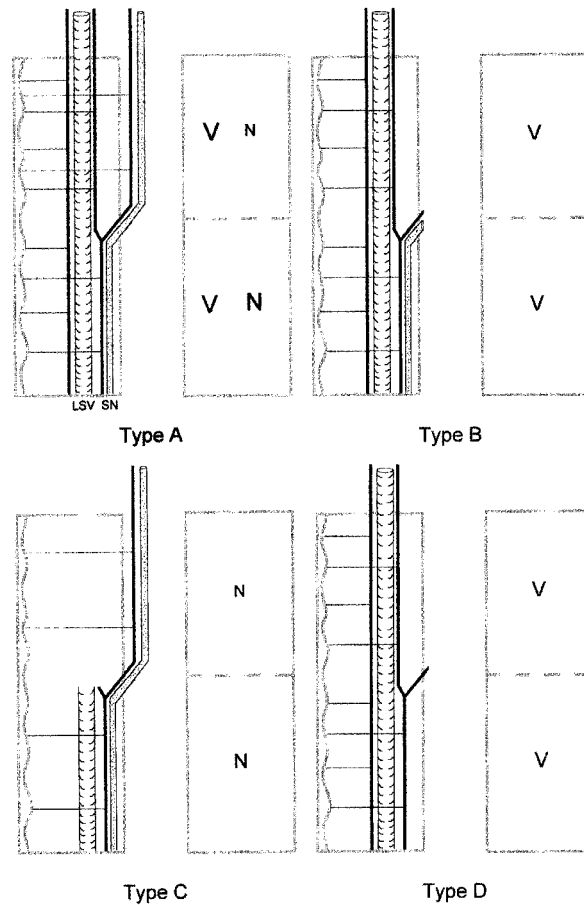


Fig 22. Theoretical flaps with a proximal base. Type A contains both the lesser saphenous vein and sural nerve. Type B is the same as type A except the sural nerve has been removed from the upper flap. Type C is the same as type A except the lesser saphenous vein has been removed from the upper flap. Type D is the same as type A except the sural nerve has been removed. To the right of each flap a diagram shows which perforators are responsible for the blood supply of each flap. The small N denotes weak vascularity to the skin. (Reprinted with permission from Nakajima H, Imanishi N, Fukuzumi S, et al: Accompanying arteries of the lesser saphenous vein and sural nerve: anatomic study and its clinical applications. *Plast Reconstr Surg* 103:104, 1999.)

Venous Flaps

The introduction of venous flaps in the 1980s was a result of the quest to develop the ideal free flap: one that was easy, reliable, thin, and not morbid. Nakayama et al¹¹³ and later Jii and colleagues¹¹⁴ and Nichter and Haines¹¹⁵ reported arterializing a flap through a venous pedicle. A venous island flap with an AV fistula was thus cre-

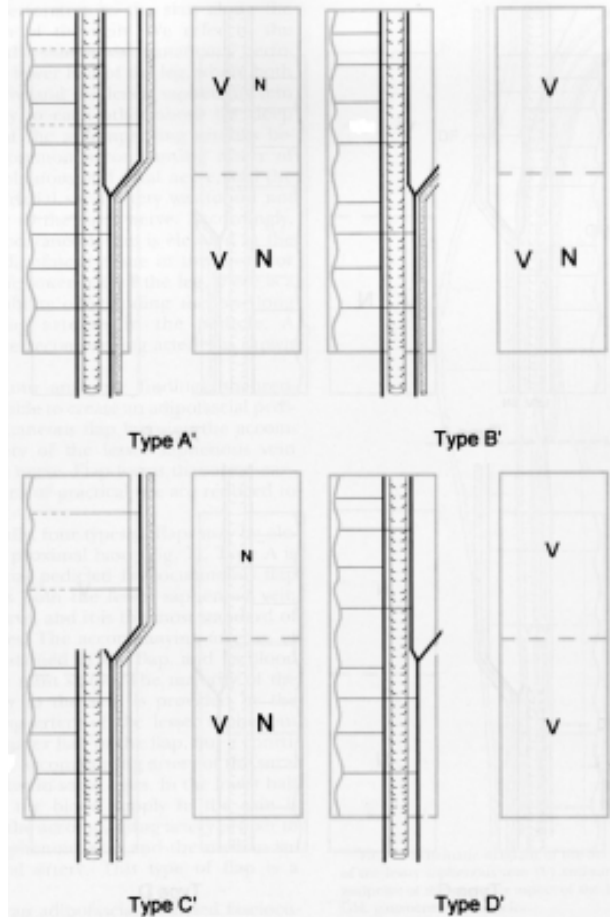


Fig 23. Theoretical flaps with a distal base. Types A', B', C', and D' are reverse flaps of the proximally based flaps. (Reprinted with permission from Nakajima H, Imanishi N, Fukuzumi S, et al: *Accompanying arteries of the lesser saphenous vein and sural nerve: anatomic study and its clinical applications. Plast Reconstr Surg* 103:104, 1999.)

ated and was reported to have up to 95 % flap survival and high patency rates. The survival of these flaps, however, was not consistent. Germann and associates¹¹⁶ showed that although blood flow in pig island flaps was reversed, oxygen consumption remained below baseline, early thrombosis was a common occurrence, and no flap survived longer than 48 hours.

The flow through venous flap in which both the afferent and efferent pedicles are supplied by venous blood was described in 1985 by Baek et al,¹¹⁷ who used the saphenous vein of a dog. Baek¹¹⁷ proposes a "to-and-fro" oscillating mechanism of flow in the vein, venules, and venous capillaries. Two years later, Chavoin¹¹⁸ applied this in a clinical setting. In 1987 a single-pedicled venous island flap

using the saphenous vein was created in a dog by Thatte and Thatte.¹¹⁹ These single-pedicled island flaps can be further classified into either proximally based or distally based flaps. Amarante and coworkers¹²⁰ concluded that single-pedicled venous flaps cannot survive without flow-through, and Lenoble et al's¹²¹ flow-through venous flaps all died despite blood flow within the venous system.

Thatte and Thatte¹²² classify venous flaps into three groups, review the experimental and clinical studies on venous flaps, and discuss the various theories of flap survival. According to this classification, type I is a unipedicled venous flap, or pure venous flap with a single cephalad vein as the only vascular conduit. Yuan, Shan, and Zhu¹²³ describe two patterns of flow in pure venous flaps: a shaking movement related to heart rate and a pendulum-like movement that is the main contributor to flap perfusion. Also observed was ongoing revascularization, which ultimately supplied the flap and which is essential for flap survival.¹²⁴ Noreldin and others¹²⁵ attributed survival to a perivenous areolar network of vessels arranged longitudinally along the whole length of the pedicle. Shalaby and Saad¹²⁶ identified an arterial network in the perivenous areolar tissue on histological study of the saphenous and cephalic venous island flaps.

Nakajima's⁴⁵ anatomic study and description of the intrinsic and extrinsic venocutaneous vascular system confirmed the presence of perivenous arterial flow of the single-pedicled venous flap. The type I venous flap would be classified by the author as a venocutaneous adipofascial flap.

Thatte and Thatte¹²² type II venous flaps are bipedicled "flow-through" flaps with afferent and efferent veins exhibiting flow from caudal to cephalad. Xiu and Chen¹²⁷ reported that the perivenous areolar tissue is essential for flow-through flap survival and conclude that it is both protective and nourishing. They divide the survival process into an early (up to 72 hours) venous nourishing stage and a secondary (day 4 to 6 weeks) stage of neovascularization characterized by arterial nourishing and vascular reconstruction.

Inada's group¹²⁸ isolated their flaps from the recipient tissue bed and concluded that flow-through venous flaps with only a single vein cannot survive if larger than 1–2 cm. For larger flaps to survive, a dense venous network is essential, which suggests that more than one vein would probably be benefi-

cial.¹²⁹ They surmised that these flaps behave not unlike a graft whose survival depends largely on the surrounding circulation.

Type III venous flaps are arterialized through a proximal arteriovenous anastomosis and drained by distal veins. Lee¹³⁰ reviews the concept of venous flaps and the arterialization of the venous system and illustrates three kinds of arterialized venous flaps (Fig 24). He points out that the circulation of blood in venous flaps is based on speculation, and credits a number of authors for various explanations. Possible patterns of blood flow in the arterialized venous flap range from pure retrograde (from a venous to a venous system), through reverse shunting (from venules to arterioles followed by normal orthograde flow), to pure shunting (where no perfusion of the flap occurs but rather blood flows directly from the afferent to the efferent channels).

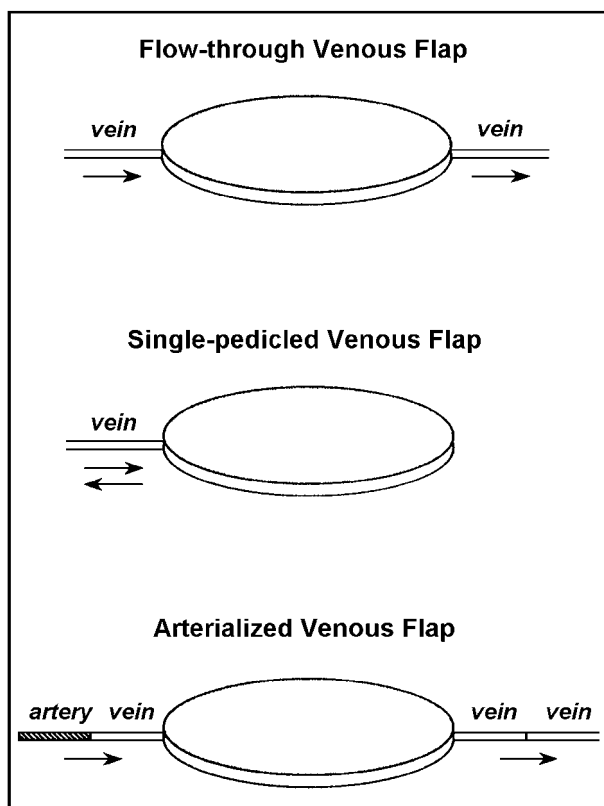


Fig 24. Three types of arterialized venous flaps. (Reprinted with permission from Lee WPA: Discussion of "Arterialized venous flap for treating multiple skin defects of the hand", by G Inoue, K Suzuki. *Plast Reconstr Surg* 91:303, 1993.)

Yilmaz et al¹³¹ describe the four options in hooking up their radial forearm venous flap. These

include orthograde inflow/orthograde outflow, retrograde inflow/retrograde outflow, orthograde inflow/retrograde outflow, and retrograde inflow/orthograde outflow. They chose the fourth system because the valves are rendered incompetent by the high pressure of the arterial inflow. Moshammer et al¹³² reported in an experimental study that the circulation at the periphery of the arterialized venous flap can be enhanced by retrograde arterialization. The authors propose that the resistance to flow from the vein's valves forces blood into the flap's periphery. Krishnan¹³³ confirmed these conclusions and also reported that according to their experimental model, venous flaps arterialized against the valves achieved a larger perfusion area than flaps perfused in the direction of the valves. The largest area of perfusion was seen in bidirectionally perfused flaps.

The mechanism of perfusion of venous flaps is still not completely understood and has been attributed to a number of factors such as plasmatic imbibition, perfusion pressure, sites of arteriovenous anastomosis, perivenous arterial networks, vein-to-vein interconnections and other vascular networks, and the circumvention of venous valves. Several studies have demonstrated improved survival of venous flaps with prearterialization and delay procedures.^{68,134-137} Unfortunately, the survival of venous flaps continues to be inconsistent.

Chavoin et al¹¹⁸ describe a reverse shunt from venules to arterioles followed by orthograde flow from arterioles to capillaries and then to normal venous channels. Imanishi and colleagues¹³⁸ propose the presence of arteriovenous shunts around the efferent vein of their arterialized cephalic venous flaps. They describe the route of flow as being from vein to perivenous network, to perivenous arterial network, to the arterial system, and then back to the venous system and the original vein.

Studies by Chow, Chen, and Gu¹³⁹ noted better survival of true arterial flaps than arterialized venous flaps. The quality of the surviving flap improved with increased perfusion pressure and better oxygenated blood. Ueda et al¹⁴⁰ noted increased survival of flow-through venous flaps when delayed. Using infrared thermography, Wolff et al¹⁴¹ examined three types of venous flaps with regard to their perfusion and long-term results. At 4 months the survival rate for arterialized venous flaps was 92.7%;

for flow-through venous flaps, 62.4%; and for venous island flaps, about 31%. They concluded that arterialized venous flaps are the safest type of venous flaps.

The clinical advantages of venous flaps are minimal donor site morbidity requiring only the sacrifice of a vein and no artery; a long and very thin, anatomically constant pedicle (eg, the saphenous vein); and fast and expedient flap elevation.^{130,132,142–145} The poorly understood physiology and unpredictable survival of venous flaps makes the clinical application of these flaps controversial. The main disadvantages of venous flaps are limited size of the flap; variable rate of tissue necrosis; delayed healing; venous congestion; susceptibility to infection; potential (though unlikely) hemodynamic complications of a surgically created AV shunt; restricted location of donor sites to maximize the venous plexus; and frequent need for skin graft coverage of donor sites.^{68,129,132,143–145} Clinical trials of prearterialization and delay procedures report improved flap survival^{68,137} with these measures.

Nishi and colleagues¹⁴⁶ and Inoue and Suzuki¹⁴² report using arterialized venous skin flaps for the treatment of skin defects in the hand. Noordhoff's group¹⁴⁷ applied venous flaps in 28 patients and categorized their operations into four types. They note the advantages and disadvantages of each type and conclude that venous flaps are not intended to replace more conventional flaps.

Chia and colleagues¹⁴⁸ describe the successful retransplantation of a venous-network-pattern skin flap using a 12 x 12 cm skin paddle from the medial aspect of the right thigh transferred to the distal lower extremity. Galumbeck and Freeman¹⁴⁴ performed human anatomical studies the results of which suggested that only the venous tributaries of the flap receive blood. The authors applied an arterialized saphenous vein fasciocutaneous graft to cover tissue defects on both the upper and lower extremities.

Stewart and Puckett¹⁴⁹ review the safety of reverse venous flow in free flap transfers, specifically the radial forearm flap. Koshima et al¹⁴³ used the saphenous vein and incorporated an osseous component. They were able to increase the functional size of the flap to 7 x 11 cm from the 3 x 8 cm reported by Nakashima.¹⁵⁰ Yilmaz and colleagues¹⁵¹ reported successful free flap transfer of an arterial-

ized venous flap measuring 8 x 12 cm from the forearm to the face.

Klein et al¹⁵² reported 4 cases of partial flap necrosis and 8 cases of total flap necrosis in a series of 29 free arterialized forearm flaps for intraoral reconstruction.

Kovacs¹⁵³ compared two types of arterialized forearm flaps for oral reconstruction. Type I was a single vein arterialized flow-through flap. Type II was an arterialized flap with two parallel veins on the proximal flap. The smaller vein was for arterial inflow and the larger for venous outflow, theoretically to avoid bypassing the flap tissue. Four of the 5 type I flaps showed total or subtotal success and one was lost. Of the 5 type II flaps, 3 were lost, one was a partial failure, and the other one was a total success.

De Lorenzi and colleagues¹⁴⁵ reported 40 cases of digital soft-tissue reconstruction with arterialized venous free flaps. Postoperative congestion was present in all flaps and resolved within 14 days. There was total flap survival in 57.5%, 17.5% had superficial epidermolysis, 17.5% had full-thickness necrosis that required grafting, and 7.5% had total flap necrosis.

Cho et al⁶⁸ reported a clinical series of 13 delayed arterialized venous flaps. The surviving surface of the flap was 100% in 10 patients, 70% in one patient, 50% in one patient, and 0% (total necrosis) in one patient.

Wungcharoen and others¹³⁷ reported the repair of extremity wounds with a prearterialized venous flap in 8 patients. Arteriovenous shunts were created at the donor site 2 weeks before flap harvest. Flap survival was reported to be 93%–100% of the surface area.

Muscle and Musculocutaneous Flaps

The initial work describing the principles, operative procedures, and clinical applications of muscle flaps was done by Ger¹⁵⁴ in the late 1960s. In 1977 Ger¹⁵⁵ reported successful closure of open wounds in 43 cases. Musculocutaneous flaps are composites of skin, subcutaneous tissue, and underlying muscle and fascia supplied by a dominant vascular pedicle. Tansini¹⁵⁶ was the first to make use of musculocutaneous flaps in 1906 when he reconstructed a breast with a combination of skin and latissimus dorsi muscle raised as one unit. For the

next 50 years no one took notice of this event until Owens¹⁵⁷ in 1955 reported the repair of massive facial defects with the sternocleidomastoid flap, a compound flap from the neck.

The idea that flat muscles (eg, pectoralis and latissimus muscles) could “carry” their overlying skin as composite flaps came independently to Hueston¹⁵⁸ and DesPrez.¹⁵⁹ Orticochea^{160,161} subsequently applied this concept clinically, using the gracilis musculocutaneous unit in penile reconstruction and to repair an ankle defect.

In 1977 McCraw, Dibbell, and Carraway^{162,163} described the vascular territories of several new musculocutaneous units and defined flap dimensions and useful arcs of rotation. The authors emphasized the concept of a dominant vascular pedicle that supplies blood to a muscle and its overlying skin territory through perforating vessels. Although some details of the geometry, reliability, and application of specific flaps were subsequently found to be inaccurate, their papers are still considered to be classics in the history of reconstructive plastic surgery. In later articles McCraw^{164,165} traced the evolution of musculocutaneous flaps, cited sources of original descriptions of yet more such flaps, and reviewed the basic principles of musculocutaneous flap anatomy and physiology.

The primary advantages of muscle flaps are the potential to ablate dead space with vascularized tissue and an increased resistance to infection.¹⁶⁶ By means of radiolabeled microspheres, Gosain et al¹⁶⁷ noted a marked increase in blood flow to all levels of tissue in both musculocutaneous and fasciocutaneous flaps after elevation. Blood flow was also similar between equivalent tissue layers. Musculocutaneous flaps showed a rapid rise in blood flow that leveled by 24 hours. In contrast, fasciocutaneous flaps showed a gradual but steady rise in flow. The greatest decrease in bacterial concentration also occurred in the first 24 hours, but was significantly greater in the musculocutaneous wound space (dropping by a factor of 10^4) than in fasciocutaneous flaps, which only decreased by 10^2 . The authors concluded that blood flow is not affected by the presence of bacteria, but musculocutaneous flaps showed better tissue ingrowth into an inoculated wound space than fasciocutaneous flaps.

Calderon, Chang, and Mathes¹⁶⁸ found that fasciocutaneous flaps were less resistant to the effect

of bacterial inoculation and exhibited less collagen deposition than musculocutaneous flaps.

The clinical application of muscle to infected wounds has been successful in osteomyelitis,^{155,169} postthoracotomy mediastinitis,¹⁷⁰ and prosthetic grafts.^{171,172} The benefits of muscle extend to free flaps. Chen,¹⁷³ Hammond,¹⁷⁴ and Perkins¹⁷⁵ successfully treated chronic intrathoracic sepsis with free latissimus and TRAM flaps containing muscle, fat, and skin.

The primary disadvantages of muscle and musculocutaneous flaps are the functional deficit at the donor site and the bulk of the flap. The design of a musculocutaneous flap requires anatomic knowledge of the vascular architecture of the muscle and the distribution of cutaneous perforators that will supply the skin paddle. In 1979 Mathes and Nahai⁶⁷ developed a useful classification of the blood supply to individual muscles. The authors described five types of muscle on the basis of their circulatory patterns (Fig 25 and Table 3):

- Type I — single vascular pedicle—eg, tensor fascia lata
- Type II — dominant pedicle(s) and minor pedicle(s)—eg, gracilis
- Type III — two dominant pedicles—eg, gluteus maximus
- Type IV — segmental vascular pedicles—eg, sartorius
- Type V — single dominant pedicle and secondary segmental pedicles—eg, latissimus dorsi

Compound and Prefabricated Flaps

Flaps can consist of any number of tissues in virtually any combination. Compound flaps are defined as diverse tissue components that are incorporated into an interrelated unit.¹⁷⁶ Composite flaps are a type of compound flap that often incorporate skin, fat, fascia, muscle, and bone based on a solitary vascular pedicle, which allows single-stage reconstruction of complex defects. Specialized flaps can provide sensory and functional muscle to areas requiring special needs.²⁹ Graham and Dellon¹⁷⁷ review specialized flaps in reconstruction of the hand, foot, oropharynx, breast, and genitalia.

Hallock¹⁷⁶ proposed a useful classification of compound flaps based on their vascularization. Compound flaps are defined as diverse tissue compo-

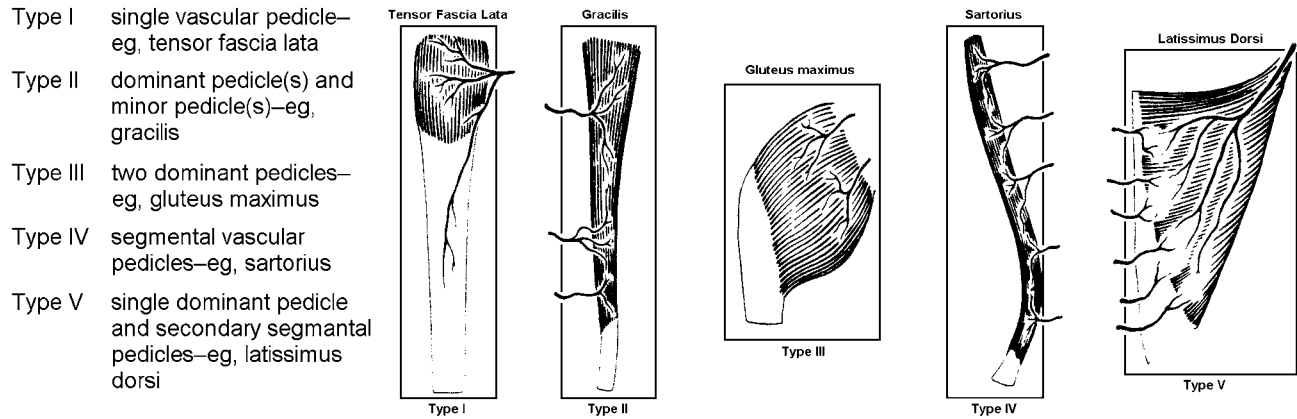


Fig 25. Five patterns of vascular anatomy of muscle. (Reprinted with permission from Mathes SJ, Nahai F: *Classification of the vascular anatomy of muscles: experimental and clinical correlation.* *Plast Reconstr Surg* 67:177, 1981.)

TABLE 3
Examples of Common Muscle Flaps by Type

Type I	<i>One vascular pedicle</i> Gastrocnemius Tensor Fasciae Latae Anconeus Vastus Intermedius		
Type II	<i>One dominant vascular pedicle usually entering close to the origin or insertion of the muscle with additional smaller vascular pedicles entering the muscle belly</i> Abductor digiti minimi Abductor hallucis Biceps femoris Brachioradialis Flexor digitorum brevis Gracilis		
	Peroneus longus Peroneus brevis Platysma Rectus Femoris Semitendinosus Soleus	Sternocleidomastoid Temporalis Trapezius Vastus lateralis	
Type III	<i>Two vascular pedicles, each arising from a separate regional artery (except orbicularis oris)</i> Gluteus maximus Rectus abdominis Serratus anterior Semimembranosus Orbicularis oris		
Type IV	<i>Multiple pedicles of similar size</i> Flexor digitorum longus Extensor hallucis longus Vastus medialis External oblique		
	Extensor digitorum longus Flexor hallucis longus Sartorius Tibialis anterior		
Type V	<i>One dominant vascular pedicle and several smaller secondary segmental vascular pedicles</i> Pectoralis major Latissimus dorsi		

(Reprinted with permission from Cormack GC, Lamberty BGH: **The Arterial Anatomy of Skin Flaps.** Edinburgh, Churchill Livingstone, 1986.)

nents such as bone, skin, fascia, and muscle that incorporated into an interrelated unit. Hallock’s classification places these complex flaps into two groups, those with solitary vascularization and those with combinations of vascularization. The compound flap with solitary vascularization is a composite flap that incorporates multiple tissue compo-

nents dependent on a single vascular supply. Compound flaps of mixed vascularization are further subdivided into Siamese flaps, conjoint flaps, and sequential flaps (Fig 26).

The concept of flap prefabrication (or, more accurately, prelamination¹⁷⁸) was introduced clinically by Orticochea¹⁷⁹ and Washio¹⁸⁰ in 1971. The

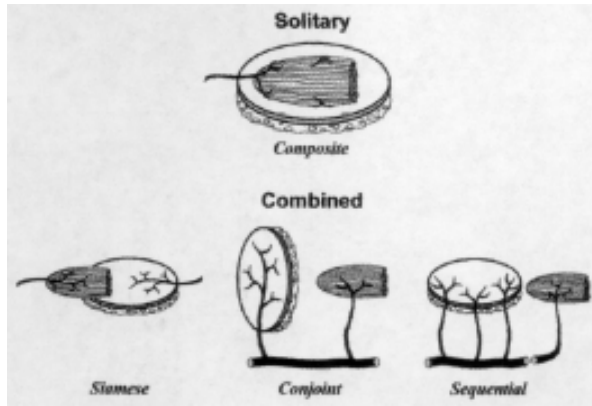


Fig 26. Compound flaps may be subdivided into either solitary or combined types based on their source of vascularization. Combined flaps may be Siamese, conjoint, or sequential. (Reprinted with permission from Hallock GG: *Simplified nomenclature for compound flaps. Plast Reconstr Surg* 105:1465, 2000.)

technique allows for the creation of an “unlimited array of composite free flaps”¹⁸¹ that would otherwise not be available with standard flaps. Combined with skin expansion and a delay procedure, prefabricated flaps are even more versatile.

Khouri, Upton, and Shaw¹⁸² review the principles of flap prefabrication and list specific advantages to their use, including “vascular induction” of specific blocks of tissue which are not naturally perfused by anatomically well-defined axial vessels—ie, prelamination,¹⁷⁸ creation of a larger flap than would otherwise be possible; reduced donor site morbidity; and evaluation of functional status before the transfer of the flap. The authors describe “pre-transfer grafting”, which was used by Barton¹⁸³ to incorporate skin and cartilage in a forehead flap for nasal reconstruction. Others have used it to create a flap incorporating a prefabricated vascularized periosteal graft with good osteogenic capacity.¹⁸⁴ In the future, simple muscle flaps may be transformed into molded vascularized bone grafts through prefabrication.¹⁸²

In another article, Khouri et al¹⁸⁵ address facial reconstruction with an expanded prefabricated flap. The authors describe creation of the prefabricated, induced, expanded (PIE) flap using both a pedicled temporoparietal and free radial forearm fasciocutaneous flaps. The flaps were placed under an expander in the supraclavicular region, which subsequently produced a capsulofasciocutaneous flap after expansion was completed. Although this flap is not intended to replace the forehead for specific

flaps in facial reconstruction, it does provide certain advantages when needed.

Homma et al¹⁸⁶ concluded that expanded muscle-vascularized prefabricated flaps have larger areas of survival than expanded fascia-vascularized flaps. Maitz¹⁸⁷ observed increased survival of delayed prefabricated flaps, while Komuro et al¹⁸⁸ note no significant difference in survival of prefabricated arterialized venous flaps compared with controls. Other authors suggest that because neovascularization is necessary for a successful flap, a delay of at least 4 weeks¹⁸⁹ and even up to 8 weeks¹⁹⁰ should be observed. Maitz, Pribaz, and Hergueter¹⁹¹ note decreased survival of prefabricated flaps subjected to mechanical pressures or restraints (eg, folding or kinking) compared with axial-pattern flaps.

FLAP PHYSIOLOGY

Regulation of Blood Flow to the Skin

Flap physiology begins at the level of the microcirculation. The microcirculation is also where thermoregulation of blood flow—the skin’s primary function—occurs. A number of factors contribute to the regulation of blood flow, such as distention, endothelium-mediated vasoconstriction, neural control, temperature, local injury, and viscosity.¹

Daniel and Kerrigan⁶² find two kinds of regulatory factors of cutaneous blood flow, systemic and local. **Systemic** control is facilitated in one of two ways:

- *Neural* regulation acts through sympathetic adrenergic fibers. Alpha-adrenergic receptors induce vasoconstriction and beta-adrenergic receptors induce vasodilation. Combined, they maintain basal tone of vascular smooth muscle at the arteriovenous anastomoses, arterioles, and arteries. Simultaneously cholinergic fibers initiate bradykinin release, which contributes to vasodilation.
- *Humoral* regulation causes vasoconstriction through the action of epinephrine and norepinephrine on alpha-adrenergic receptors in the cutaneous vessels. Serotonin, thromboxane A₂, and prostaglandin F₂-alpha may also produce vasoconstriction, while bradykinin, histamine, and prostaglandin-E₁ cause direct vasodilation (Fig 27).

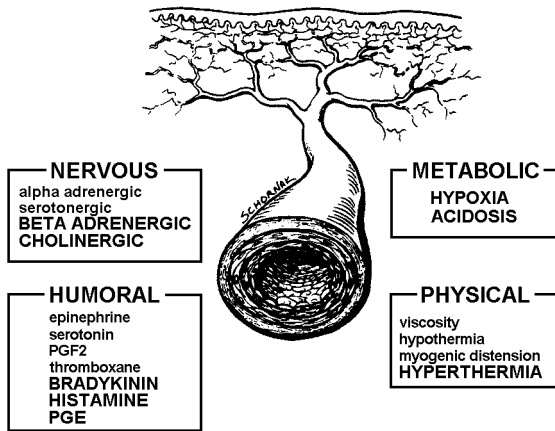


Fig 27. Physiologic factors that regulate the cutaneous microcirculation. (Reprinted with permission from Daniel RK, Kerrigan CL: *Principles and physiology of skin flap surgery*. In: McCarthy JG (ed), *Plastic Surgery*. Philadelphia, Saunders, 1990. Vol 1, Ch 9.)

The effects of local injury to a part of the arterial wall can completely override basal vascular tone and cause spasm even in the absence of sympathetic innervation.¹ For instance, a pin prick elicits a persistent isolated ring contraction locally, and extensive crushing or tearing can induce a widespread and prolonged spasm distantly (Fig 28).

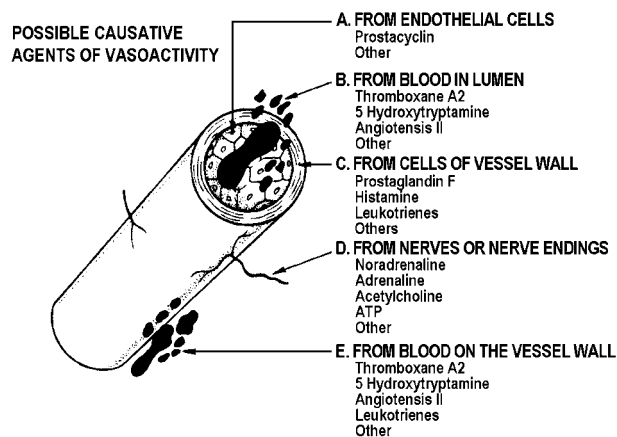


Fig 28. Biochemical agents affecting the circulation. (Reprinted with permission from Cormack GC, Lamberty BGH: *The Arterial Anatomy of Skin Flaps*, 2nd ed. Edinburgh, Churchill Livingstone, 1994.)

Local effects (autoregulation) are mediated by metabolic and physical factors.

- **Metabolic** factors act primarily as vasodilators and include hypercapnea, hypoxia, acidosis, and

hyperkalemia. These factors are not as significant in the skin as in muscle, which has higher metabolic requirements.

- **Physical** factors that influence blood flow include the *myogenic reflex*, which triggers vasoconstriction in response to distention of isolated cutaneous vessels and thereby maintains capillary flow at a constant level independent of arterial pressure. Local hypothermia (which acts directly on the smooth muscle in vessel walls) and increased blood viscosity (hematocrit >45%) may also decrease flow. The effects of hematocrit were questioned by Kim et al,¹⁹² who concluded that normovolemic anemia (hct 19%) had no significant effect on the survival of pedicled musculocutaneous flaps.

These same concepts of blood flow regulation can be applied to muscles. With regard to systemic control, although muscle has a much higher capillary density than skin, arteriovenous shunts are absent. And because the metabolic demand of muscle is greater than that of the skin, autoregulation plays a more important role. Neuronal controls such as exercise and arterial hypotension induce a reflexive vasoconstriction, while hypertension results in vasodilation. Humoral regulation is similar except that epinephrine causes vasodilation, in direct contrast to the vasoconstriction seen in skin. In the scheme of local control, metabolic autoregulation is limited in muscle but does exceed that of skin, and blood flow is minimally changed in response to temperature fluctuations.

Burnstock and Ralevic¹⁹³ review new insights into the local regulation of blood flow. The authors discuss the concept of co-transmission, whereby nerves synthesize, store, and release more than one transmitter, and the importance of the endothelium as a mediator of vasodilation and constriction.

In summary, the mechanisms of blood flow regulation are different in skin and muscle. Myogenic tone is important in muscle regulation but has little effect on cutaneous vessels, whereas sympathetic vasoconstrictors are the predominant means of regulating blood flow to the skin.

Flap Transfer

The elevation of a skin flap results in many profound changes that drastically disrupt the finely bal-

anced equilibrium of homeostasis. Primary changes include the loss of sympathetic innervation and the insult of ischemia.

Hoopes¹⁹⁴ gives a detailed account of the circulatory events that take place in a pedicled flap after its blood supply is partially interrupted during elevation and transfer.

0–24 hrs: reduction in arterial blood supply; progressively decreasing circulatory efficiency for the first 6 hours; plateau at 6–12 hours; increase in circulatory efficiency beginning at 12 hours; marked congestion and edema during the initial 24 hours; marked dilatation of arterioles and capillaries

1–3 days: increasing isotope appearance; improvement in pulse amplitude; little or no improvement in circulation during the initial 48 hours; increase in number and caliber of longitudinal anastomoses; increase in the number of small vessels in the pedicle

3–7 days: progressive increase in circulatory efficiency until it reaches a plateau at about day 7; vascular anastomoses between flap and recipient bed present at 2–3 days, become functionally significant at 5 to 7 days; increase in size and number of functioning vessels; reorientation of vessels along the long axis of the flap

1 week: circulatory function well established between flap and recipient bed; pulsatile blood flow approaches preoperative levels

7–14 days: no further significant increase in vascularization; arterial pattern becomes normal; radioisotope clearance indicates circulatory efficiency surpassing normal values at 10–21 days, returning to normal after 3 weeks

2 weeks: progressive regression of the vascular system; continuous maturation of anastomoses between pedicled flap and recipient site

3 weeks: vascular pattern approximates preoperative state; flap achieves 90% of its final circulation; vital staining occurs simultaneously with recipient limb; fully developed vascular connections between pedicle and recipient site

4 weeks: all vessels decreased in diameter, few remaining newly formed vessels

Most investigators endorse the concept of *venous insufficiency* as the primary cause of necrosis in pedicled flap tissue.¹⁹⁴ As early as 1967, Fujino¹⁹⁵ concluded that reduction in venous outflow probably results in flap necrosis despite the presence of adequate arterial inflow. Tsuzuki and colleagues¹⁹⁶ found that mild venous inadequacy did not affect survival of an experimental flap when the arterial inflow was maintained, but once arterial inflow was impaired, even mild venous inadequacy reduced flap survival.

Angel and coworkers¹⁹⁷ studied secondary ischemia time in a rodent model, and noted that venous obstruction was more deleterious to flap survival than secondary ischemia from complete pedicle obstruction. In contrast, Kerrigan found *inadequate arterial inflow* was the primary cause of flap failure,¹⁹⁸ and proposed a combination of ischemia, inflammation, and sympathectomy to explain the vascular collapse that underlies the failing skin flap.¹⁹⁹ Furthermore, damage to the flap becomes irreversible if adequate nutrient circulation is not provided

May²⁰⁰ studied circulatory changes in free epigastric flaps in rabbits. They noted consistent edema and swelling of the vascular parenchymal cells when free flaps were subjected to a period of ischemia. There was concomitant narrowing of the capillary lumen and trapping of foreign blood elements as well as sludge or thrombus formation in the stagnant blood within the vascular tree of the ischemic tissue. All flaps survived up to 4 hours of ischemia. Between 4 and 8 hours of ischemia, the typical hemodynamic and cellular events occurring in flaps as a response to ischemia were reversible. As the period of ischemia lengthened, the circulatory alterations gradually worsened and vascular obstruction progressed until they became irreversible; this occurs after 12 hours. The point at which it is *not* possible to reestablish nutrient inflow despite reperfusion is known as the *no-reflow* phenomenon. The no-reflow phenomenon is the result of ischemia-induced reperfusion injury and precedes flap death.

The metabolic effects of ischemia during flap elevation are many. With inadequate tissue oxygenation there is a change from aerobic to anaerobic metabolism, resulting in higher levels of superoxide radicals. Glucose consumption and lactate production both increase, with concomitant deple-

tion of glycogen. The metabolic derangements of tissue ischemia also affect physical properties of blood such as viscosity and clotting. Direct cytotoxic injury results from the accumulation of oxygen-derived free radicals during flap ischemia.

Im et al²⁰¹ in 1985 and later Manson and colleagues^{202,203} noted increased production of toxic superoxide radicals during anaerobic metabolism. The authors suggested a role for oxygen-derived free radicals (ODFR) as mediators of tissue necrosis in the ischemic transition zone between the proximal, viable portion of a skin flap and its distal, non-viable segment. With renewed flow comes an abundant supply of calcium ions and a release of oxygen free radical species—the so-called respiratory burst. Free radicals are not only directly cytotoxic but also trigger the synthesis of numerous proinflammatory lipid mediators (eg, PAF and LTB₄) as well as peptide mediators (eg, C5a, TNF- α , and IL-1 β).²⁰⁴ After reperfusion, the free radicals are attacked by free radical scavengers, causing further injury to the cells. This phenomenon has come to be known as *ischemia-induced reperfusion injury* (IIRI). The transition from normal reperfusion and reperfusion injury differs according to tissue type.²⁰⁵ Skin and bone can usually tolerate ischemia for up to 3 hours but muscle and intestinal mucosa are much less tolerant.

Kerrigan and Stotland²⁰⁶ review the clinical significance, etiology, pathophysiology, research investigations, and current management of ischemia and IIRI. Biochemical changes occurring during ischemia “actually prime the tissue to respond in a pathological fashion upon exposure to re-established vascular supply.” The authors discuss the *xanthine oxidase* and *NADPH oxidase* systems, with their production of the toxic radicals superoxide anion (O₂⁻), hydrogen peroxide (H₂O₂), and the hydroxyl radical (OH). These reactive oxygen intermediates lead to a variety of microvascular and inflammatory derangements such as endothelial cell swelling and increased capillary permeability. Leukotrienes (LTB₄), thromboxanes (A₂), and prostaglandins play a major role in these processes. In addition, neutrophils contribute to the acute inflammatory injury of reperfusion through their adhesion, emigration, and proteolytic enzyme degradation.

Carroll and Esclamado²⁰⁵ reviewed flap physiology, ischemia/reperfusion injury, and the use of

pharmacotherapeutic agents in microvascular surgery.

FLAP DELAY

Delay is the surgical interruption of a portion of the blood supply to a flap at a preliminary stage before transfer. The purpose of delay is to increase the surviving length of a flap or to improve the circulation of a flap to diminish the insult of transfer. Despite advances in our understanding of flap physiology the exact mechanism of delay is incompletely defined.

Two schools of thought exist regarding the mechanism of the delay phenomenon. One theory holds that *delay conditions tissue to ischemia*, allowing it to survive on less nutrient blood flow than normally needed. Others believe that *delay improves or increases vascularity*. The process by which delay contributes to flap survival is likely to be a combination of both mechanisms acting to a greater or lesser extent at various times during surgical delay of a flap. Definitive investigations into flap response to decreased blood supply have been hampered by inconsistent results obtained in different laboratory models and lack of adequate controls to establish true increase in surviving length following delay procedures.

Hoopes¹⁹⁴ lists the following five mechanisms of delay:

- sympathectomy
- vascular reorganization
- reactive hyperemia
- acclimatization to hypoxia
- nonspecific inflammatory reaction

A number of anatomic and physiologic investigations into the delay of flaps began during the 1950s. Braithwaite^{207,208} proposed that the likely mechanism of delay consists of vascular reorganization and reactive hyperemia acting through nonlethal ischemia to condition the tissue to survive on less blood flow, together with an increase in size of the vessels in the dermovenous plexus. He postulated that the hyperemia observed when a tubed pedicle is transferred arises from a vascular debt as a result of increased resistance to venous outflow. Brown and McDowell²⁰⁹ stated that the purpose of delay is

to permit gradual hypertrophy of the blood vessels in the pedicle and possibly to accustom the tissues in the flap to a lower oxygen tension or poor circulation. The acclimatization to hypoxia formed the basis for Daniel and Kerrigan's²⁹ belief that delayed flaps have adequate blood flow to survive the early stage of vasoconstriction whereas acute flaps do not.

Hynes²¹⁰ used a variation of the sweat test to detect the presence or absence of sympathetic activity in tubed pedicles. In his study, sympathectomy was the mechanism of delay, and its effect was to enhance vascularity. Jurell²¹¹ analyzed levels of norepinephrine, ATP, and cyclic-AMP in delayed and nondelayed skin flaps to judge the effects of sympathetic denervation on the delay phenomenon. Norepinephrine causes vasoconstriction and metabolic stimulation. When flaps are delayed, blood vessels and adrenergic nerves are severed, causing a spontaneous discharge of neurotransmitters, so that by the time of flap inset there is little release of norepinephrine and consequent diminution in vasoconstriction of the flap. The author confirmed significantly lower levels of norepinephrine in flaps at the second operation.

Seitchik and Kahn²⁷ reviewed the histologic alterations associated with delay and confirmed the findings of Germann and associates²¹² from 1933. Their observations can be summarized as follows:

- longitudinal reorientation of small vessels parallel with the long axis of tubed pedicles at 1 to 7 days postdelay
- increase in size of vessels
- increase in number of small arteries in the subdermal plexus

Pang and colleagues²¹³ monitored skin capillary blood flow and angiogenesis in delayed and nondelayed random skin flaps in the pig. Capillary blood flow was significantly higher in the delayed skin flaps and came from the pedicle only, not as neovascularization from the wound bed or margin. The increase in flow was detectable within 2 days of surgical delay, increased 100% by day 4, and remained at this plateau until day 14. There was, however, no significant increase in the density of arteries between acute and delayed skin flaps. The authors conclude that the delay phenomenon is not dependent on angiogenesis but probably mediated through locally released neurohumoral substances.

However, as reported first by Serafin²¹⁴ and later by Garcia,²¹⁵ both an increase in the number and size and an ingrowth of new vessels from the surrounding tissue occurred about 4 to 5 days postoperatively.

Jonsson and colleagues²¹⁶ noted that surgical delay improved delivery of oxygen to the flap. After delay, blood vessels were seen to reorganize parallel to the incision line and blood flow was increased first by vasodilation and secondly by angiogenesis until about day 14. Rerouting of blood flow by injury, inflammation, and angiogenesis caused by the repair seems to account for a significant portion of the delay phenomenon. Others^{217,218} confirm these findings and suggest that an ischemic tissue gradient provides the impetus for angiogenesis and leads to greater viability of delayed flaps.

The angiogenic process in acute and delayed flaps was investigated by Lopez et al²¹⁹ by means of immunohistochemical methods with monoclonal antibodies to evaluate vascular endothelium. Delayed flaps exhibit an increase in capillaries from 48 hours, and this continues until 7 days after flap elevation. Their theory of delay holds that hypoxia accounts for vasodilation and release of neurohumoral substances. Macrophages subsequently migrate to the skin and release angiogenic factors that, along with other factors by platelets, damaged endothelium, and the elastic layer of vessels, trigger capillary proliferation at the second surgical stage. The period of delay offering maximum survival is about 1 week, whereas the minimum effective time is 2 to 3 days.

Callegari and colleagues²²⁰ subsequently conducted a number of experiments to define the anatomic changes in flaps after surgical delay. The authors reached the following conclusions:

- the survival length of flaps is related to the distance between perforators
- the necrosis line of a flap usually appears in the zone of choke vessels connecting adjacent territories
- a surgical delay results in dilatation of existing vessels with maximal effect in the zone of choke arteries
- the most effective delay is obtained by elevating the flap in stages from the base and not detaching the tip until last

- tissue expansion is a form of surgical delay, particularly in terms of vessel hypertrophy
- similar changes occur when a muscle is delayed. (Application of the delay phenomenon in muscle is further discussed by Barker et al.²²¹)

Dhar and Taylor²²² investigated the sequence of anatomic changes with delay in a dog muscle and rabbit skin model to support their previous conclusion that flap delay results in dilation of existing vessels, not ingrowth of new vessels. The authors concluded that the anatomic effect of delay is focused on the choke anastomotic vessels that link adjacent territories and that the time sequence of delay is similar in different tissue types and in different species. Their delay sequence is divided into four phases (Fig 29):

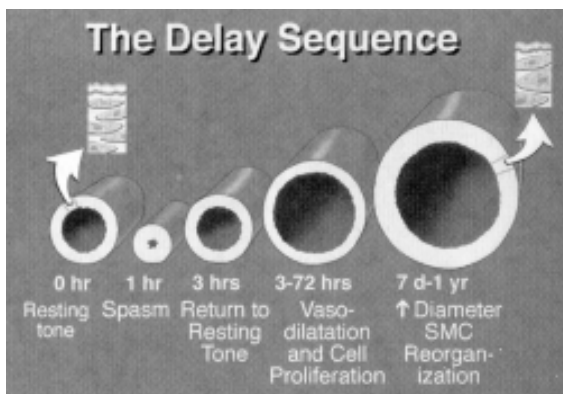


Fig 29. The delay sequence—summary of results. (Reprinted with permission from Dhar SC, Taylor GI: *The delay phenomenon: the story unfolds*. *Plast Reconstr Surg* 104:2079, 1999.)

Phase 1: Initial spasm of all flap vessels which lasts up to 3 hours and is followed by gradual dilation of vessel up to 24 hours.

Phase 2: Between 24 and 72 hours, an accelerated increase in the caliber of flap arteries, primarily at the choke vessel level.

Phase 3: From 72 hours to 7 days, further gradual dilation of vessel lumen associated with vessel wall thickening.

Phase 4: From 7 days on, the choke vessels remain permanently and irreversibly dilated.

Ribuffo and colleagues²²³ selectively delayed the deep and superficial inferior epigastric arteries during TRAM flap reconstructions. The authors found significantly increased caliber of the superior epi-

gastric artery and decreased arterial resistance following delay of either vessel. Restifo et al²²⁴ compared the diameter and flow of the superior epigastric artery after a delay period of 1 or 2 weeks. The delay procedure consisted of division of the superficial and deep inferior epigastric vessels bilaterally. The authors did not find a statistically significant difference between delay after 1 week versus 2 weeks.

In view of the conflicting evidence regarding the anatomy and physiology of delay, the only unquestionable fact seems to be that "surgical delay results in hypertrophy and reorganization of vessels along the axis of a flap"²²⁰ and somehow improves flap survival. Current theories attempt to explain the delay phenomenon as

- a dramatic alteration of blood flow secondary to closure of AV shunts, transection of sympathetic nerves, and hypersensitivity to catecholamines;
- a conditioning of tissue to ischemia; or
- an improvement in vascularity and blood flow brought about through vasodilation, angiogenesis, or both.

Timing of Flap Division

Much of the experimental and clinical data regarding appropriate timing of flap division is based on observations of tubed pedicle flaps, at least some of which may not have required an initial delay procedure. German and associates²¹² concluded that circulation in flaps was reestablished considerably earlier than previously thought. They began dividing their flaps at 14 days posttransfer, and subsequently shortened the interval to 10 days without deleterious effects on flap survival.

Stark, Hong, and Futrell²²⁵ studied the role of ischemia from low perfusion as the trigger of neovascularization in a rat model. They found that neovascularization was enhanced by a perfusion gradient across the wound margins. Poorly perfused tissue brought into a healthy recipient bed enhanced neovascularization, exceeding the need of the ischemic tissue itself to encompass the whole adjacent flap. The authors conclude that this is experimental evidence for the beneficial effect of delayed division of a distant flap.

To summarize the available data,^{194,214,226-229} although flaps can be divided as early as the third

day in animal models, clinically delay should be lengthened to suit specific anatomy, expected flap viability, and characteristics of the recipient site. According to Hauser et al,²³⁰ the traditional 3 weeks for division of an inset flap is probably acceptable in 85% of patients, but is premature in some and excessively long in most. The cumulative experience of many surgeons suggests that most flaps can be divided safely at 10 days to 3 weeks.

FLAP SURVIVAL

Physical Factors

The physical environment of a flap can be manipulated to try to improve flap survival. Sasaki and colleagues²³¹ keep the flap edges *moist* and report an increase in the surviving portion of flaps. McGrath²³² states that a moist environment diminishes the depth of tissue loss and increases flap survival, presumably by minimizing desiccation of ischemic tissue.

Awwad et al²³³ established a direct relationship between local *temperature* and blood flow in island and free flaps. Hypothermia led to vasoconstriction and increased blood viscosity, with resultant decrease in skin blood flow; warming of the flap had the opposite effect. When flaps were cooled to 20°C, Husl and colleagues²³⁴ found a reduction in blood flow to 65% of baseline and in oxygen consumption to 25% of baseline. At 14°C, blood flow ceased completely, probably as a result of increased plasma viscosity.

Mounsey, Pang, and Forest²³⁵ explore the concept of *preconditioning*, in which the protection from ischemic damage induced in cardiac muscle by brief periods of coronary artery occlusion is translated to skeletal muscle. To enhance muscle flap survival and sustain normothermic ischemia, the muscle flap is subjected to intermittent periods of global ischemia followed by reperfusion. Mounsey noted a 20% increase in flap survival at 30-minute intervals.

Preconditioning as a means to enhance flap survival has been tried on both skin and pedicled musculocutaneous flaps.²³⁶ Musculocutaneous flaps fared significantly better after preconditioning, but not so skin flaps; and both flap types showed improved survival when used as free flaps. The mechanism of action in preconditioning is unknown. Proposed

theories include alterations in blood flow, decreased tissue metabolism, selective loss of certain nonessential cellular functions, decreased levels of oxygen-derived-free radicals, and the release of endothelium-derived relaxing factors, which may cause vasodilation and improved distal blood flow.^{235,237}

Tan and others²³⁸ and Ramon et al²³⁹ report increased survival in rat abdominal flaps treated with hyperbaric air (21% O₂) and hyperbaric 100% O₂, but not hyperbaric 8% O₂. Nemiroff and colleagues²⁴⁰ also showed a beneficial effect of *hyperbaric oxygen* (HBO) on acute skin flaps, and noted that, to be helpful, HBO must be given as soon as possible after surgery. These findings are similar to those of Quirinia and Viidik²⁴¹ and Esclamado et al,²⁴² who find that HBO therapy does improve skin flap viability. Kaelin et al²⁴³ found that prolonged preoperative and postoperative hyperbaric oxygen treatment improved survival in a rat skin flap model. The beneficial effect of HBO therapy was thought to be due to increased superoxide dismutase activity.

Not all investigators have had positive results with hyperbaric oxygen. Stewart and associates²⁴⁴ evaluated the effects of HBO with and without free-radical scavengers, and noted no significant increase in flap survival with HBO unless it was combined with either *alpha-tocopherol* or superoxide dismutase and catalase (CAT). Alpha-tocopherol is one of four tocopherols making up vitamin E, whose action is to terminate free-radical reactions by competing for peroxyradicals, especially at cell membrane surfaces. Catalase is an H₂O₂ scavenger.

Pharmacologic

Pang, Forrest, and Morris²⁴⁵ present a concise overview of the pathophysiology of skin flap necrosis and the pharmacologic manipulation of skin flaps to prevent or reverse this process. Carroll and Esclamado²⁰⁵ review the use of pharmacotherapeutic agents in microvascular surgery (Table 4).

A number of experimental studies have looked into drugs to increase flap survival. As Kerrigan²⁹ points out, many of these studies contradict one another, are performed by only one researcher on a number of different experimental models, and often use an inadequate cohort that precludes statistical validation of the results. This section will

TABLE 4
Classification of Common Pharmacotherapeutic Agents Used in Microvascular Surgery

Anticoagulants
Heparin
Hirudin
Dextran
Thrombolytic agents
Streptokinase
Urokinase
Issue Plasminogen-Activator (t-PA)
Acetylated Plasminogen-Streptokinase Activator Complex
Vasodilators
Calcium channel blockers
Dipyridamole
Calcitonin gene-related peptide (CGAP)
Adenosine
Free radical scavengers
Superoxide dismutase (SOD)
Caralase
Deferoxamine
Allopurinol
Antiinflammatory agents
Aspirin
Ibuprofen
Ketorolac
Immunomodulation
Platelet-activating factor
Arachidonic acid metabolites

(Reprinted with permission from Carroll WR, Esclamado RM: *Ischemia/reperfusion injury in microvascular surgery*. *Head Neck* 22:700, 2000.)

focus only on those pharmacologic agents that are commonly used in clinical practice.

Anticoagulants

Dextran, originally designed as a volume expander, has been a tool of the microvascular surgeon for many years. Rothkopf et al²⁴⁶ cite a review of the effects of dextran, which include decrease in platelet adhesiveness and procoagulant activity; increased bleeding time; inhibition of platelet aggregation; and decrease in blood viscosity. With dextran 40 as a perfusate, the patency of arterial inversion grafts (similar to those of Wolfort's²⁴⁷) almost doubled over that of controls.

Working on a venous model, Zhang and Wieslander²⁴⁸ observed increased microcirculatory patency when using dextran 70. The microperfusion was further enhanced when low-molecular-weight heparin was added. Later Salemark, Knudsen, and Dougan²⁴⁹ noted increased patency of microcirculation with dextran 40, but *only on a short term basis*. After 1 week of use, Dextran 40 showed little effect regardless of model.

Disa et al²⁵⁰ conducted a prospective randomized analysis of the morbidity associated with dextran and aspirin prophylaxis in head and neck microsurgery patients. The incidence of system complications for patients receiving low molecular weight dextran for 120 hours was 51%; for 48 hours, it was 29%; and for aspirin, 7%. The authors have discontinued the use of dextran in their patients.

Dextran is associated with significant systemic morbidity including anaphylaxis, pulmonary edema, cardiac complications, adult respiratory distress syndrome, and renal failure. The routine use of dextran in free tissue transfer is now discouraged.^{251,252}

Heparin is an effective anticoagulant that acts in conjunction with antithrombin III to inhibit thrombosis by inactivation factor X. Heparin is more effective at preventing venous thrombosis than arterial thrombosis. Sawada, Hatayama, and Sone²⁵³ report improved flap survival when heparin was continuously and topically administered to specific regions of their flaps. They attributed the beneficial effect to platelet disaggregation and maintenance of vascular patency by heparin, not to vasodilatation and increased vascular flow. These findings correspond with those of the Cox group,²⁵⁴ who noted a dose-related increase in flap patency with heparin. The effect was first noted at heparin concentrations of 100 U/mL, a dose the researchers find to be ideal from a morbidity standpoint.

Investigators from Duke University Medical Center²⁵⁵ report that both unfractionated and low molecular weight heparin (LMWH) improved microcirculatory perfusion, but only LMWH improved anastomotic patency while minimizing hemorrhage. Kroll et al²⁵⁶ retrospectively reviewed 517 free flaps and noted a lower incidence of flap loss when heparin was administered (either as bolus or in low dose), but this difference was not statistically significant. Hudson et al²⁵⁷ reported the experimental and clinical use of a catheter placed proximal to the venous anastomosis for the direct infusion of heparin to prevent venous thrombosis. The local partial thromboplastin time was elevated but the systemic value remained normal, therefore reducing the systemic complications of heparin.

Thrombolytic agents act by the stimulation of plasminogen which is the precursor of plasmin which acts to cleave fibrin within a thrombus. Streptokinase and urokinase are first-generation agents and tissue plasminogen activator (t-PA) and acetylated

plasminogen-streptokinase activator complex (APSAC) are second-generation agents. Thrombolytics have been effective in animal models for the salvage of flaps after microvascular thrombosis.²⁵⁸

Streptokinase is a nonenzymatic protein derived from group C beta-hemolytic streptococci. In flap salvage it is injected into the arterial side of the flap and drained through the venous side, usually avoiding systemic effects. Doses of 50,000 to 125,000 units have been used clinically.²⁰⁵

Yii et al²⁵⁹ reported 6 free flaps that were salvaged and 2 that failed after the clinical use of thrombolytics (urokinase and t-PA) for pedicle thrombosis. Serletti et al²⁶⁰ reported 5 cases of venous thrombosis that were salvaged by revision of the venous anastomosis followed by intraoperative infusion of 250,000 units of urokinase.

Leeches have been used in medicine since ancient times for the treatment of various ailments.²⁶¹ Recently there has been renewed interest in medicinal leeches, *Hirudo medicinalis*, for the relief of venous congestion after free tissue transfers and replantations.^{262,263} Leeches exert their effect by injecting hirudin at the site of bite. Hirudin is a naturally occurring anticoagulant that inhibits the conversion of fibrin to fibrinogen and that, unlike heparin, does not require antithrombin-III for activation. In addition, leeches secrete hyaluronidase, which facilitates spread of the anticoagulant within the tissues, and a vasodilator, which contributes to prolonged bleeding (up to 48 hrs).^{261,264,265} Moreover, leeches have a mechanical action by creating physical channels through which venous drainage can occur. Nevertheless, according to Rodgers et al,²⁶⁴ "no controlled study has proven the efficacy of leeching."

The main indication for the use of leeches is in cases of venous congestion where outflow is insufficient or venous channels are either absent or unsuitable for anastomosis. The primary contraindication to leeches is arterial insufficiency, in which case the leeches will simply not attach themselves to the flap.

Leech therapy is not without potential complications. The most significant risks are bacterial infection from the gram-negative rod *Aeromonas hydrophila* (which is the leech enteric organism responsible for red cell digestion), anaphylaxis, persistent bleeding, and excessive scarring. Current recommendations for treatment with medicinal

leeches include prophylaxis with an aminoglycoside and a third-generation cephalosporin and caution when treating immunocompromised patients.^{261,265}

Vasodilators

Many studies²⁶⁶⁻²⁷⁰ show increased flap survival in rats treated with *calcium-channel blockers*—eg, diltiazem, nifedipine, nitrendipine, verapamil—which act on the vascular smooth muscles to cause vasodilation and improve circulation in the flap. These agents do not restrict their effects to smooth muscle, however. For instance, diltiazem has been shown to stimulate the release of prostacyclin (PGI₂), a potent vasodilator and antiplatelet aggregator, from vascular endothelial cells.²⁶⁶

Jernbeck and Dalsgaard²⁷¹ describe the clinical application of intravenous *calcitonin gene-related peptide* in the treatment of flaps with compromised circulation.

Topical *nitroglycerin* is a potent vasodilator with a greater effect on the venous circulation than on arterial vessels. Rohrich and colleagues²⁷² reported improved survival of axial flaps in pigs and rats treated with nitroglycerin ointment, as did Price and Pearl,²⁷³ who applied nitroglycerin transdermally. Nichter,²⁷⁴ on the other hand, found no increase in survival of random pattern flaps in rats treated with nitroglycerin paste.

Ichioka and others²⁷⁵ evaluated the effects of amrinone, a selective phosphodiesterase III inhibitor, and found enhanced microcirculatory blood flow from its positive inotropic and vasodilating properties, with a corresponding increase in viable area of flaps. In a later clinical study, Ichioka et al²⁷⁶ demonstrated an increase in microcirculatory blood flow in flaps after intravenous administration and a decrease in vasospasm after topical application of amrinone to the pedicle. The results obtained with amrinone were comparable to the results obtained with prostaglandin E1 and lidocaine.

Grossman and associates²⁷⁷ report increased flap survival in a rat model with intraperitoneal injection of *dimethyl sulfoxide* (DMSO) or hyaluronidase, and postulate a decrease in tissue edema with resultant improved blood flow. Haller, Trachy, and Cummings²⁷⁸ note improved flap perfusion after intraperitoneal injection of DMSO as measured by laser Doppler velocimetry and perfusion flowmetry. Rand-Luby and coworkers²⁷⁹ determined that topi-

cal application of DMSO increased flap viability in humans by controlling skin ischemia through vasodilation, reduction of platelet aggregation, or the free-radical scavenging properties of DMSO. They find DMSO safe to use in a clinical setting.

The effects of topical *lidocaine* and *pentobarbital*, which are believed to inhibit endothelium-dependent relaxation on the vascular smooth muscle, were studied by Wadstrom and Gerdin.²⁸⁰ They conclude that although there is an effective and prompt resolution of mechanically induced vasospasm, the effects are circumvented by microvascular thrombosis.

Prostacyclin (PGI₂) is a potent vasodilator which also decreases platelet activation and impairs the release of cytotoxins from white blood cells.²⁰⁵ Emerson and Sykes²⁸¹ showed improved survival of random skin flaps in rats after treatment with prostacyclin. PGI₂ was found to be effective only if given at the time of flap elevation and continued postoperatively. The authors theorize that perhaps PGI₂ also stimulates new vessel formation in ischemic tissue. Others^{282,283} have had similar experiences with exogenously administered PGI₂ in laboratory animals, but caution that high-dose prostacyclin actually has a detrimental effect on skin flap survival.²⁸³ Gateley, McAnulty, and Martin²⁸⁴ report two instances of intravenous infusion of prostacyclin for impending free flap failure, with subsequent pinking up of the flaps and a successful outcome to the cases.

A PGI₂ analog, *iloprost*, was evaluated by Senderoff et al,²⁸⁵ who found significantly higher flap survival rates in the study group compared with flaps perfused with lactated Ringer's or urokinase solutions. The authors note that iloprost has the same action and potency as PGI₂, but with greater chemical stability and therapeutic potential. In addition, iloprost seems to have a cytoprotective effect that prevents lysosomal enzyme release during tissue hypoxia. Renaud and associates²⁸⁶ report successful resolution of a failing free flap after intraarterial infusion of iloprost in the acute setting and intravenous administration postoperatively.

Suzuki and colleagues²⁸⁷ described the use of *prostaglandin E₁* (PGE₁). Its effects were very similar to prostacyclin in causing peripheral vasodilation and platelet disaggregation. PGE₂ may be available in a more stable form and, like PGI₁, has been noted to have a biphasic response—ie, higher doses

of the agent result in hypotension and significant decrease in blood flow to the whole skin flap.

Free Radical Scavengers

A number of investigators^{288–292} have shown increased flap survival with *allopurinol* treatment in a rat skin model. Allopurinol inhibits xanthine oxidase and in the process leads to diminished free radical production and retards the loss of purine substrates available for high-energy metabolic synthesis. Picard-Ami and colleagues²⁹³ note that xanthine oxidase levels in human tissue are 1/40th of those in rats, casting doubt on XO as a major source of free radicals responsible for tissue injury and flap necrosis in human skin.

Treatment of skin flaps with *superoxide dismutase*, a scavenger of free oxygen radicals, has been shown to improve flap survival.²⁰¹ Manson and colleagues²⁰³ reported that a single dose of SOD improved flap survival from 38% to 76% in rats. Tissue levels of SOD were higher in the surviving portions of flaps. Suzuki and coworkers²⁹⁴ confirmed the beneficial effects of SOD in preventing flap necrosis, and suggested that reperfusion following ischemia, not continuous incomplete ischemia, produces reactive oxygen species and a gradual increase in blood flow in the distal flap. Hawkes, Young, and Cleland²⁹⁵ note anaphylactic reactions in a pig model associated with the use of superoxide dismutase.

Angel and colleagues²⁹⁶ also demonstrated improved flap survival with *deferoxamine*, an iron chelator and free radical scavenger. Deferoxamine has been shown to diminish flap necrosis caused by underlying hematomas. Its beneficial effect on flaps probably relates to its ability to scavenge free radicals, although Green and associates²⁹⁷ state that the logic behind using chelators such as deferoxamine is to inhibit hydroxy radical formation from superoxide radicals.

Antiinflammatory Agents

The role of steroids on flap survival continues to be hotly debated. Nancarrow²⁹⁸ demonstrated a 25% increase in survival of groin island flaps in rats after administration of 1.5 mg/Kg of *dexamethasone* 12 hours preoperatively. Nakatsuka and others²⁹⁹ studied the effect of *methylprednisolone* on

pig musculocutaneous, axial, and random pattern flaps. They found no increase in area of flap survival or fluorescein dye penetration. There was no increase in skin capillary blood flow as measured by entrapment of radioactive microspheres. In summary, there was no evidence to support the clinical use of corticosteroids to enhance flap viability. These findings were in contrast with those of Esclamado, Larrabee, and Zel,²⁴² who observed that perioperative steroids did improve skin flap viability.

Kerrigan and Stotland²⁹⁵ review the accumulated data regarding attempts to modulate the proinflammatory mechanism involved in reperfusion injury. Various studies have involved platelet activating factor antagonism; selective inhibition of leukotriene synthesis to prevent leukocyte-endothelial cell adhesion and macromolecular leakage; inhibition of thromboxane and complement; and antibodies directed against neutrophil toxicity.

Thromboxane A₂ (TxA₂) is a potent vasoconstrictor and platelet aggregator released by platelets. Prostacyclin (PGI₂) is a potent vasodilator and inhibitor of platelet aggregation produced by endothelial cells. Both are products of arachidonic acid metabolism and have strong effects at the endothelial cell level²⁸⁵ (Fig 30).

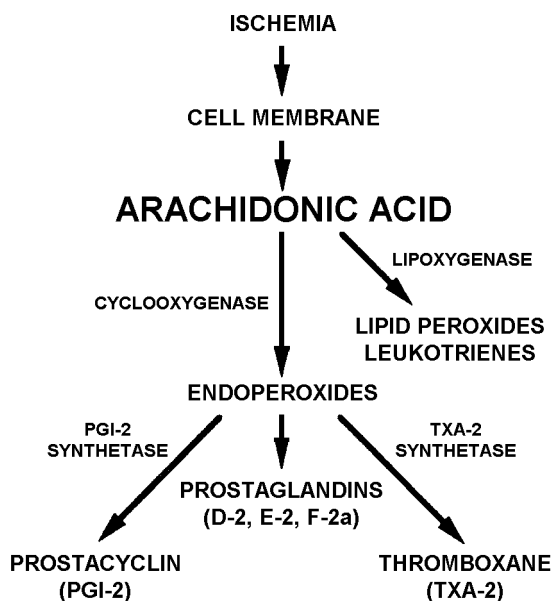


Fig 30. The metabolism of arachidonic acid. (Reprinted with permission from Senderoff DM, Israeli D, Zhang WX, et al: Iloprost improves survival of ischemic experimental skin flaps. *Ann Plast Surg* 32:490, 1994.)

Aspirin (ASA) acetylates the enzyme cyclooxygenase, thereby decreasing the synthesis of TXA₂ in platelets and PGI₂ in the vessel walls. At low doses the effect of aspirin is selective and only the cyclooxygenase system in platelets is inhibited and the formation of thromboxane is blocked. In the laboratory, preoperative aspirin decreases thrombus formation at venous anastomosis and improves capillary perfusion in the microcirculation.³⁰⁰ Other studies demonstrate increased early anastomotic patency but no difference from controls after 24 hour to a week.²⁰⁵

Salemark and associates³⁰¹ studied the possible role of ASA as an antithrombogenic agent. Their results were disappointing in that ASA showed both beneficial and detrimental effects depending on when the injected drug was exposed to the subendothelial layers of the damaged vessel wall.

There is no empiric support in the literature for the use of aspirin postoperatively.²⁰⁵ Buckley, Davidson, and Das³⁰² explored the effects of another NSAID, ketorolac tromethamine (Toradol). Despite significantly prolonged mean bleeding times, markedly reduced platelet aggregation, and considerably higher patency rates in the ketorolac group at 20 min, all vessels thrombosed at 24 hours.

Nicotine

Forrest, Pang, and Lindsay³⁰³ described the effects of nicotine on capillary blood flow in random pattern skin flaps elevated in rats. The authors found that nicotine significantly decreased capillary blood flow, distal perfusion, and flap survival in a dose- and time-dependent fashion, and proposed several hypotheses to explain the mechanism of action of the drug. Black et al³⁰⁴ note that acute exposure of human skin vasculature to nicotine is associated with amplification of norepinephrine-induced skin vasoconstriction and impairment of endothelium-dependent skin vasorelaxation.

MONITORING FLAP VASCULARITY

Despite the clinical success of free flaps, strict evaluation of flap perfusion is essential to prevent, recognize, and treat complications. The failure rate of free tissue transfer is reported to be less than 5%; however, the incidence of pedicle thrombosis is higher than the failure rate would reflect due to a

salvage rate after pedicle thrombosis that ranges from 36%–70%.²⁵⁹ Several techniques have been suggested to assess perfusion of flap tissues in an attempt to predict flap survival.^{29,305,306} These methods are reviewed by Furnas and Rosen,³⁰⁷ Truelson,³⁰⁸ Bradford,³⁰⁹ and Gapany.³¹⁰

Brown et al³¹¹ retrospectively reviewed successful free flap salvage at their institution. Due to more successful salvage within the first 24 hours after the initial surgery, they recommended hourly monitoring for the first 24 hours and then every 4 hours for 48 hours.

Table 5 from Daniel and Kerrigan²⁹ summarizes various monitoring tools used to assess flap viability. According to the authors, the ideal monitoring device should

- reflect the condition of the entire (buried) flap
- be reliable, reproducible, consistent, and sensitive
- provide continuous monitoring
- be user-friendly and easily interpreted
- be affordable
- be relatively unaffected by the external environment

Subjective/Physical Criteria

“Clinical observation remains the gold standard against which monitoring systems are generally measured...and it...fulfills many of the criteria of the ideal monitoring system.”³⁰⁶ Climo³¹² surveyed various clinical measurements of flap vascularity as of 1951 and noted that the *color of the blood oozing from the dermis* was a reliable indicator of circulatory status. Blue dermal bleeding was the best warning sign of inadequate perfusion. Hoopes,¹⁹⁴ however, believes that “it is a misconception to equate blood supply with viability; the crucial test of adequacy of circulation is survival of the pedicled flap tissue.”

Daniel and Kerrigan²⁹ review various techniques for subjectively evaluating flap viability and note that color, capillary blanching, and warmth are unreliable and of limited use. Of the subjective tests, bleeding from a stab wound is probably the most accurate. Table 6 outlines the clinical signs that can be used to differentiate venous from arterial maladies in flaps.

Temperature monitoring is a simple technique to evaluate flap viability. It can be accomplished in a number of ways, including surface temperature and differential thermometry. In general, surface temperature can be taken easily, requires relatively inexpensive equipment, and is clinically useful in monitoring for extrinsic complications. As an indicator of intrinsic flap failure it is inadequate, however. Differential thermometry is a useful tool to monitor vascular patency in buried free tissue transfers in which a temperature gradient exceeding 3°C is considered significant.²⁹

Jones, Dunscombe, and Greenhalgh³¹³ took serial temperature measurements of flap skin and control skin simultaneously in order to negate environmental and metabolic variables. They found that skin temperature responded slowly to vascular occlusion and was not a reliable indicator of flap failure in the immediate postoperative period. Temperature readings, however, can be used effectively to track the course of replanted digits.

Khouri and Shaw³¹⁴ review surface temperature recordings of 600 free flaps and conclude that when properly applied and interpreted, its sensitivity and predictive value approach 98% and 75%, making it a simple, inexpensive, and highly reliable technique of free flap monitoring.

Cho et al³¹⁵ and Akin and Basut³¹⁶ created small monitoring flaps that are exteriorized to facilitate monitoring of buried free flaps. The monitoring flap is based on a perforator fed by the main pedicle. The authors were able to predict pedicle compromise from the appearance of the monitoring flap.

Vital Dye Measurements

Fluorescein has been used for over 40 years to clinically assess flap vascularity.³¹⁷ In 1962 Myers³¹⁸ reviewed the history of fluorescein and used it to determine the viability of skin flaps after radical mastectomy. McCraw, Myers, and Shanklin³¹⁹ delineated the pharmacologic characteristics of fluorescein that enabled it to be an indicator of blood flow, emphasized its merits in predicting the viability of arterial flaps, and suggested clinical applications. Fluorescein is believed to be better than 70% accurate as an indicator of the circulatory status of a flap.

Fluorescein is usually given in a bolus injection of 500 to 1000 mg (15 mg/Kg). After a waiting

TABLE 5
Techniques for Monitoring Flap Perfusion

Test	Setting	Uses	Number of Sites	Repeat-ability	Time to perform	Comments
Color	Clinical	Skin flaps, I&E	Infinite	Infinite	Seconds	Not a reliable test
Capillary blanching	Clinical	Skin flaps, I&E	Infinite	Infinite	Seconds	Not very reliable, needs experience to interpret
Warmth	Clinical	Skin flaps, I&E	Infinite	Infinite	Seconds	Much too subjective to be of clinical use
Stab wound bleeding	Clinical	Skin and muscle flaps, E	Infinite	Infinite	Seconds	Useful subjective measure, especially in free flaps
pH	Clinical and research	Skin and buried flaps, I&E	One site	Infinite	Minutes	Has been disappointing, although possibilities for buried tissue transfers still exist
tcpO ₂	Clinical and research	Skin flaps, E	One site	Infinite	20–30 min	Has been disappointing and most have abandoned its use
Laser Doppler	Clinical and research	Skin and buried flaps, I&E	One site	Infinite	Continuous	Most promising test currently available for clinical use; implantable probes recently developed
Photoplethysmography	Clinical	Skin flap, I&E	One site	Infinite	Minutes	Disappointing results, although some modifications have improved its use
Surface temperature	Clinical and research	Skin flaps, E	Multiple sites, continuous	Infinite	Minutes	Most widely used test for monitoring free flaps but must be interpreted by experienced persons
Differential thermometry	Clinical and research	Skin and buried flaps, E	One site	Infinite	Continuous	Current standard for buried tissue transfers, although not widely used
Fluorescein	Clinical and research	Skin flaps, I&E	Whole flap	Every 8 hr	30 min	Currently the best test available for intrinsic failure
Dermofluorometry	Clinical and research	Skin flaps, I&E	One site, or more sequentially	Infinite	20–30 min	Relatively inexpensive instrumentation for very useful information
Clearance (H, Tc, Xe, etc.)	Clinical and research	Skin and ?buried flaps, I&E	One site, or more sequentially	Infinite	30–60 min	Particularly useful for research laboratory; equipment may be cumbersome for clinical use
Radioactive microspheres	Research	All flaps, I&E	Infinite	3 times	Hours	Golden standard for laboratory; test takes seconds to perform but data analysis takes hours
Electromagnetic flowmetry	Research	All island flaps, E	One site	Infinite	Continuous	Technically demanding but gives excellent measure of total flap flow; cannot differentiate nutrient from total flow

I = intrinsic failure; E = extrinsic complications.

(Reprinted with permission from Daniel RK, Kerrigan CL: *Principles and physiology of skin flap surgery*. In: McCarthy JG (ed), *Plastic Surgery*. Philadelphia, Saunders, 1990. Vol 1, Ch 9.)

period of 20–30 min, the extent of dye staining in those tissues which are adequately perfused can be seen with a Wood's lamp. If necessary the test can be repeated every 8 hours,²⁹ although others suggest waiting 24 hrs.³²⁰ Pang and others³²¹ report that when the fluorescein test is performed 1 hour

after flap elevation, the length of flap that is viable is consistently underestimated. When the test is performed at 18 hours postoperatively, the length of dye staining and skin viability correlated very well. These results were obtained in random flaps, axial pattern flaps, and musculocutaneous flaps.

TABLE 6
Signs of Arterial Occlusion and Venous Congestion

	ARTERIAL OCCLUSION	VENOUS CONGESTION
Skin color	Pale, mottled, bluish, or white	Cyanotic, bluish, or dusky
Capillary refill	Sluggish	Brisker than normal
Tissue turgor	Prune-like, turgor decreased	Tense, swollen; turgor increased
Dermal bleeding	Scant amount of dark blood and/or serum	Rapid bleeding of dark blood
Temperature	Cool	Cool

(Reprinted with permission from Adams JF, Lassen LF: *Leech therapy for venous congestion following myocutaneous pectoralis flap reconstruction. ORL-Head Neck Nurs 13:12, 1995.*)

Myers and Donovan³²² note that all techniques for evaluating flap perfusion with fluorescein are reasonably accurate, including the traditional Wood's lamp method which was as reliable as newer ones. In their opinion, inaccuracies in fluorescein testing are probably inherent and unavoidable, in that it only measures vascularity at the time the dye is given and blood supply can change. More specifics are given by Odland et al,³²³ who note that since fluorescein is a derivative of phthalein, a pH indicator, and ischemic tissues become acidotic, the acidosis might quench the expected fluorescence in the distal skin flap.

Silverman, Norton, and Brousseau³²⁴ described the use of *perfusion fluorometry*, a technique where the admitted fluorescence of the tissue is measured using a fiberoptic light guide (dermofluorometer) and an objective value of dye-fluorescence units is obtained. Accurate readings can be made as early as 2 minutes after injection, and serial injections and measurements are possible because the doses of dye are small (0.15 mg/Kg). The method was 96% accurate in predicting ultimate flap viability at lower dosage and with fewer side-effects than fluorescein testing.

Dermofluorometry has recently been applied to venous flaps. Suzuki et al³²⁵ compared arterialized to nonarterialized and random-pattern flaps and noted that the instrument is a reliable indicator of circulation in all types of flaps evaluated.

Thomson and Kerrigan³²⁶ described the formula for calculating the dye fluorescence index (DFI) and documented that fluorescence varies with blood supply. The authors confirmed the accuracy of

dermofluorometry in predicting skin flap survival in pigs. Clinically, a DFI of 30% or more is considered safe.

Issing and Naumann³²⁷ used computer-aided digital morphometry (CADM) to compare fluorescein staining, skin pH, and skin temperature in the evaluation of skin flap perfusion. They conclude that fluorescein staining is the most accurate predictor of flap viability.

Indocyanine green (ICG) is a second-generation dye that can be used as a clinical marker of cutaneous blood flow. The principle of monitoring is similar to that of fluorescein, but the chemical properties of indocyanine green are more suitable to clinical use.³²⁸ ICG has been used successfully in experimental and clinical models.³²⁸⁻³³¹ Intraoperative laser-induced fluorescence of ICG showed arterial spasm, venous congestion, and regional hypoperfusion in microvascular flaps and correlated strongly with the clinical outcome.³²⁹

Photoelectric Assessment

Two types of Doppler instruments are currently in clinical use. The first is the *ultrasound* Doppler, which uses reflected sound to pick up pulsatile vessels. The second is the *laser* Doppler, which measures the frequency shift of light and therefore has limited penetration (1.5 mm).²⁹

Amerhauser and associates³³² evaluated *color flow ultrasound* (CFUS) in an experimental and clinical setting and noted that it was sensitive to venous and arterial insufficiency at flow rates as low as 3.0 mL/min. They found CFUS was capable of differentiating blood flow and was proficient at visualizing luminal dissections, intimal flaps, thromboses, and arteriolar constrictions.

The *laser Doppler flowmeter* gives an output voltage proportional to the total flux of red blood cells in the volume of tissue sampled (approximately 1 mm³), and thus includes the subcapillary plexus. The technique yields two values:³³³ a Doppler flow measurement, which is a reflection of the number and velocity of moving red blood cells and which decreases to low levels in response to arterial or venous occlusion; and a photometry value, which is a photoplethysmographic reading of the intensity of the back-scattered light. This value does not change with arterial occlusion but decreases in response to venous occlusion, helping to distinguish

between venous and arterial causes of flap embarrassment.

Hallock³³⁴ investigated the critical threshold for tissue viability as determined by laser Doppler flowmetry, and found that a baseline of 30% is generally sufficient to predict flap survival. Heden and associates^{335,336} found that laser Doppler flowmetry correlated well with actual skin viability and necrosis in the immediate postoperative period. A sensitivity of 93% and specificity of 94% were recorded by the Hovius group.³³⁷

Bircher et al³³⁸ provide an in-depth overview of guidelines for the measurement of cutaneous blood flow by laser Doppler flowmetry. Svensson, Holmberg, and Svedman³³⁹ review the proper interpretation of laser Doppler recordings from free flaps and suggest the following guidelines to improve accuracy of the analysis:

- a fixed probe
- continuous recordings
- attention to physiologic fluctuations and trends

Many factors affect the clinical usefulness of these techniques. Among them are ease of application, equipment cost, and expertise required to operate. Silverman and coworkers³⁴⁰ compared the laser Doppler, perfusion fluorometry, and transcutaneous oxygen assay methods and concluded that fluorometry is more precise and can be used to monitor several areas in serial fashion. Transcutaneous oxygen and Doppler probing were better suited for continuous monitoring. Cummings and colleagues³⁴¹ reached similar conclusions but emphasize, as does Marks,³⁴² that beginning 24 hours postoperatively the laser Doppler technique is the most sensitive.

Place, Witt, and Hendricks³⁴³ agree that Doppler flowmetry is a useful tool for assessing flap viability, but stress that since postoperative blood flow is a dynamic process that peaks about 52 to 80 hours and returns to baseline some 120 hours postoperatively, no single measurement is indicative of anything except the status at that one time.

Yuen and Feng³⁴⁴ reported a 5-year experience with laser Doppler flowmeter monitoring of 232 microvascular flaps. Vascular compromise was detected in all cases, with no false positives or negatives. The salvage rate was 69% and the overall success rate was 98%.

Advantages of Doppler probing are high reliability (approaching 100% 24 hrs after flap transfer) and the ability to continuously monitor skin perfusion by a noninvasive technique. Disadvantages are that it is not quantitative, it obtains information only from a single site, is sensitive to movement of the subject, and has limited accuracy below the critical threshold at which tissue necrosis is guaranteed.³⁴⁵ The scanning laser Doppler³⁴⁶ and laser flowgraph³⁴⁷ may give a more global picture of the flap than could be obtained by Doppler flowmetry. In Kerrigan and Daniel's view, however, "no single technique is universally applicable or superior to all others."¹⁹⁹

Metabolic

Tsur and coworkers³⁴⁸ measured *transcutaneous oxygen tension* in delayed axial and random pattern skin flaps by means of an oxygen electrode applied to the skin. They found oxygen partial-pressure measurements to be an effective predictor of the effectiveness of the delay procedure. Similarly, Hjortdal and colleagues³⁴⁹ found measurement of subcutaneous and intramuscular oxygen tension in pig island flaps to be a sensitive indicator of acute impairment of the supplying vessels. Kerrigan and Daniel³⁵⁰ evaluated capillary blood samples in pig island flaps and noted that while PO_2 and PCO_2 measurements were highly variable, changes in hematocrit and pH were useful predictors of flap viability. Other less popular methods of evaluating circulation in a flap include measurement of the fibrillation potential in skeletal muscle,³⁵¹ magnetic resonance imaging,³⁵² and magnetic resonance spectroscopy.³⁵³

Golde and Mahoney³⁵⁴ described an implantable optochemical oxygen-sensing electrode device or *optode* that allows rapid and continuous monitoring of tissue PO_2 and which was felt to reliably reflect vascular occlusion. The probe is small, easily implantable, and independent of anastomotic proximity, but the authors did not comment on the ability of the optode to differentiate between arterial and venous compromise. The implantable PO_2 sensor in Hofer's³⁵⁵ series accurately indicated flap failure in all cases, yet the authors' decision to reexplore a failing free flap was still based on clinical observation.

Photoplethysmography is a technique that measures fluid volume by detecting variations in infra-red light absorption by the skin. Its current use in clinical practice has several limitations.^{29,305,307} In addition to displaying the waveforms of the photoplethysmograph, the *pulse oximeter* also measures light absorption to derive oxygen saturation of arterial hemoglobin. The device is commonly used in anesthesiology and was evaluated by Lindsey et al,³⁵⁶ who demonstrated its usefulness but recommended further study to develop specific guidelines before it was universally accepted in clinical practice.

Irwin et al³⁵⁷ evaluated a newer and noninvasive technique for assessing flap circulation that involves continuous monitoring of changes in the oxy-, deoxy-, and total hemoglobin concentrations of flap blood. In addition to deeper evaluation (up to 10 cm) of flaps than is possible with the laser Doppler, *near infrared spectroscopy* (NIRS) was able to delineate the difference between arterial, venous, and total vascular occlusion.

Other means of evaluating flaps include quantitative tests, clearance tests, radioactive microspheres, and electromagnetic flowmetry. These are essentially reserved for experimental purposes only, and will not be discussed here.

SKIN EXPANSION

James F Thornton MD

HISTORY

Bennet and Hirt¹ review the history of tissue expansion and note that its origins date to Celsus (25 BC–50 AD), who “described the technique of wound closure by creating, stretching, and approximating skin flaps.” In 1957 Neumann² reported the first clinical use of controlled skin expansion. He placed a rubber balloon subcutaneously beneath the temporal scalp and postauricular skin. Over the next 2 months the balloon was gradually expanded, increasing the skin area by approximately 50% or enough to provide sufficient cover for cartilage graft reconstruction of a traumatic ear defect. Not until 1976, when Radovan³ reported his work with tissue expansion for breast reconstruction, did the potential usefulness of this technique become obvious. Since then, controlled tissue expansion has been used for the

reconstruction of all areas of the body in many diverse problems. Baker⁴ summarizes the history and dynamics of tissue expansion.

TECHNIQUE

Modern expanders are made of silicon elastomers and come in several shapes and sizes or are custom-made to fit individual needs. The expander is usually connected to a subcutaneous valve through which isotonic saline is injected for incremental expansion. Jackson and colleagues⁵ described using an external reservoir that was associated with few complications, but the authors do not recommend it in cases where a permanent prosthesis is planned, such as for breast reconstruction.

The time interval between injections of saline for gradual expansion depends on the nature of the defect and its anatomic location as well as host tissue characteristics. The interval ranges from 3 to 10 days. Hallock and Rice⁶ advocate monitoring the expansion process with a combination of transcutaneous electrodes for measuring oxygen levels, implant pressure, and local perfusion to gauge the end-point of each expansion session. Comparing simultaneous laser Doppler flowmetry and transcutaneous oxygen monitoring,⁷ they note that either technique records diminished circulation in response to increased expansion, but adequate tissue circulation still exists at the threshold of pain.

Pietila and colleagues⁸ recommended overfilling the expander to increase the amount of expansion at each session and shorten the total expansion period, but Van Beek and Adson⁹ caution that if the intraluminal pressure exceeds 500 mmHg, leakage at the injection port is likely, especially when using large-caliber needles. Although rapid expansion is possible in some circumstances, preserving tissue integrity takes precedence over speed of expansion.

Van Rappard et al¹⁰ evaluated the differences in surface area of expanded tissue in relation to shape of the individual expander. For expanders with a round base, a rectangular base, or a crescentic base, the respective gains were 25%, 38%, and 32%. The authors concluded that an expander of appropriate size has a base that is 2.5 times as large as the defect to be closed.

Matton and associates¹¹ described a “universal incision” for tissue expander insertion that has been shown to minimize the complications seen with

other incisions. Austad and Rose¹² described a self-inflating expander containing hypertonic sodium chloride crystals within a shell that gradually fills through osmosis. Besides the protracted inflation times of 8 to 14 weeks, the device was plagued by reports of skin necrosis and implant rupture. The concept of a self-inflating expander was explored further by Wiese,¹³ who incorporated a copolymer of methylmethacrylate and N-vinyl-2-pyrrolidone in a gel casing capable of generating a maximum pressure of 235 mmHg. The author notes that this expander is “biocompatible” and holds promise in the area of tissue expansion without the disadvantages noted above.

Bergé and colleagues¹⁴ reported direct closure with Hydrogel tissue expanders in 9 of 10 patients. The defects closed were the result of radial forearm flap harvest. At implantation the initial volume of the expanders was 10 mm, and over 20 days they were inflated to 100 mm.

HISTOLOGY OF EXPANDED SKIN

Johnson et al¹⁵ review the histology and physiology of tissue expansion. Austad and colleagues^{16,17} studied changes in the epidermis, dermis, and subcutaneous tissue of expanded guinea pig skin. Compared with normal skin, expanded skin showed a significantly *thicker epidermis*—which they attributed either to increased mitotic rate or decreased rate of cell turnover—and a *thinner dermis* and panniculus carnosus. There was minimal inflammatory reaction to the expander. Their conclusions signified that skin expansion is not simply a matter of stretching skin but the actual formation of additional new skin with all the attributes of the original tissue.

Argenta and coworkers¹⁸ summarize the histomorphologic changes occurring in expanded skin. The epidermis does not change in thickness, although there is an undulation of the basal lamina and a loss of intercellular spaces. The surrounding dermis decreases in thickness considerably, and increased numbers of fibroblasts and myofibroblasts are seen in the expander capsule. The fibrous capsule that forms around the implant consists of thick bundles of collagen fibers and elongated fibroblasts and myofibroblasts. Tissue expansion also triggers an increase in vasculature, primarily at the junction of the capsule and host tissue and to a

lesser degree in the dermis. Muscle and fat both diminish in mass in response to expansion, and while there is no loss of muscle function, the loss of fat appears to be permanent.

Like Austad, Pasyk et al¹⁹ noted significant thickening of the epidermis after 5 weeks of expansion, as well as significant thinning of the dermis and subcutaneous tissues. Leighton and associates²⁰ found differential thinning of all tissue layers except the epidermis, which was unchanged. Olenius and Johansson²¹ also report significant increase in epidermal thickness, but 6 months after the end of expansion the epidermis had returned to normal thickness. Olenius, Dalsgaard, and Wickman²² studied the mitotic activity of human skin samples after tissue expansion and noted a statistically significant rise in the number of labeled basal and suprabasal keratinocytes. This confirmed earlier findings of increased mitosis¹⁷ and suggested a *net gain* of tissue, not only by stretching the existing area but through generation of new tissue.

The phenomenon of tissue growth in response to mechanical expansion has been investigated by Takei and colleagues.²³ The authors state: “The mechanism by which strain causes an enhancement of cellular growth appears to be a network of several integrated cascades, implicating growth factors, cytoskeleton, and the protein kinase family. . . . Additional evidence has accumulated that mechanical strain stimulates signal transduction pathways that could trigger a series of cascades eventually leading to a new skin production.”²³

Normal human skin is continually undergoing stretching and relaxation. *Collagen* fibers exist in a convoluted form and, unlike fibers made of *elastin*, are incapable of returning to their relaxed state after being stretched. If the limits of the elastic fibers are exceeded, permanent deformation of collagen may result.²⁴ Melis and colleagues²⁵ found changes in the orientation of collagen fibers in the dermis as a result of skin stretching. After 15 minutes of stretching with a skin-stretching device, the fibers became aligned in the direction of the stretching force, perpendicular to the wound margin. This dynamic realignment of collagen fibers explains the significantly decreased wound closing tension resulting from skin stretching and explains how skin stretches beyond its inherent extensibility.

Chang et al²⁶ found that tissue expansion in the rat inhibits the contractile function of dermal fibro-

blasts in vitro. This effect was more pronounced after 5 weeks than in the first 1 or 2 weeks of expansion. Lee, Squier, and Bardach²⁷ had previously noted that anticontractile agents instilled into the tissues surrounding an expander enhanced the rate and extent of skin expansion, presumably through relaxation or inactivation of contractile fibroblasts in the periprosthetic capsule.

Beauchenne²⁸ detected higher levels of hydroxyproline and a net accumulation of collagen in expanded skin compared with normal skin. Johnson, Kernahan, and Bauer²⁹ likewise noted increased total collagen content in expanded skin, which resulted in a theoretical net gain in the dermal layer as well as in the epidermal layer. Knight and coworkers³⁰ confirmed increased collagen content in expanded dermis of pigs, and speculated that it could be due to tensile factors during expansion which stimulated biosynthetic activity or mitosis of fibroblasts.

Timmenga and coworkers³¹ noted thickened dermal collagen bundles and collagen fibrils that were loosely packed in both expanded and sham-operated skin. The mechanism of action was thought to be the normal process of wound healing in addition to a delay phenomenon. Wickman, Heden, and Jurell³² report adrenergic supersensitivity in expanded pig skin, suggesting sympathetic denervation as a result of expansion.

Pasyk, Austad, and Cherry³³ note formation of a capsule around every silicone expander. The capsule has four histological zones.

- Inner zone—adjacent to the expander. Contains fibrin-like filaments and a cellular layer with macrophages.
- Central zone—next to the inner zone. Contains elongated fibroblasts and myofibroblasts oriented parallel to the surface of the implant.
- Transitional zone—on the outside of the central zone. Has loose bundles of collagen fibers.
- Outer zone—most superficial layer. Has established vessels loosely interspersed with collagen fibers.

Once an expander is removed, the surrounding fibrous capsule rapidly thins. Maturri and colleagues³⁴ biopsied previously expanded skin at least 1 year after expander removal and found normal-appearing epidermis with normal mitotic activity. The dermis showed only minimal degree of elastosis and zonal

fragmentation of elastic fibers, while the hypodermis, which was in contact with the expander capsule, did not manifest accentuated fibrosis.

Expansion of the human scalp shortens the telogen phase of hair follicles by activating and accelerating epidermal mitosis.³⁵

The histologic effect of expansion on muscle was examined during breast reconstruction with tissue expanders. The underlying pectoralis major muscle showed considerable ultrastructural damage under light and electron microscopy.³⁶

Tissue expansion of irradiated pig skin shows no further histopathological changes beyond those caused by irradiation and is indistinguishable from nonexpanded irradiated skin in the porcine model.^{37,38} Radiation did reduce the overall area of expanded skin by 23% in one study.³⁸ Working on a rabbit model, Goodman and associates³⁹ note increased epidermal thickness but no dermal or capsular alterations in irradiated skin postexpansion.

BLOOD SUPPLY OF EXPANDED SKIN

The histologic changes evident in expanded skin lend support to the concept that skin expansion is a form of delay. Cherry, Pasyk and others⁴⁰ compared the survival of expanded and delayed flaps with acutely raised random-pattern skin flaps in pigs. Expanded flaps showed a 117% increase in surviving length over unexpanded skin flaps. Delayed flaps showed a 73% increase over the controls. No significant difference was noted between expanded and delayed skin flaps. Specimen angiograms of expanded skin showed evidence of increased vascularity compared with control skin. The authors recommended including the expander capsule in the flap at the time of transfer for its contribution to the blood supply, and postulated that mechanical forces are in some way related to the increased vascularity.

In a similar study, Sasaki and Pang⁴¹ focused on the viability and capillary blood flow of expanded and delayed skin flaps. Compared with acutely raised random-pattern flaps, both expanded and delayed skin exhibited increased total capillary blood flow, and this increase paralleled flap survival. The survival length of random flaps in skin overlying tissue expanders was also increased, whether the expander was inflated or not.

Saxby⁴² also reported 150% greater surviving lengths of expanded flaps over acutely raised, nondelayed flaps and 50% greater surviving lengths than nonexpanded, delayed flaps. Angiograms of the flap specimens revealed increased caliber of the axial vessels in the expanded flaps.

Wickman and associates³² found evidence of increased superficial blood flow in expanded skin by laser Doppler flowmetry and venous outflow measurements, but no significant difference in total blood flow between flaps raised in expanded and nonexpanded skin.

Babovic et al⁴³ studied the effects of tissue expansion on ischemia in free flaps. Compared with the control and sham groups, preexpanded skin flaps demonstrated a statistically significant increase (700%) in perfusion as measured by fluorescein. The increase in flap circulation induced by the expansion facilitated an increase in flap tolerance to secondary ischemia.

EXTENT OF EXPANSION

Several authors have investigated the origin of the expanded tissue. Austad^{12,16} documented a true tissue dividend from expansion that was thought to result from the increased mitotic activity of the stressed tissues. Vander Kolk and others⁴⁴ reported a 32% increase in midhorizontal length and 44% increase in midvertical length of expanded porcine skin. After flap elevation and inset, the overall increase in surface area available for coverage was 30%. Three months after surgery there was a slight decrease in area which was not statistically significant.

RATE OF EXPANSION

Traditionally, the expansion process begins 2 to 3 weeks after implantation of the expander and continues at weekly intervals until the desired inflation is achieved. The skin adapts to stress in two ways. First, in the event of immediate tissue expansion, mechanical stretching changes the elasticity and alignment of collagen by a process called *creep*. Creep is the "time-dependent plastic deformation of any material or tissue in response to constant stress."⁴⁵ Second, the process of *stress-relaxation* occurs where, over a period of time when skin is stretched to a given constant length, the force required to maintain it is gradually decreased.²⁴ As summarized

by Baker,⁴ the physiologic changes in skin during creep include the following:

- dehydration of tissue
- microfragmentation of elastic fibers
- increasingly parallel alignment of randomly positioned collagen fibers
- migration of tissue in the direction of the force vector

Baker⁴ expands Gibson's definition of *cyclic loading* to mean stretching followed by relaxation of expanded tissue, as opposed to continuous expansion. It appears that cyclic loading is the most effective method of recruiting extra tissue. Skin creep alone does not account for all the extra skin during serial expansion, and factors such as recruitment, tissue compression/thinning, and new growth also play a role.

In 1987 Sasaki⁴⁶ described intraoperative sustained limited expansion (ISLE) for immediate reconstruction. The author later reported intraoperative expansion in closure of small skin defects on an emergency basis.⁴⁷ He mentions disadvantages of the slow expansion method, namely gradual inflation over many weeks and months; the risk of infection and implant exposure from the protracted presence of the expander, particularly in poorly vascularized areas; and the cosmetic and functional deformities of buried expanders and valves. Sasaki states that these shortcomings of slow expansion are eliminated by the intraoperative expansion technique.

Siegert et al⁴⁵ evaluated intermittent intraoperative short-term tissue expansion in dogs and in 30 patients with severe microtia. Cycled expansions yielded maximal increase in length of 15% to 20%. The authors mention mechanisms that lead to an increase in skin length (Fig 1)—elasticity, interstitial displacement of fluids, creep, and genuine growth—yet fail to credit any of these specifically for their findings. Instead, they attribute the mechanism of expansion to another, undefined form of subcutaneous mobilization.

Shapiro⁴⁸ combines acute cycled expansions with rectangular skin flaps and notes a decrease in wound closing tension compared with simple flap undermining. Nevertheless, the author states that "undermining must still be considered the most important element in reducing wound closing tension."

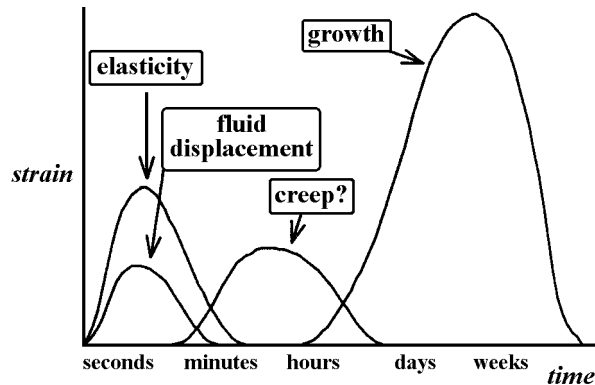


Fig 1. Skin expansion mechanisms. (Reprinted with permission from Siegert R, Weerda H, Hoffmann S, Mohadjer C: *Clinical and experimental evaluation of intermittent intraoperative short-term expansion.* *Plast Reconstr Surg* 92:248, 1993.)

Wee, Logan, and Mustoe⁴⁹ describe a continuous infusion device that maintains a constant expander pressure and shortens the time to full expansion by two-thirds. The authors compared the efficacy of continuous versus intraoperative tissue expansion in a pig model, and find three times more tissue gain with the former technique.

Futran⁵⁰ discusses the clinical applications of the Sure-Closure™ skin-stretching device originally introduced by Hirshowitz and colleagues.⁵¹ The device is said to harness the viscoelastic properties of the skin by applying incremental traction to allow the skin to rapidly stretch and extend while minimizing its tendency to recoil.

Wickman and colleagues⁵² measured mechanical properties of the skin during rapid and slow tissue expansion for breast reconstruction. Distensibility lessened during expansion, increased after the expander was replaced by a permanent implant, and decreased thereafter. Elasticity did not change significantly and neither did hysteresis (a measure of the skin turgor and plasticity). In summary, there were minimal differences in skin properties between rapidly and slowly expanded patients.

APPLICATIONS OF EXPANDED SKIN

The main advantages of tissue expansion in reconstructive surgery are good color and texture match of the skin used for coverage, preservation of sensation and hair, absence of a donor defect, simplicity, and reliability. To date expanders have been used to good effect in the head and neck, the extremities, the trunk, and for breast reconstruction. Expanders are generally contraindicated in areas of poorly vascularized tissue, where there is localized infection, or if there is a higher-than-average risk of recurrent cancer. Fisher and Hammond⁵³ review the literature of expanders combined with flaps for breast reconstruction.

Most reports of reconstruction by tissue expansion imply movement of tissue as advancement flaps. Joss and coworkers⁵⁴ note that advancement flap reconstruction wastes tissue (in dog-ears) at either end of the defect, and instead recommend transposing the expanded tissue into the wound bed along a 90° arc (Fig 2). The expander can be of any shape but should be twice as wide as the defect to be covered.

Wilmhurst and Sharpe⁵⁵ insert tissue expanders immediately after resection of malignant skin lesions to complete the reconstruction in two operations. The excisional bed is temporarily covered by a skin graft.

Austad⁵⁶ advocates against tissue expansion in acute injuries because of the risk of contamination and possible inability to obtain rational informed consent on an emergency basis. He reminds us that tissue expansion results in a distortion of body image that some patients are unable to tolerate.

COMPLICATIONS

Potential complications of tissue expansion include infection, hematoma, seroma, expander extrusion, implant failure, skin necrosis, pain, and neurapraxia. These problems undoubtedly delay the reconstruc-

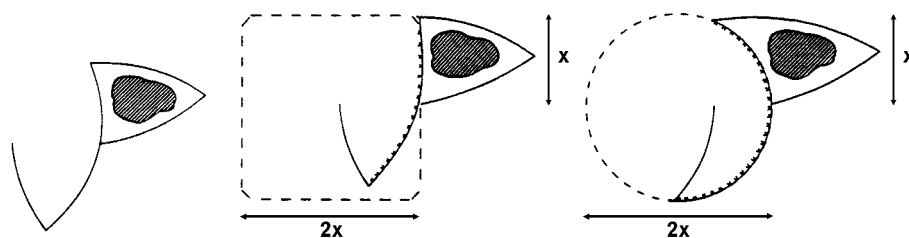


Fig 2. Markings for transposition flap and expander placed beneath flap and beyond. The shape of the expander is irrelevant. (Reprinted with permission from Joss GS, Zoltie N, Chapman P: *Tissue expansion technique and the transposition flap.* *Br J Plast Surg* 43:328, 1990.)

tive process and may necessitate implant removal, but do not signal a catastrophe with dire consequences to the patient. Austad⁵⁶ notes a remarkable absence of disasters in a survey of more than 50,000 tissue expansion procedures, and points out that the overall incidence of complications associated with tissue expansion has decreased as surgeons have become more knowledgeable and experienced in the routine use of expanders. Austad recounts four cases of partial flap necrosis after the expander had been removed and the flap advanced over the defect, and attributes the cyanosis to epinephrine in the local anesthetic solution known to be detrimental to the survival of delayed—hence expanded—flaps.⁵⁷

Manders and colleagues⁵⁸ report a 24% incidence of major complications that delayed or compromised the outcome of their cases of tissue expansion. Minor complications were noted in 17% and included pain on expansion, seroma, and widening of scars. Argenta and associates¹⁸ also noted a 24% complication rate early in their series, but this subsequently fell to 7%. Infection is usually reported in 1% of cases, and only in patients with predisposing factors. The most frequent cause of exposure is an insufficient pocket at the initial procedure that forces the prosthesis against the suture line. Sharp edges or irregular folds in the prosthesis should also be smoothed out or risk thinning of the shell from friction and perhaps implant exposure. Argenta recommends waiting for 2 weeks after implantation of the expander before beginning inflation.

Zoltie and associates⁵⁹ review their experience with non-scalp, non-breast tissue expansion in 56 patients, and report an overall failure of 12%. Failures were most common in the arm (31%) and rarest in the leg (0%). They credit their low failure rate to an expander size twice as wide as the defect, slow rate of inflation, aggressive management of any complication, and use of transposition flaps.

Youm and coworkers⁶⁰ reviewed retrospectively 34 tissue expanders placed in 30 patients at a New York City public hospital over a 7-year period. Complications occurred in 22 of 34 expanders (65%), necessitating removal in 13 (38%). Only 12 of 34 expanders (35%) were free of complications.

The pain associated with tissue expansion tends to be mild and of short duration, although an occa-

sional patient may complain of disabling pain. Intraluminal instillation of lidocaine has been suggested to relieve pain during expansion,⁶¹ but Sinow and Cunningham⁶² report no difference in pain after expansion between patients receiving lidocaine analgesia and placebo.

McGuire and Caffee⁶³ note that the rate of diffusion of lidocaine through an expander membrane depends on the pH of the solution. Only by adding sodium bicarbonate to commercially available lidocaine to raise its pH to 8.0 will the anesthetic diffuse at a sufficient rate to provide analgesia during expansion. Derby and colleagues⁶⁴ similarly conclude that this technique of lidocaine delivery by diffusion across a tissue expander shell “is unlikely to provide significant salutary benefit, and advise against it because of the potential for progressive lidocaine accumulation” that could lead to lidocaine overdose in the event of implant failure.

Infrequent reports of erosion and deformation of bone underlying an expander have appeared in the literature, specifically rib concavity with thoracic skin expansion and calvarial deformity and remodeling with scalp expansion in children.⁶⁵ Paletta⁶⁶ describes rupture of an expander placed in the scalp of a child caused by erosion of the outer table of the skull and bone spur formation from pressure by the expander.

CONCLUSIONS

As summarized by Baker,⁴ tissue expansion is associated with

- improved flap survival
- increase in vascularity to the skin or capsule
- probable enhancement of the blood supply of rapidly expanded skin
- creation of additional new skin
- thinning of the dermis and subcutaneous tissue and corresponding decrease in tensile strength
- larger surface area gains with prolonged expansion
- normalization of the parameters to the preexpanded state when the expansion process is discontinued

BIBLIOGRAPHY

1. Cormack GC, Lamberty BGH: **The Arterial Anatomy of Skin Flaps**. London, Churchill Livingstone, 1986.
2. Menick FJ: Aesthetic refinements in use of forehead for nasal reconstruction: the paramedian forehead flap. *Clin Plast Surg* 17:4, 1990.
3. McDowell F, Valone JA, Brown JB: Bibliography and historical note on plastic surgery of the nose. *Plast Reconstr Surg* 10:149, 1952.
4. Lamberty BGH, Cormack GC: Progress in flap surgery: greater anatomical understanding and increased sophistication in application. *World J Surg* 14:776, 1990.
5. Song YG, Chen GZ, Song YL: The free thigh flap: a new free flap concept based on the septocutaneous artery. *Br J Plast Surg* 37:149, 1984.
6. Koshima I, Soeda S: Inferior epigastric artery skin flaps without rectus abdominis muscle. *Br J Plast Surg* 42:645, 1989.
7. Allen R, Treece P: Deep inferior epigastric perforator flap for breast reconstruction. *Ann Plast Surg* 32:32, 1994.
8. Blondeel PN, Boeckx WD: Refinements in free flap breast reconstruction: the free bilateral deep inferior epigastric perforator flap anastomosed to the internal mammary artery. *Br J Plast Surg* 47:495, 1994.
9. Angrigiani C, Grilli D, Siegert I: Latissimus dorsi musculocutaneous flap without muscle. *Plast Reconstr Surg* 96:1608, 1995.
10. Allen R, Tucker C: Superior gluteal artery perforator free flap for breast reconstruction. *Plast Reconstr Surg* 95:1207, 1995.
11. Koshima I, Nanba Y, Takahashi Y, et al: Future of supramicrosurgery as it relates to breast reconstruction: free paraumbilical perforator adiposal flap. *Sem Plast Surg* 16:93, 2002.
12. Koshima I, Inagawa K, Urushibara K, Moriguchi T: Paraumbilical perforator flap without deep inferior epigastric vessels. *Plast Reconstr Surg* 102:1052, 1998.
13. Koshima I, Inagawa K, Yamamoto M, Moriguchi T: New microsurgical breast reconstruction using free paraumbilical perforator adiposal flaps. *Plast Reconstr Surg* 106:61, 2000.
14. Kimura N: A microdissected thin tensor fascia latae perforator flap. *Plast Reconstr Surg* 109:69, 2002.
15. Hallock GG: Discussion of "A microdissected thin tensor fascia latae perforator flap," by N Kimura. *Plast Reconstr Surg* 109:78, 2002.
16. Hyakusoku H, Gao JH: The "super-thin" flap. *Br J Plast Surg* 47:457, 1994.
17. Hyakusoku H, Pennington DG, Gao JH: Microvascular augmentation of the super-thin occipito-cervico-dorsal flap. *Br J Plast Surg* 47:465, 1994.
18. Koshima I, Moriguchi T, Fukuda H, et al: Free, thinned, paraumbilical perforator-based flaps. *J Reconstr Microsurg* 7:313, 1991.
19. Kimura N, Satoh K: Consideration of a thin flap as an entity and clinical applications of the thin anterolateral thigh flap. *Plast Reconstr Surg* 97:985, 1996.
20. Taylor GI, Palmer JH: The vascular territories (angiosomes) of the body—Experimental study and clinical applications. *Br J Plast Surg* 40:113, 1987.
21. Wei FC, Celik N: Perforator flap entity. *Clin Plast Surg* 30:325, 2003.
22. Asko-Seljavaara S: Free style free flaps (abstract). *Seventh Congress of the International Society of Reconstructive Microsurgery, New York, 1983*.
23. Allen RJ, Heitmann C: Perforator flaps—The history of evolution. *Handchir Mikrochir Plast Chir* 34:216, 2002.
24. Mardini S, Tsai FC, Wei FC: The thigh as a model for free style free flaps. *Clin Plast Surg* 30:473, 2003.
25. Hallock GG: Direct and indirect perforator flaps: the history and the controversy. *Plast Reconstr Surg* 111:855, 2003.
26. Manchot C: **Die Hautarterien des Menschlichen Koerpers**. Leipzig, Bogel, 1889.
27. Seitchik MW, Kahn S: The effects of delay on the circulatory efficiency of pedicled tissue. *Plast Reconstr Surg* 33:16, 1964.
28. Spalteholz W: Die Verteilung der Blutgefasse in der Haut. *Arch Anat Physiol* 1:54, 1893.
29. Daniel RK, Kerrigan CL: Principles and Physiology of Skin Flap Surgery. In: McCarthy JG (ed), **Plastic Surgery**. Philadelphia, Saunders, 1990, Ch 9.
30. Taylor GI: The blood supply to the skin. In: Aston SJ, Beasley RW, Thorne CHM (eds), **Grabb and Smith's Plastic Surgery**, 5th ed. Philadelphia, Lippincott-Raven, 1997, Ch 5.
31. Inoue Y, Taylor GI: The angiosomes of the forearm: anatomic study and clinical applications. *Plast Reconstr Surg* 98:195, 1996.
32. Taylor GI, Pan WR: Angiosomes of the leg: anatomic study and clinical implications. *Plast Reconstr Surg* 102:599, 1998.
33. Houseman ND, Taylor GI, Pan WR: The angiosomes of the head and neck: anatomic study and clinical applications. *Plast Reconstr Surg* 105:2287, 2000.
34. McGregor AD: The angiosome—an in vivo study by fluorescein angiography. *Br J Plast Surg* 45:219, 1992.
35. Nakajima H, Fujino T, Adachi S: A new concept of vascular supply to the skin and classification of skin flaps according to their vascularization. *Ann Plast Surg* 16:1, 1986.
36. Nakajima H, Minabe T, Imanishi N: Three-dimensional analysis and classification of arteries in the skin and subcutaneous adipofascial tissue by computer graphics imaging. *Plast Reconstr Surg* 102:748, 1998.
37. Taylor GI, Caddy CM, Watterson PA, Crock JG: The venous territories (venosomes) of the human body: experimental study and clinical implications. *Plast Reconstr Surg* 86:185, 1990.
38. Zhong SZ, Wang GY, Yuan L, Xu DC: Anatomic basis of venous drainage in donor flaps. *Surg Radiol Anat* 16:349, 1994.

39. Imanishi N, Nakajima H, Aiso S: Anatomic study of the venous drainage architecture of the forearm skin and subcutaneous tissue. *Plast Reconstr Surg* 106:1287, 2000.
40. Imanishi N, Nakajima H, Aiso S: Anatomical study of the venous drainage architecture of the scapular skin and subcutaneous tissue. *Plast Reconstr Surg* 108:656, 2001.
41. Imanishi N, Nakajima H, Minabe T, et al: Venous drainage architecture of the temporal and parietal regions: anatomy of the superficial temporal artery and vein. *Plast Reconstr Surg* 109:2197, 2002.
42. Imanishi N, Nakajima H, Fukuzumi S, Aiso S: Venous drainage of the distally based lesser saphenous-sural veno-neuroadipofascial pedicled fasciocutaneous flap: a radiographic perfusion study. *Plast Reconstr Surg* 103:494, 1999.
43. Pinal FD, Taylor GI: The deep venous system and reverse flow flaps. *Br J Plast Surg* 46:652, 1993.
44. Birkbeck DP, Moy OJ: Anatomy of upper extremity skin flaps. *Hand Clin* 13(2):175, 1997.
45. Nakajima H, Imanishi N, Fukuzumi S, et al: Accompanying arteries of the cutaneous veins and cutaneous nerves in the extremities: anatomical study and a concept of the venoadipofascial and/or neuroadipofascial pedicled fasciocutaneous flap. *Plast Reconstr Surg* 102:779, 1998.
46. Nakajima H, Imanishi N, Fukuzumi S, et al: Accompanying arteries of the lesser saphenous vein and sural nerve: anatomic study and its clinical applications. *Plast Reconstr Surg* 103:104, 1999.
47. Grabb WC, Smith JW, eds: **Plastic Surgery. A Concise Guide to Clinical Practice**, 2nd Ed. Boston, Little Brown, 1973.
48. Lamberty BGH, Healy C: Flaps: physiology, principles of design, and pitfalls. In: Cohen M (ed), **Mastery of Plastic and Reconstructive Surgery**. Boston, Little, Brown, 1995.
49. Suzuki S, Matsuda K, Nishimura Y: Proposal for a new comprehensive classification of V-Y plasty and its analogues: the pros and cons of inverted versus ordinary Burow's triangle excision. *Plast Reconstr Surg* 98:1016, 1996.
50. Rohrich RJ, Zbar RIS: A simplified algorithm for the use of Z-plasty. *Plast Reconstr Surg* 103:1513, 1999.
51. Furnas DW, Fischer GW: The Z-plasty: biomechanics and mathematics. *Br J Plast Surg* 24:144, 1971.
52. Seyhan A: A V-shaped ruler to detect the largest transposable z-plasty (letter). *Plast Reconstr Surg* 101:870, 1994.
53. Jackson IT: **Local Flaps in Head and Neck Reconstruction**. St Louis, Mosby, 1985.
54. Keser A, Sensöz O, Mengi AS: Double opposing semicircular flap: a modification of opposing z-plasty for closing circular defects. *Plast Reconstr Surg* 102:1001, 1998.
55. Mendelson BC, Masson JK. Cervical and Clavicular Tubed Skin flaps. In: Strauch B, Vasconez LO, and Hall-Findlay EJ (eds), **Grabb's Encyclopedia of Flaps**. Boston, Little, Brown, 1990. Vol 1, Ch 42.
56. Goldwyn RM, Lamb DL, White WL: An experimental study of large island flaps in dogs. *Plast Reconstr Surg* 31:328, 1963.
57. Khouri RK: Avoiding free flap failure. *Clin Plast Surg* 19:773, 1992.
58. Chao JJ, Castello JR, English JM, Tittle BJ: Microsurgery: free tissue transfer and replantation. *Selected Read Plast Surg* 9(11), 2000.
59. McGregor IA, Morgan G: Axial and random pattern flaps. *Br J Plast Surg* 26:202, 1963.
60. Milton SH: Pedicled skin flaps: the fallacy of the length:width ratio. *Br J Surg* 57:502, 1970.
61. Daniel RK, Williams HB: The free transfer of skin flaps by microvascular anastomoses: an experimental study and a reappraisal. Part I: the vascular supply of the skin. *Plast Reconstr Surg* 52:16, 1973.
62. Daniel RK, Kerrigan CL: Skin flaps: an anatomical and hemodynamic approach. *Clin Plast Surg* 6:181, 1979.
63. Cormack GC, Lamberty BGH: A classification of fasciocutaneous flaps according to their patterns of vascularisation. *Br J Plast Surg* 37:80, 1984.
64. Batchelor JS, Moss ALH: The relationship between fasciocutaneous perforators and their fascial branches: an anatomic study in human cadaver lower legs. *Plast Reconstr Surg* 95:629, 1995.
65. Blondeel PN, Landuyt KV, Hamdi M, Monstrey SJ: Perforator flap terminology: Update 2002. *Clin Plast Surg* 30:343, 2003.
66. Blondeel PN, Landuyt KH, Monstrey SJ, et al: The "Gent" consensus on perforator flap terminology: preliminary definitions. *Plast Reconstr Surg* 112:1378, 2003.
67. Mathes SJ, Nahai F: **Clinical Applications of Muscle and Musculocutaneous Flaps**. St Louis, Mosby, 1982.
68. Cho B-C, Lee J-H, Byun J-S, Baik B-S: Clinical applications of the delayed arterialized venous flap. *Ann Plast Surg* 39:145, 1997.
69. Koshima I, Fukuda H, Yamamoto H, et al: Free anterolateral thigh flaps for reconstruction of head and neck defects. *Plast Reconstr Surg* 92:421, 1993.
70. Wei F-C, Jain V, Suominen S, Chen H-C: Confusion among perforator flaps: what is a true perforator flap? *Plast Reconstr Surg* 107:874, 2001.
71. Wei F-C, Jain V, Celik N, et al: Have we found an ideal soft-tissue flap? An experience with 672 anterolateral thigh flaps. *Plast Reconstr Surg* 109:2219, 2002.
72. Taylor GI: Discussion of "The 'Gent' consensus on perforator flap terminology: preliminary definitions", by PN Blondeel et al. *Plast Reconstr Surg* 112:1384, 2003.
73. Geddes CR, Morris SF, Neligan PC: Perforator flaps: evolution, classification, and applications. *Ann Plast Surg* 50:90, 2003.
74. Blondeel PN, Vanderstraeten GC, Monstrey SJ, et al: The donor site morbidity of free DIEP flaps and free TRAM flaps for breast reconstruction. *Br J Plast Surg* 50:322, 1997.
75. Futter CM, Webster MHC, Hagen S, Mitchell SL: A retrospective comparison of abdominal muscle strength following breast reconstruction with a free TRAM or DIEP flap. *Br J Plast Surg* 53:578, 2000.
76. Futter CM: Abdominal donor site morbidity: impact of the TRAM and DIEP flap on strength and function. *Semin Plast Surg* 16:119, 2002.
77. Kroll SS, Sharma S, Koutz C, et al: Postoperative morphine requirements of free TRAM and DIEP flaps. *Plast Reconstr Surg* 107:338, 2001.

78. Kroll SS, Reece GP, Miller MJ, et al: Comparison of cost for DIEP and free TRAM flap breast reconstructions. *Plast Reconstr Surg* 107:1413, 2001.
79. Kaplan JL, Allen RJ: Cost-based comparison between perforator flaps and TRAM flaps for breast reconstruction. *Plast Reconstr Surg* 105:943, 2000.
80. Nahabedian MY, Momen B, Galdino G, Manson PN: Breast reconstruction with the free TRAM or DIEP flap. Patient selection, choice of flap, and outcome. *Plast Reconstr Surg* 110:466, 2002.
81. Blondeel PN, Demuyneck M, Mete D, et al: Sensory nerve repair in perforator flaps for autologous breast reconstruction: sensational or senseless? *Br J Plast Surg* 52:37, 1999.
82. Chen H-C, Tang Y-B: Anterolateral thigh flap: an ideal soft tissue flap. *Clin Plast Surg* 30(3):383, 2003.
83. Kimata Y, Uchiyama K, Ebihara S, et al: Anatomic variations and technical problems of the anterolateral thigh flap: a report of 74 cases. *Plast Reconstr Surg* 102:1517, 1998.
84. Hsieh C-H, Yang C-C, Kuo Y-R, et al: Free anterolateral thigh adipofascial perforator flap. *Plast Reconstr Surg* 112:976, 2003.
85. Kuo Y-R, Jeng S-F, Kyo M-H, et al: Free anterolateral thigh flap for extremity reconstruction: clinical experience and functional assessment of donor site. *Plast Reconstr Surg* 107:1766, 2001.
86. Koshima I, Inagawa K, Urushibara K, et al: Deep inferior epigastric perforator dermal-fat or adiposal flap for correction of craniofacial contour deformities. *Plast Reconstr Surg* 106:10, 2000.
87. Marchetti C, Gessaroli M, Cipriani R, et al: Use of "perforator flaps" in skull base reconstruction after tumor resection. *Plast Reconstr Surg* 110:1303, 2002.
88. Geddes CR, Morris SF, Neligan PC: Perforator flaps: evolution, classification, and applications. *Ann Plast Surg* 50:90, 2003.
89. Craigie JE, Allen RJ, DellaCroce FJ, Sullivan SK: Autogenous breast reconstruction with the deep inferior epigastric perforator flap. *Clin Plast Surg* 30:359, 2003.
90. Hamdi M, Weiler-Mithoff EM, Webster MHC: Deep inferior epigastric perforator flap in breast reconstruction: experience with the first 50 flaps. *Plast Reconstr Surg* 103:86, 1999.
91. Kroll SS: Fat necrosis in free transverse rectus abdominis myocutaneous and deep inferior epigastric perforator flaps. *Plast Reconstr Surg* 106:576, 2000.
92. Kimata Y, Uchiyama K, Sekido M, et al: Anterolateral thigh flap for abdominal wall reconstruction. *Plast Reconstr Surg* 103:1191, 1999.
93. Celik N, Wei F-C, Lin C-H, et al: Technique and strategy in anterolateral thigh perforator flap surgery, based on an analysis of 15 complete and partial failures in 439 cases. *Plast Reconstr Surg* 109:2211, 2002.
94. Taylor GI: The angiosomes of the body and their supply to perforator flaps. *Clin Plast Surg* 30:331, 2003.
95. Ponten B: The fasciocutaneous flap: its use in soft tissue defects of the lower leg. *Br J Plast Surg* 34:215, 1981.
96. Haertsch PA: The surgical plane in the leg. *Br J Plast Surg* 35:464, 1981.
97. Barclay TC, Cardoso E, Sharpe DT, Crockett DJ: Repair of lower leg injuries with fasciocutaneous flaps. *Br J Plast Surg* 35:127, 1982.
98. Tolhurst DE, Haeseker B: Fasciocutaneous flaps in the axillary region. *Br J Plast Surg* 35:430, 1982.
99. Tolhurst DE, Haeseker B, Zeeman RJ: The development of the fasciocutaneous flap and its clinical applications. *Plast Reconstr Surg* 71:597, 1983.
100. Cormack GC, Lamberty BGH: Fasciocutaneous vessels. their distribution on the trunk and limbs, and their clinical application in tissue transfer. *Anat Clin* 6:121, 1984.
101. Cormack GC, Lamberty BGH: Fasciocutaneous vessels in the upper arm: application to the design of new fasciocutaneous flaps. *Plast Reconstr Surg* 74:244, 1984.
102. Carriquiry C, Costa MA, Vasconez LO: An anatomic study of the septocutaneous vessels of the leg. *Plast Reconstr Surg* 76:354, 1985.
103. Schafer K: Das subcutane Gefäßsystem (untere Extremität) Mikropaparatorische Untersuchungen. *Gegenbaurs Morphol Jahrb (Leipzig)* 121:492, 1975.
104. Gumener R, Montandon D, Marty F, Zbrodowski A: The subcutaneous tissue flap and the misconception of fasciocutaneous flaps. *Scand J Plast Reconstr Surg* 20:61, 1986.
105. Masquelet AC, Romana MC, Wolf G: Skin island flaps supplied by the vascular axis of the sensitive superficial nerves: anatomic study and clinical experience in the leg. *Plast Reconstr Surg* 89:1115, 1992.
106. Nakajima H, Imanishi N, Fukuzumi S, et al: Accompanying arteries of the cutaneous veins and cutaneous nerves in the extremities: anatomical study and a concept of the venoadipofascial and/or neuroadipofascial pedicled fasciocutaneous flap. *Plast Reconstr Surg* 102:779, 1998.
107. Imanishi N, Nakajima H, Fukuzumi S, Aiso S: Venous drainage of the distally based lesser saphenous-sural veno-neuroadipofascial pedicled fasciocutaneous flap: a radiographic perfusion study. *Plast Reconstr Surg* 103:494, 1999.
108. Fraccalvieri M, Verna G, Dolcet M, et al: The distally based superficial sural flap: our experience in reconstructing the lower leg and foot. *Ann Plast Surg* 45:132, 2000.
109. Baumeister SP, Spierer R, Erdmann D, et al: A realistic complication analysis of 70 sural artery flaps in a multimorbid patient group. *Plast Reconstr Surg* 112:129, 2003.
110. Cavadas PC: Reversed saphenous neurocutaneous island flap: clinical experience. *Plast Reconstr Surg* 99:1940, 1997.
111. Cavadas PC: Reversed saphenous neurocutaneous island flap: clinical experience and evolution to the posterior tibial perforator-saphenous subcutaneous flap. *Plast Reconstr Surg* 111:837, 2003.
112. Chen S-L, Chen T-M, Chou T-D, et al: The distally based lesser saphenous venofasciocutaneous flap for ankle and heel reconstruction. *Plast Reconstr Surg* 110:1664, 2002.
113. Nakayama Y, Soeda S, Kasai Y: Flaps nourished by arterial inflow through the venous system: an experimental investigation. *Plast Reconstr Surg* 67:328, 1981.
114. Ji SY, Chia SL, Cheng HH: Free transplantation of venous network pattern skin flap: an experimental study in rabbits. *Microsurgery* 5:151, 1984.

115. Nichter LS, Haines PC: Arterialized venous perfusion of composite tissue. *Am J Surg* 150:191, 1985.
116. Germann GK, et al: Effect of arteriovenous flow reversal on blood flow and metabolism in a skin flap. *Plast Reconstr Surg* 79:375, 1987.
117. Baek SM, Weinberg H, Song Y, et al: Experimental studies in the survival of venous island flaps without arterial inflow. *Plast Reconstr Surg* 75:88, 1985.
118. Chavoin JP, Rouge D, Bachaud M, et al: Island flaps with an exclusively venous pedicle: a report of eleven cases and a preliminary haemodynamic study. *Br J Plast Surg* 40:149, 1987.
119. Thatte RL, Thatte MR: A study of the saphenous venous island flap in the dog without arterial inflow using a non-biological conduit across a part of the length of the vein. *Br J Plast Surg* 40:11, 1987.
120. Amarante J, Costa H, Reis J, et al: Venous skin flaps: an experimental study and report of two clinical distal island flaps. *Br J Plast Surg* 41:132, 1988.
121. Lenoble E, Foucher G, Voisin MC, et al: Observations on experimental flow-through venous flaps. *Br J Plast Surg* 46:378, 1993.
122. Thatte MR, Thatte RL: Venous flaps. *Plast Reconstr Surg* 91(4):747, 1993.
123. Yuan R, Shan Y, Zhu S: Circulating mechanism of the "pure" venous flap: direct observation of microcirculation. *J Reconstr Microsurg* 14(3):147-152, 1998.
124. Pittet B, Chang P, Cederna P, et al: The role of neovascularization in the survival of an arterialized venous flap. *Plast Reconstr Surg* 97:621, 1996.
125. Noreldin AA, Fukuta K, Jackson IT: Role of perivenous areolar tissue in the viability of venous flaps: an experimental study on the inferior epigastric venous flap of the rat. *Br J Plast Surg* 45:18, 1992.
126. Shalaby HA, Saad MA: The venous island flap: is it purely venous? *Br J Plast Surg* 46:285, 1993.
127. Xiu Z-F, Chen Z-J: The microcirculation and survival of experimental flow-through venous flaps. *Br J Plast Surg* 49:41, 1996.
128. Inada Y, Toshiyuki D, Fukui A, et al: An experimental study of the flow-through venous flap: investigation of the width and area of survival with one flow-through vein preserved. *J Reconstr Microsurg* 8:297, 1992.
129. Inada Y, Fukui A, Tamai S, Mizumoto S: The arterIALIZED venous flap: experimental studies and a clinical case. *Br J Plast Surg* 46:61, 1993.
130. Lee WPA: Discussion of "Arterialized venous flap for treating multiple skin defects of the hand", by G Inoue and K Suzuki. *Plast Reconstr Surg* 91:303, 1993.
131. Yilmaz M, Menderes A, Karaca C, Barutcu A: Free arterIALIZED venous forearm flap. *Ann Plast Surg* 34:88, 1995.
132. Moshammer HET, Schwarzl FX, Haas FM, et al: Retrograde arterIALIZED venous flap: an experimental study. *Microsurgery* 23:130, 2003.
133. Krishnan KG: The venous flaps: an experimental study of the microvascular architecture, the area of perfusion and their correlation. *Br J Plast Surg* 55:340, 2002.
134. Ueda K, Harada T, Nagasaka S, et al: An experimental study of delay of flow-through venous flaps. *Br J Plast Surg* 46:56, 1993.
135. Ueda K, Tajima S, Tanaka Y, et al: Experimental study of delay of venous island flaps. *Ann Plast Surg* 33:519, 1994.
136. Wungcharoen B, Pradidarcheep W, Santidhananon Y, Chongchet V: Pre-arterialisation of the arterIALIZED venous flap: an experimental study in the rat. *Br J Plast Surg* 54:621, 2001.
137. Wungcharoen B, Santidhananon Y, Chongchet V: Pre-arterialisation of an arterIALIZED venous flap: clinical cases. *Br J Plast Surg* 54:112, 2001.
138. Imanishi N, Nakajima H, Aiso S: A radiographic perfusion study of the cephalic venous flap. *Plast Reconstr Surg* 97:408, 1996.
139. Chow SP, Chen DZ, Gu YD: A comparison of arterial and venous flaps. *J Hand Surg* 17B:359, 1992.
140. Ueda K, Harada T, Nagasaka S, et al: An experimental study of delay of flow-through venous flaps. *Br J Plast Surg* 46:56, 1993.
141. Wolff KD, Telzrow T, Rudolph KH, et al: Isotope perfusion and infrared thermography of arterIALIZED, venous flow-through, and pedicled venous flaps. *Br J Plast Surg* 48:61, 1995.
142. Inoue G, Suzuki K: ArterIALIZED venous flap for treating multiple skin defects of the hand. *Plast Reconstr Surg* 91:299, 1993.
143. Koshima I, Soeda S, Nakayama Y, et al: An arterIALIZED venous flap using the long saphenous vein. *Br J Plast Surg* 44:23, 1991.
144. Galumbeck MA, Freeman BG: ArterIALIZED venous flaps for reconstructing soft-tissue defects of the extremities. *Plast Reconstr Surg* 94:997, 1994.
145. De Lorenzi F, van der Hulst RRWJ, den Dunnen WFA, et al: ArterIALIZED venous free flaps for soft-tissue reconstruction of digits: a 40-case series. *J Reconstr Microsurg* 18:569, 2002.
146. Nishi G, et al: ArterIALIZED venous skin flaps for the injured finger. *J Reconstr Microsurg* 5:357, 1989.
147. Chen HC, Tang YB, Noordhoff MS: Four types of venous flaps for wound coverage: a clinical appraisal. *J Trauma* 31(9):1286, 1991.
148. Chia SL, Cheng HH, Mao L: Free transplantation of venous network pattern skin flap. *Plast Reconstr Surg* 82:892, 1988.
149. Stewart DH, Puckett CL: Is reversed venous flow safe in free-flap transfer? A dilemma with the radial forearm flap. *Plast Reconstr Surg* 89:237, 1992.
150. Nakashima H: Experiences with the venous skin graft. *Jpn J Plast Reconstr Surg* 32:11, 1989.
151. Yilmaz M, Menderes A, Karaca C, Barutcu A: Free arterIALIZED venous forearm flap. *Ann Plast Surg* 34:88, 1995.
152. Klein C, Kovacs A, Stuckensen T: Free arterIALIZED venous forearm flaps for intraoral reconstruction. *Br J Plast Surg* 50:166, 1997.
153. Kovacs AF: Comparison of two types of arterIALIZED venous forearm flaps for oral reconstruction and proposal of a reliable procedure. *J Craniomaxillofac Surg* 26:249, 1998.
154. Ger R: **Current Problems in Surgery**. Chicago, Year Book, 1972.
155. Ger R: Muscle transposition for treatment and prevention of chronic post-traumatic osteomyelitis of the tibia. *J Bone Joint Surg* 58A:784, 1977.

156. Tansini I: Sopra il mio nuovo processo di amputazione della mammella. *Gaz Med Ital* 57:141, 1906.
157. Owens N: A compound neck pedicle designed for repair of massive facial defects: formation, development, and application. *Plast Reconstr Surg* 15:369, 1955.
158. Hueston JT, McConchie IH: A compound pectoral flap. *Aust N Z J Surg* 38:61, 1968.
159. DesPrez JD, Kiehn CL, Eckstein W: Closure of large meningocele defects by composite skin-muscle flaps. *Plast Reconstr Surg* 47:234, 1971.
160. Orticochea M: Musculo-cutaneous flap method: immediate and heroic substitute for the method of delay. *Br J Plast Surg* 25:106, 1972.
161. Orticochea M: New method of total reconstruction of the penis. *Br J Plast Surg* 25:347, 1972.
162. McCraw JB, Dibbell DG: Experimental definition of independent myocutaneous vascular territories. *Plast Reconstr Surg* 60:212, 1977.
163. McCraw JB, Dibbell DG, Carraway JH: Clinical definition of independent myocutaneous vascular territories. *Plast Reconstr Surg* 60:341, 1977.
164. McCraw JB: The recent history of myocutaneous flaps. *Clin Plast Surg* 7:3, 1980.
165. McCraw JB, Vasconez LO: Musculocutaneous flaps: principles. *Clin Plast Surg* 7:9, 1980.
166. Chang N, Mathes SJ: Comparison of the effect of bacterial inoculation in musculocutaneous and random-pattern flaps. *Plast Reconstr Surg* 70:1, 1982.
167. Gosain A, Chang N, Mathes S, et al: A study of the relationship between blood flow and bacterial inoculation in musculocutaneous and fasciocutaneous flaps. *Plast Reconstr Surg* 86(6):1152, 1990.
168. Calderon W, Chang N, Mathes SJ: Comparison of the effect of bacterial inoculation in musculocutaneous and fasciocutaneous flaps. *Plast Reconstr Surg* 77:785, 1986.
169. Stark WJ: The use of pedicled muscle flaps in the surgical treatment of chronic osteomyelitis resulting from compound fractures. *J Bone Joint Surg* 28:343, 1946.
170. Scully HE, Leclerc Y, Martin RD: Comparison between antibiotic irrigation and mobilization of pectoral muscle flaps in treatment of deep sternal infections. *J Thorac Cardiovasc Surg* 90:523, 1985.
171. Perler BA, Vander Kolk CA, Dufresne CR, Williams GM: Can infected prosthetic grafts be salvaged with rotational muscle flaps? *Plast Reconstr Surg* 110:30, 1991.
172. Mixer RC, Turnipseed WD, Smith DJ, et al: Rotational muscle flaps: a new technique for covering infected vascular grafts. *J Vasc Surg* 9:472, 1989.
173. Cheng H, Tang Y, Noordhoff MS, Chang C: Microvascular free muscle flaps for chronic empyema with bronchopleural fistula when the major local muscles have been divided. *Ann Plast Surg* 24:510, 1990.
174. Hammond DC, Fisher J, Meland NB: Intrathoracic free flaps. *Plast Reconstr Surg* 91:1259, 1993.
175. Perkins DJ, Lee KK, Pennington DG, Stern HS: Free flaps in the management of intrathoracic sepsis. *Br J Plast Surg* 48:546, 1995.
176. Hallock GG: Simplified nomenclature for compound flaps. *Plast Reconstr Surg* 105:1465, 2000.
177. Graham B, Dellon AL: Sensory recovery in innervated free-tissue transfers. *J Reconstr Microsurg* 11(2):157, 1995.
178. Pribaz JJ, Fine NA: Prelamination: defining the prefabricated flap - a case report and review. *Microsurgery* 15:618, 1994.
179. Orticochea M: A new method for total reconstruction of the nose: the ears as donor areas. *Br J Plast Surg* 24:225, 1971.
180. Washio H: An intestinal conduit for free transplantation of other tissues. *Plast Reconstr Surg* 48:48, 1971.
181. Khouri RK, Upton J, Shaw WW: Prefabrication of composite free flaps through staged microvascular transfer: an experimental and clinical study. *Plast Reconstr Surg* 87(1):108, 1991.
182. Khouri RK, Upton J, Shaw WW: Principles of flap prefabrication. *Clin Plast Surg* 19(4):763, 1992.
183. Barton FE: Aesthetic aspects of nasal reconstruction. *Clin Plast Surg* 15:155, 1988.
184. Yajima H, Tamai S, Ishida H, Kisanuki O: Prefabricated vascularized periosteal grafts using fascial flap transfers. *J Reconstr Microsurg* 11(3):201, 1995.
185. Khouri RK, Ozbek MR, Hruza GJ, Young VL: Facial reconstruction with prefabricated induced expanded (PIE) supraclavicular skin flaps. *Plast Reconstr Surg* 95(6):1007, 1995.
186. Homma KI, Sugihara T, Yoshida T, Ohura T: Fascia-vascularized vs. muscle-vascularized prefabricated flaps using tissue expanders: an experimental study in a rat model. *J Reconstr Microsurg* 11(3):221, 1995.
187. Maitz PKM, Pribaz JJ, Duffy FJ, Hergrueter CA: The value of the delay phenomenon in flap prefabrication: an experimental study in rabbits. *Br J Plast Surg* 47:149, 1994.
188. Komuro Y, Takato T, Yamada A, Yonehara Y: Experimental study of prefabricated flaps using vein grafts. *J Reconstr Surg* 9(5):373, 1993.
189. Hickey MJ, Wilson Y, Hurley J, Morrison WA: Mode of vascularization of control and basic fibroblast growth factor-stimulated prefabricated skin flaps. *Plast Reconstr Surg* 101:1296, 1998.
190. Kostakođlu N, Manek S, Green CJ: The development of neovascularisation in flap prefabrication with vascular implantation: an experimental study. *Br J Plast Surg* 50:428, 1997.
191. Maitz PKM, Pribaz JJ, Hergrueter CA: Manipulating prefabricated flaps: an experimental study examining flap viability. *Microsurgery* 15:624, 1994.
192. Kim KZ, Thompson DH, George TF, et al: Effect of anemia on survival of myocutaneous flaps in the pig. *Otolaryngol Head Neck Surg* 111:509, 1994.
193. Burnstock G, Ralevic V: New insights into the local regulation of blood flow by perivascular nerves and endothelium. *Br J Plast Surg* 47:527, 1994.
194. Hoopes JE: Pedicle flaps—An overview. In: Krizek TJ, Hoopes JE (eds), *Symposium on Basic Science in Plastic Surgery*. St Louis, Mosby, 1976, Vol 15, Ch 28, pp 241-259.
195. Fujino T: Contribution of the axial and perforator vasculature to circulation in flaps. *Plast Reconstr Surg* 39:125, 1967.

196. Tsuzuki K, Yanai A, Tange I, Bandoh Y: The influence of congestion and ischemia on survival of an experimental vascular pedicle island flap. *Plast Reconstr Surg* 84:789, 1989.
197. Angel MF, Mellow CG, Knight KR, O'Brien BM: Secondary ischemia time in rodents: contrasting complete pedicle interruption with venous obstruction. *Plast Reconstr Surg* 85:789, 1990.
198. Kerrigan CL: Skin flap failure: pathophysiology. *Plast Reconstr Surg* 72:766, 1983.
199. Kerrigan CL, Daniel RK: Skin flap research: a candid view. *Ann Plast Surg* 13:383, 1984.
200. May JW: The no-reflow phenomenon in experimental free flaps. *Plast Reconstr Surg* 61:256, 1978.
201. Im MJ, et al: Effects of superoxide dismutase and allopurinol on the survival of acute island skin flaps. *Ann Surg* 201:357, 1985.
202. Manson PN, Anthenelli RM, Im MJ, et al: The role of oxygen-free radicals in ischemic tissue injury in island skin flaps. *Ann Surg* 198:87, 1983.
203. Manson PN, et al: Improved survival in free skin flap transfers in rats. *Surgery* 99:211, 1986.
204. Stotland MA, Kerrigan CL: E- and L-selectin adhesion molecules in musculocutaneous flap reperfusion injury. *Plast Reconstr Surg* 99:2010, 1997.
205. Carroll WR, Esclamado RM: Ischemia/reperfusion injury in microvascular surgery. *Head Neck* 22:700, 2000.
206. Kerrigan CL, Stotland MA: Ischemia reperfusion injury: a review. *Microsurgery* 14:165, 1993.
207. Braithwaite F: Some observations on the vascular channels in tubed pedicles. *Br J Plast Surg* 4:28, 1951.
208. Braithwaite F: Preliminary observations on the vascular channels in tube pedicles. *Br J Plast Surg* 3:40, 1950.
209. Brown JB, McDowell F: **Skin Grafting**. Philadelphia, Lippincott, 1958.
210. Hynes W: The blood vessels in skin tubes and flaps. *Br J Plast Surg* 3:165, 1950.
211. Jurell G: Adrenergic nerves and the delay phenomenon. *Ann Plast Surg* 17:493, 1986.
212. German WJ, Finesilver EM, Davis JS: Establishment of circulation in tubed skin flaps; experimental study. *Arch Surg* 26:27, 1933.
213. Pang CY, Forest CR, Neligan PC: Augmentation of blood flow in delayed random skin flaps in the pig: effect of length of delay period and angiogenesis. *Plast Reconstr Surg* 78:68, 1986.
214. Serafin D, Shearin JC, Georgiade NG: The vascularization of free flaps. *Plast Reconstr Surg* 60:233, 1977.
215. Garcia PB, Nieto CS, Ortega JMR: Morphological changes in the vascularisation of delayed flaps in rabbits. *Br J Plast Surg* 44:285, 1991.
216. Jonsson K, Hunt TK, Brennan SS, Mathes SJ: Tissue oxygen measurements in delayed skin flaps: a reconsideration of the mechanisms of the delay phenomenon. *Plast Reconstr Surg* 82:328, 1988.
217. Zink JR, Syed SA, Zahir K, et al: Transferring vascular territories from one axial pattern flap to another: a comparison of delay procedures. *Ann Plast Surg* 38:385, 1997.
218. Park SS, Rodeheaver GT, Levine PA: Role of ischemic gradient in neovascularization of interpolated skin flaps. *Arch Otolaryngol Head Neck Surg* 122:886, 1996.
219. Lopez JLA, Nieto CS, Garcia PB, Ortega JMR: Evaluation of angiogenesis in delayed skin flaps using a monoclonal antibody for the vascular endothelium. *Br J Plast Surg* 48:479, 1995.
220. Callegari PR, Taylor GI, Caddy CM, Minabe T: An anatomic review of the delay phenomenon: I. Experimental studies. *Plast Reconstr Surg* 89:397, 1992.
221. Barker JH, van Aalst VC, Keelen PC, et al: Vascular delay in skeletal muscle: a model for microcirculatory studies. *Plast Reconstr Surg* 100:665, 1997.
222. Dhar SC, Taylor GI: The delay phenomenon: the story unfolds. *Plast Reconstr Surg* 104:2079, 1999.
223. Ribuffo D, Muratori L, Antoniadou K, et al: A hemodynamic approach to clinical results in the TRAM flap after selective delay. *Plast Reconstr Surg* 99:1706, 1997.
224. Restifo RJ, Syed SA, Ward BA, et al: Surgical delay in TRAM flap breast reconstruction: a comparison of 7- and 14-day delay periods. *Ann Plast Surg* 38:330, 1997.
225. Stark GB, Hong C, Futrell JW: Enhanced neovascularization of rat tubed pedicle flaps with low perfusion of the wound margin. *Plast Reconstr Surg* 80:814, 1987.
226. Velander E: Vascular changes in tubed pedicles: an animal experimental study. *Acta Chir Scand* 322(Suppl):1, 1964.
227. Hoffmeister FS: Studies on timing of tissue transfer in reconstructive surgery: effect of delay on circulation in flaps. *Plast Reconstr Surg* 19:283, 1957.
228. Black MJM, Chait L, O'Brien BM, et al: How soon may the axial vessels of a surviving free flap be safely ligated: a study in pigs. *Br J Plast Surg* 31:295, 1978.
229. Gatti JE, LaRossa D, Brousseau DA, Silverman DG: Assessment of neovascularization and timing of flap division. *Plast Reconstr Surg* 73:396, 1984.
230. Hauser WH, et al: Determination of the vascular status of pedicle skin grafts by radioactive tracer studies. *Surg Gynecol Obstet* 112:625, 1961.
231. Sasaki A, Fukuda O, Soeda S: Attempts to increase the surviving length in skin flaps by a moist environment. *Plast Reconstr Surg* 64:526, 1979.
232. McGrath MH: How topical dressings salvage "questionable" flaps: experimental study. *Plast Reconstr Surg* 67:653, 1981.
233. Awwad AM, White RJ, Webster MHC, Vance JP: The effect of temperature on blood flow in island and free skin flaps: an experimental study. *Br J Plast Surg* 36:373, 1983.
234. Hussl H, Guy RJ, Eriksson E, Russell RC: Effect of temperature on blood flow and metabolism in a neurovascular island skin flap. *Ann Plast Surg* 17:73, 1986.
235. Mounsey RA, Pang CY, Forrest C: Preconditioning: a new technique for improved muscle flap survival. *Otolaryngol Head Neck Surg* 107(4):549, 1992.
236. Zahir KS, Syed SA, Zink JR, et al: Ischemic preconditioning improves the survival of skin and myocutaneous flaps in a rat model. *Plast Reconstr Surg* 102:140, 1998.
237. Rees R, Punch J, Shakeen K, et al: The stress response in skin: the role of neutrophil products in preconditioning. *Plast Reconstr Surg* 92:110, 1993.

238. Tan CM, Im MJ, Myers RAM, Hoopes JE: Effects of hyperbaric oxygen and hyperbaric air on the survival of island skin flaps. *Plast Reconstr Surg* 73:27, 1984.
239. Ramon Y, Abramovich A, Shupak A, et al: Effect of hyperbaric oxygen on a rat transverse rectus abdominis myocutaneous flap model. *Plast Reconstr Surg* 102:416, 1998.
240. Nemiroff PM, et al: Effects of hyperbaric oxygen and irradiation on experimental skin flaps in rats. *Otolaryngol Head Neck Surg* 93:485, 1985.
241. Quirinia A, Viidik A: The effect of hyperbaric oxygen on different phases of healing of ischaemic flap wounds and incisional wounds in skin. *Br J Plast Surg* 48:583, 1995.
242. Esclamado RM, Larrabee WF, Zel GE: Efficacy of steroids and hyperbaric oxygen on survival of dorsal skin flaps in rats. *Otolaryngol Head Neck Surg* 102(1):41, 1990.
243. Kaelin CM, et al: The effects of hyperbaric oxygen on free flaps in rats. *Arch Surg* 125:607, 1990.
244. Stewart RJ, Moore T, Bennett B, et al: Effect of free-radical scavengers and hyperbaric oxygen on random-pattern skin flaps. *Arch Surg* 129(9):982, 1994.
245. Pang CY, Forrest CR, Morris SF: Pharmacological augmentation of skin flap viability: a hypothesis to mimic the surgical delay phenomenon or a wishful thought. *Ann Plast Surg* 22:293, 1989.
246. Rothkopf DM, Chu B, Bern S, May JW: The effect of dextran on microvascular thrombosis in an experimental rabbit model. *Plast Reconstr Surg* 92(3):511, 1993.
247. Wolfort SF, Angel MF, Knight KR, et al: The beneficial effect of dextran on anastomotic patency and flap survival in a strongly thrombogenic model. *J Reconstr Microsurg* 8(5):375, 1992.
248. Zhang B, Wieslander JB: Improvement of patency in small veins following dextran and/or low-molecular-weight heparin treatment. *Plast Reconstr Surg* 94(2):352, 1994.
249. Salemark L, Knudsen F, Dougan P: The effect of dextran 40 on patency following severe trauma in small arteries and veins. *Br J Plast Surg* 48:121, 1995.
250. Brooks D, Okeefe P, Buncke HJ: Dextran-induced acute renal failure after microvascular muscle transplantation. *Plast Reconstr Surg* 108:2057, 2001.
251. Hein KD, Wechsler ME, Schwartzstein RM, Morris DJ: The adult respiratory distress syndrome after dextran infusion as an antithrombotic agent in free TRAM flap breast reconstruction. *Plast Reconstr Surg* 103:1706, 1999.
252. Disa JJ, Polvora VP, Pusic AL, et al: Dextran-related complications in head and neck microsurgery: do the benefits outweigh the risks? A prospective randomized analysis. *Plast Reconstr Surg* 112:1534, 2003.
253. Sawada Y, Hatayama I, Sone, K: The effect of continuous topical application of heparin on flap survival. *Br J Plast Surg* 45:515, 1992.
254. Cox GW, Runnels S, Hsu HSH, Das SK: A comparison of heparinised saline irrigation solutions in a model of microvascular thrombosis. *Br J Plast Surg* 45:345, 1992.
255. Ritter EF, Cronan JC, Rudner AM, et al: Improved microsurgical anastomotic patency with low molecular weight heparin. *J Reconstr Microsurg* 14(5):331, 1998.
256. Kroll SS, Miller MJ, Reece GP, et al: Anticoagulants and hematomas in free flap surgery. *Plast Reconstr Surg* 96(3):643, 1995.
257. Hudson DA, Engelbrecht G, Duminy FJ: Another method to prevent venous thrombosis in microsurgery: an in situ venous catheter. *Plast Reconstr Surg* 105:999, 2000.
258. Senderoff DM, Zhang WX, Israeli D, et al: The additive beneficial effect of UW solution and urokinase on experimental microvascular free-flap survival. *J Reconstr Microsurg* 9(3):197, 1993.
259. Yii NW, Evans GRD, Miller MJ, et al: Thrombolytic therapy: what is its role in free flap salvage? *Ann Plast Surg* 46:601, 2001.
260. Serletti JM, Moran SL, Orlando GS, et al: Urokinase protocol for free-flap salvage following prolonged venous thrombosis. *Plast Reconstr Surg* 102:1947, 1998.
261. Soucacos PN, Beris AE, Malizos KN, et al: The use of medicinal leeches, *Hirudo medicinalis*, to restore venous circulation in trauma and reconstructive surgery. *Int Angiol* 13:251, 1994.
262. Batchelor AGG, Davison P, Sully L: The salvage of congested skin flaps by the application of leeches. *Br J Plast Surg* 37:358, 1984.
263. Lee C, Mehran RJ, Lessard ML, Kerrigan CL: Leeches: controlled trial in venous compromised rat epigastric flaps. *Br J Plast Surg* 45:235, 1992.
264. Rodgers IR, Grove AS, Silverman DG: Venous engorged tissue flaps treated with medicinal leeches. *Ophthalmic Plast Reconstr Surg* 8(4):271, 1992.
265. Adams JF, Lassen LF: Leech therapy for venous congestion following myocutaneous pectoralis flap reconstruction. *ORL - Head Neck Nurs* 13(1):12, 1995.
266. Kawabata H, Knight KR, Coe SA, et al: Experience with calcium antagonists nitrendipine, diltiazem, and verapamil and B_2 -agonist salbutamol in salvaging ischemic skin flaps in rabbits. *Microsurgery* 12:160, 1991.
267. Stark GB, Dorer A, Jaeger K, Narayanan K: The influence of the calcium channel blocker nimodipine on flap survival. *Ann Plast Surg* 23:306, 1989.
268. Hira M, Tajima S, Sano S: Increased survival length of experimental flap by calcium antagonist nifedipine. *Ann Plast Surg* 24:45, 1990.
269. Pal S, Khazanchi RK, Moudgil K: An experimental study on the effect of nifedipine on ischaemic skin flap survival in rats. *Br J Plast Surg* 44:299, 1991.
270. Carpenter RJ, Angel MF, Amiss LR, et al: Verapamil enhances the survival of primary ischemic venous obstructed rodent skin flaps. *Arch Otolaryngol Head Neck Surg* 119:1015, 1993.
271. Jernbeck J, Dalsgaard C-J: Calcitonin gene-related peptide treatment of flaps with compromised circulation in humans. *Plast Reconstr Surg* 91:236, 1993.
272. Rohrich RJ, Cherry GW, Spira M: Enhancement of skin-flap survival using nitroglycerin ointment. *Plast Reconstr Surg* 73:943, 1984.
273. Price MA, Pearl RM: Multiagent pharmacotherapy to enhance skin flap survival: lack of additive effect of nitroglycerin and allopurinol. *Ann Plast Surg* 33:683, 1994.
274. Nichter LS, Sobieski MW, Edgerton MT: Efficacy of topical nitroglycerin for random-pattern skin-flap salvage. *Plast Reconstr Surg* 75:847, 1985.
275. Ichioka S, Nakatsuka T, Sato Y, et al: Amrinone, a selective phosphodiesterase III inhibitor, improves microcirculation and flap survival: a comparative study with prostaglandin E_1 . *J Surg Res* 75:42, 1998.

276. Ichioka S, Nakatsuka T, Ohura N, et al: Clinical use of amrinone (a selective phosphodiesterase III inhibitor) in reconstructive surgery. *Plast Reconstr Surg* 108:1931, 2001.
277. Grossman JAI, McGonagle BA, Dowden RV, Dinner MI: The effect of hyaluronidase and dimethylsulfoxide (DMSO) on experimental skin flap survival. *Ann Plast Surg* 11:223, 1983.
278. Haller J, Trachy R, Cummings CW: Effect of dimethyl sulfoxide on island flap perfusion and survival in rats. *Arch Otolaryngol Head Neck Surg* 113:859, 1987.
279. Rand-Luby L, Pommier RF, Williams ST, et al: Improved outcome of surgical flaps treated with topical dimethylsulfoxide. *Ann Surg* 224:583, 1996.
280. Wadstrom J, Gerdin B: Modulatory effects of topically administered lidocaine and pentobarbital on traumatic vasospasm in the rabbit ear artery. *Br J Plast Surg* 44:341, 1991.
281. Emerson DJM, Sykes PJ: The effect of prostacyclin on experimental random pattern flaps in the rat. *Br J Plast Surg* 34:264, 1981.
282. Zachary LS, et al: Effects of exogenous prostacyclin on flap survival. *Surg Forum* 33:588, 1982.
283. Reus WF, Murphy RC, Hegggers JP, et al: Effect of intraarterial prostacyclin on survival of skin flaps in the pig: biphasic response. *Ann Plast Surg* 13:29, 1984.
284. Gateley DR, McAnulty GR, Martin DL: Intravenous infusion of prostacyclin to prevent platelet thrombus during microvascular anastomoses. *Br J Plast Surg* 49:249, 1996.
285. Senderoff DM, Israeli D, Zhang WX, et al: Iloprost improves survival of ischemic experimental skin flaps. *Ann Plast Surg* 32(5):490, 1994.
286. Renaud F, Succo E, Alessi MC, et al: Iloprost and salvage of a free flap. *Br J Plast Surg* 49:245, 1996.
287. Suzuki S, Isshiki N, Ogawa Y, et al: Effect of intravenous prostaglandin E1 on experimental flaps. *Ann Plast Surg* 19:49, 1987.
288. Nieto CS, Garcia MJS, Garcia PB: A comparative study on the effect of various pharmacological agents on the survival of skin flaps in the rat. *Br J Plast Surg* 45:113, 1992.
289. Angel MF, Ramasastry SS, Swartz WM, et al: Augmentation of skin flap survival with allopurinol. *Ann Plast Surg* 18:494, 1987.
290. Im MJ, Shen W-H, Pak CJ, et al: Effect of allopurinol on the survival of hyperemic island skin flaps. *Plast Reconstr Surg* 73:276, 1984.
291. Tamir G, Yaffe B, Pri-Chen S, et al: The effect of allopurinol on experimental island skin flap survival under prolonged periods of arterial ischaemia. *Br J Plast Surg* 47:155, 1994.
292. Picard-Ami LA Jr, MacKay A, Kerrigan CL: Pathophysiology of ischemic skin flaps: Differences in xanthine oxidase levels among rats, pigs, and humans. *Plast Reconstr Surg* 87:750, 1991.
293. Suzuki S, Miyachi Y, Niwa Y, Isshiki N: Significance of reactive oxygen species in distal flap necrosis and its salvage with liposomal SOD. *Br J Plast Surg* 42:559, 1989.
294. Hawkes JS, Young CMA, Cleland LG: Ischaemia reperfusion injury in pedicle skin flaps in the pig: lack of protective effect of SOD and allopurinol. *Br J Plast Surg* 42:668, 1989.
295. Prada FS, Arrunategui G, Alves MC, et al: Effect of allopurinol, superoxide-dismutase, and hyperbaric oxygen on flap survival. *Microsurgery* 22:352, 2002.
296. Angel MF, Narayanan K, Swartz WM, et al: Deferoxamine increases skin flap survival: additional evidence of free radical involvement in ischaemic flap surgery. *Br J Plast Surg* 39:469, 1986.
297. Green CJ, Dharni L, Prasad S, et al: The effect of desferrioxamine on lipid peroxidation and survival of ischaemic island skin flaps in rats. *Br J Plast Surg* 42:565, 1989.
298. Nancarrow JD: Augmentation of island flaps by preoperative cell membrane stabilisation: an experimental study in rats. *Br J Plast Surg* 34:212, 1981.
299. Nakatsuka T, Pang CY, Neligan P, et al: Effect of glucocorticoid treatment on skin capillary blood flow and viability in cutaneous and myocutaneous flaps in the pig. *Plast Reconstr Surg* 76:374, 1985.
300. Peter FW, Franken RJPM, Wang WZ, et al: Effective low dose aspirin on thrombus formation at arterial and venous microanastomoses and on the tissue microcirculation. *Plast Reconstr Surg* 99:1112, 1997.
301. Salemark L, Wieslander JB, Dougan P, Arnlfots B: Time of low-dose acetylsalicylic acid administration influences in vivo platelet function and thrombus formation following arteriotomy and intimestomy; an experimental study in small arteries of rabbits. *Microsurgery* 11:209, 1990.
302. Buckley RC, Davidson SF, Das SK: Effects of ketorolac tromethamine (Toradol®) on a functional model of microvascular thrombosis. *Br J Plast Surg* 46:296, 1993.
303. Forrest CR, Pang CY, Lindsay WK: Dose and time effects of nicotine treatment on the capillary blood flow and viability of random pattern skin flaps in the rat. *Br J Plast Surg* 40:295, 1987.
304. Black CE, Huang N, Neligan PC, et al: Effect of nicotine on vasoconstrictor and vasodilator responses in human skin vasculature. *Am J Physiol Regulatory Integrative Comp Physiol* 281:R1097, 2001.
305. Sloan GM, Sasaki GH: Noninvasive monitoring of tissue viability. *Clin Plast Surg* 12(2):185, 1985.
306. Neligan PC: Monitoring techniques for the detection of flow failure in the postoperative period. *Microsurgery* 14:162, 1993.
307. Furnas H, Rosen JM: Monitoring in microvascular surgery. *Ann Plast Surg* 26(3):265, 1991.
308. Truelson JM: Perioperative patient management of free flaps. *Fac Plast Surg* 12(1):13, 1996.
309. Bradford CR: Flap monitoring. *Fac Plast Surg* 12(1):19, 1996.
310. Gapany M: Failing flap. *Fac Plast Surg* 12(1):23, 1996.
311. Brown JS, Devine JC, Magennis P, et al: Factors that influence the outcome of salvage in free tissue transfer. *Br J Oral Maxillofac Surg* 41:16, 2003.
312. Climo S: Dermal bleeding and the delay operation. *Plast Reconstr Surg* 8:59, 1951.
313. Jones BM, Dunscombe PB, Greenhalgh RM: Differential thermometry as a monitor of blood flow in skin flaps. *Br J Plast Surg* 36:83, 1983.
314. Khouri RK, Shaw WW: Monitoring of free flaps with surface-temperature recordings: is it reliable? *Plast Reconstr Surg* 89(3):495, 1992.

315. Cho BC, Shin DP, Byun JS, et al: Monitoring flap for buried free tissue transfer: its importance and reliability. *Plast Reconstr Surg* 110:1249, 2002.
316. Akin S, Basut O: A new flap design for monitoring the circulation of a buried free radial forearm flap in pharyngoesophageal reconstruction. *J Reconstr Microsurg* 18:591, 2002.
317. Lange K, Boyd L: The use of fluorescein to determine the adequacy of the circulation. *Med Clin North Am* 26:943, 1942.
318. Myers MB: Prediction of skin sloughs at the time of operation with the use of fluorescein dye. *Surgery* 51:158, 1962.
319. McCraw JB, Myers B, Shanklin KD: The value of fluorescein in predicting the viability of arterialized flaps. *Plast Reconstr Surg* 60:710, 1977.
320. Kreidstein ML, Levine RH, Knowlton RJ, Pang CY: Serial fluorometric assessments of skin perfusion in isolated perfused human skin flaps. *Br J Plast Surg* 48:288, 1995.
321. Pang CY, et al: Assessment of the fluorescein dye test for prediction of skin flap viability in pigs. *J Surg Res* 41:173, 1986.
322. Myers B, Donovan W: An evaluation of eight methods of using fluorescein to predict the viability of skin flaps in the pig. *Plast Reconstr Surg* 75:245, 1985.
323. Odland RM, Poole DV, Lessard GM, et al: Fluorescein and acidosis. *Arch Otolaryngol Head Neck Surg* 118(7):712, 1992.
324. Silverman DG, Norton KJ, Brousseau DA: Serial fluorometric documentation of fluorescein dye delivery. *Surgery* 97:185, 1985.
325. Suzuki Y, Isshiki N, Ishikawa K, Koyama H: Viability and quantitative dermofluorometry of experimental arterialised and non-arterialised venous flaps. *Br J Plast Surg* 46:273, 1993.
326. Thomson JC, Kerrigan CL: Dermofluorometry: Thresholds for predicting flap survival. *Plast Reconstr Surg* 83:859, 1989.
327. Issing WJ, Naumann C: Evaluation of pedicled skin flap viability by pH, temperature and fluorescein: an experimental study. *J Cranio-Maxillofac Surg* 24:305, 1996.
328. Holm C, Mayr M, Hofter A, et al: Intraoperative evaluation of skin-flap viability using laser-induced fluorescence of indocyanine green. *Br J Plast Surg* 55:635, 2002.
329. Holm C, Tegeler J, Mayr M, et al: Monitoring free flaps using laser-induced fluorescence of indocyanine green: a preliminary experience. *Microsurgery* 22:278, 2002.
330. Eren S, Rubben A, Krein R, et al: Assessment of microcirculation of an axial skin flap using indocyanine green fluorescence angiography. *Plast Reconstr Surg* 96:1636, 1995.
331. Still J, Law E, Dawson J, et al: Evaluation of the circulation of reconstructive flaps using laser-induced fluorescence of indocyanine green. *Ann Plast Surg* 42:266, 1999.
332. Amerhauser A, Moelleken BRW, Mathes SJ, et al: Color flow ultrasound for delineating microsurgical vessels: a clinical and experimental study. *Ann Plast Surg* 30(3):193, 1993.
333. Svensson H, Svedman P, Holmberg J, Jacobsson S: Detecting arterial and venous obstruction in flaps. *Ann Plast Surg* 14:20, 1985.
334. Hallock GG: Critical threshold for tissue viability as determined by laser Doppler flowmetry. *Ann Plast Surg* 28:554, 1992.
335. Heden P, Jurell G, Arnander C: Prediction of skin flap necrosis: a comparative study between laser doppler flowmetry and fluorescein test in a rat model. *Ann Plast Surg* 17:485, 1986.
336. Heden P, Eriksson E: Skin flap circulation: simultaneous monitoring with laser Doppler and electromagnetic flowmeters in the pig island buttock flap. *Scand J Plast Reconstr Surg* 23:1, 1989.
337. Hovius SER, Adrichem LNA, Mulder HD, et al: The predictive value of the laser doppler flowmeter for postoperative microvascular monitoring. *Ann Plast Surg* 31(4):307, 1993.
338. Bircher A, DeBoer EM, Agner T, et al: Guidelines for measurement of cutaneous blood flow by laser doppler flowmetry. *Contact Dermatitis* 30(2):65, 1994.
339. Svensson H, Holmberg J, Svedman P: Interpreting laser doppler recordings from free flaps. *Scand J Plast Reconstr Hand Surg* 27:81, 1993.
340. Silverman DG, et al: Comparative assessment of blood flow to canine island flaps. *Arch Otolaryngol* 111:677, 1985.
341. Cummings CW, et al: Prognostication of myocutaneous flap viability using laser Doppler velocimetry and fluorescein microfluorometry. *Otolaryngol Head Neck Surg* 92:559, 1984.
342. Marks NJ: Quantitative analysis of skin flap blood flow in the rat using laser Doppler velocimetry. *J R Soc Med* 78:308, 1985.
343. Place MJ, Witt P, Hendricks D: Cutaneous blood-flow patterns in free flaps determined by laser Doppler flowmetry. *J Reconstr Microsurg* 12:355, 1996.
344. Yuen JC, Feng Z: Monitoring free flaps using the laser Doppler flowmeter: five-year experience. *Plast Reconstr Surg* 105:55, 2000.
345. Hallock GG, Altobelli JA: Assessment of TRAM flap perfusion using laser doppler flowmetry: an adjunct to microvascular augmentation. *Ann Plast Surg* 29(2):122, 1992.
346. Arnold F, He CF, Jia CY, Cherry GW: Perfusion imaging of skin island flap blood flow by a scanning laser-doppler technique. *Br J Plast Surg* 48:289, 1995.
347. Yamamoto Y, Ohura T, Nohira K, et al: Laserflowgraphy: a new visual blood flow meter utilizing a dynamic laser speckle effect. *Plast Reconstr Surg* 91(5):884, 1993.
348. Tsur H, Orenstein A, Mazkereth R: The use of transcutaneous oxygen pressure measurement in flap surgery. *Ann Plast Surg* 8:510, 1982.
349. Hjortdal VE, Awwad AM, Gottrup F, et al: Tissue oxygen tension measurement for monitoring musculocutaneous and cutaneous flaps. *Scand J Plast Reconstr Hand Surg* 24:27, 1990.
350. Kerrigan CL, Daniel RK: Monitoring acute skin-flap failure. *Plast Reconstr Surg* 71:519, 1983.

351. Larsson L: An electrophysiological method for monitoring blood flow in skeletal muscle. An experimental study in the rat. *Scand J Plast Reconstr Surg* 23:181, 1989.
352. Varnell RM, et al: Myocutaneous flap failure: early detection with Gd-DTPA-enhanced MR imaging. *Radiology* 173:755, 1989.
353. Klein HW, Gourley IM: Use of magnetic resonance spectroscopy in the evaluation of skin flap circulation. *Ann Plast Surg* 20:547, 1988.
354. Golde AR, Mahoney JL: The oxygen optode: an improved method of assessing flap blood flow and viability. *J Otolaryngol* 23(2):138, 1994.
355. Hofer SOP, Timmenga EJJ, Christiano R, Bos KE: An intravascular oxygen tension monitoring device used in myocutaneous transplants: a preliminary report. *Microsurgery* 14:304, 1993.
356. Lindsey LA, Watson JD, Quabe AA: Pulse oximetry in postoperative monitoring of free muscle flaps. *Br J Plast Surg* 44:27, 1991.
357. Irwin MS, Thorniley MS, Dore CJ, Green CJ: Near infrared spectroscopy: a non-invasive monitor of perfusion and oxygenation within the microcirculation of limbs and flaps. *Br J Plast Surg* 48:14, 1995.
13. Wiese KG: Osmotically induced tissue expansion with hydrogels: a new dimension in tissue expansion? A preliminary report. *J Craniomaxillofac Surg* 21:309, 1993.
14. Bergé SJ, Wiese KG, von Lindern J-J, et al: Tissue expansion using osmotically active hydrogel systems for direct closure of the donor defect of the radial forearm flap. *Plast Reconstr Surg* 108:1, 2001.
15. Johnson TM, Lowe L, Brown MD, et al: Histology and physiology of tissue expansion. *J Dermatol Surg Oncol* 19:1074, 1993.
16. Austad ED, Pasyk KA, McClatchey KD, Cherry GW: Histomorphologic evaluation of guinea pig skin and soft tissue after controlled tissue expansion. *Plast Reconstr Surg* 70:704, 1982.
17. Austad ED, Thomas SB, Pasyk K: Tissue expansion: dividend or loan? *Plast Reconstr Surg* 78(1):63, 1986.
18. Argenta LC, Marks MW, Pasyk KA: Advances in tissue expansion. *Clin Plast Surg* 12:159, 1985.
19. Pasyk KA, Argenta LC, Hassett C: Quantitative analysis of the thickness of human skin and subcutaneous tissue following controlled expansion with a silicone implant. *Plast Reconstr Surg* 81:516, 1988.
20. Leighton WD, Russell RC, Feller AM, et al: Experimental pretransfer expansion of free-flap donor sites: II. physiology, histology, and clinical correlation. *Plast Reconstr Surg* 82:76, 1988.
21. Olenius M, Johansson O: Variations in epidermal thickness in expanded human breast skin. *Scand J Plast Reconstr Hand Surg* 29(1):15, 1995.
22. Olenius M, Dalsgaard CJ, Wickman M: Mitotic activity in expanded human skin. *Plast Reconstr Surg* 91(2):213, 1993.
23. Takei T, Mills I, Arai K, Sumpio BE: Molecular basis for tissue expansion: clinical implications for the surgeon. *Plast Reconstr Surg* 102:247, 1998.
24. Rohrich RJ: Principles of tissue expansion. *Presented at the PSEF symposium in Snowbird, Utah, Feb 16-21, 1988.*
25. Melis P, Noorlander ML, van der Horst CM, van Noorden CJ: Rapid alignment of collagen fibers in the dermis of undermined and not undermined skin stretched with a skin-stretching device. *Plast Reconstr Surg* 109:674, 2002.
26. Chang B, Tuchler RE, Siebert JW, et al: The effect of tissue expansion on dermal fibroblast contraction. *Ann Plast Surg* 28:315, 1992.
27. Lee P, Squier CA, Bardach J: Enhancement of tissue expansion by anticontractile agents. *Plast Reconstr Surg* 76:604, 1985.
28. Beauchene JC, et al: Biochemical, biomechanical, and physical changes in the skin in an experimental animal model of therapeutic tissue expansion. *J Surg Res* 47:507, 1989.
29. Johnson PE, Kernahan DA, Bauer BS: Dermal and epidermal response to soft-tissue expansion in the pig. *Plast Reconstr Surg* 81:390, 1988.
30. Knight KR, McCann JJ, Vanderkolk CA, et al: The redistribution of collagen in expanded pig skin. *Br J Plast Surg* 43:565, 1990.
31. Timmenga EJJ, Schoorl R, Klopffer PJ: Biomechanical and histomorphological changes in expanded rabbit skin. *Br J Plast Surg* 43:101, 1990.

Skin Expansion

1. Bennett RG, Hirt M: A history of tissue expansion. *Dermatol Surg Oncol* 19:1066, 1993.
2. Neumann CG: The expansion of an area of skin by progressive distention of a subcutaneous balloon. Use of the method for securing skin for subtotal reconstruction of the ear. *Plast Reconstr Surg* 19:124, 1957.
3. Radovan C: Adjacent flap development using expandable Silastic implant. *Presented at the Annual Meeting of the American Society of Plastic and Reconstructive Surgeons, Boston, Mass., 1976.*
4. Baker SR: Fundamentals of expanded tissue. *Head Neck* 13:327, 1991.
5. Jackson IT, Sharpe DT, Polley J, et al: Use of external reservoirs in tissue expansion. *Plast Reconstr Surg* 80:266, 1987.
6. Hallock GG, Rice DC: Objective monitoring for safe tissue expansion. *Plast Reconstr Surg* 77:416, 1986.
7. Hallock GG, Rice DC: Increased sensitivity in objective monitoring of tissue expansion. *Plast Reconstr Surg* 91(2):217, 1993.
8. Pietilä JP, Nordström REA, Virkkunen PJ, et al: Accelerated tissue expansion with the "overfilling" technique. *Plast Reconstr Surg* 81:204, 1988.
9. Beek AL, Adson MH: Tissue expansion in the upper extremity. *Clin Plast Surg* 14:535, 1987.
10. Rappard JHA, Molenaar J, Doorn D, et al: Surface-area increase in tissue expansion. *Plast Reconstr Surg* 83:733, 1988.
11. Matton GE, Tonnard PL, Monstrey SJ, Landuyt KH: A universal incision for tissue expander insertion. *Br J Plast Surg* 48:172, 1995.
12. Austad ED, Rose GL: A self-inflating tissue expander. *Plast Reconstr Surg* 70:588, 1982.

32. Wickman M, Heden P, Jurell G: Circulatory and metabolic changes in expanded pig skin flaps. *Plast Reconstr Surg* 88:650, 1991.
33. Pasyk KA, Austed ED, Cherry GW: Intra-cellular collagen fibers around silicone expander. *J Surg Res* 36(2):125, 1984.
34. Maturri L, Azzolini A, Riberti C, et al: Long-term histopathologic evaluation of human expanded skin. *Plast Reconstr Surg* 90:636, 1992.
35. Lee Y, Gil MS, Hong JJ: Histomorphologic changes of hair follicles in human expanded scalp. *Plast Reconstr Surg* 105:2361, 2000.
36. Gur E, Hanna W, Andrighetti L, Semple JL: Light and electron microscopic evaluation of the pectoralis major muscle following tissue expansion for breast reconstruction. *Plast Reconstr Surg* 102:1046, 1998.
37. Kao JT, Dagum AB, Mahoney JL, et al: The histopathological changes in irradiated vs. nonirradiated tissue-expanded skin in the porcine model. *Ann Plast Surg* 39:287, 1997.
38. Dvali LT, Dagum AB, Pang CY, et al: Effect of radiation on skin expansion and skin flap viability in pigs. *Plast Reconstr Surg* 106:624, 2000.
39. Goodman CM, Miller R, Patrick CW Jr, et al: Radiotherapy: effects on expanded skin. *Plast Reconstr Surg* 110:1080, 2002.
40. Cherry GW, Austed E, Pasyk K, et al: Increased survival and vascularity of random-pattern skin flaps elevated in controlled, expanded skin. *Plast Reconstr Surg* 72:680, 1983.
41. Sasaki GH, Pang CY: Pathophysiology of skin flaps raised on expanded pig skin. *Plast Reconstr Surg* 74:59, 1984.
42. Saxby PJ: Survival of island flaps after tissue expansion: a pig model. *Plast Reconstr Surg* 81:30, 1988.
43. Babovic S, Angel MF, Im MJ, et al: Effects of tissue expansion on secondary ischemic tolerance in experimental free flaps. *Ann Plast Surg* 34(6):593, 1995.
44. Vander Kolk CA, McCann JJ, Knight KR, O'Brien BM: Some further characteristics of expanded tissue. *Clin Plast Surg* 14:447, 1987.
45. Siegert R, Weerda H, Hoffmann S, Mohadjer C: Clinical and experimental evaluation of intermittent intraoperative short-term expansion. *Plast Reconstr Surg* 92(2):248, 1993.
46. Sasaki GH: Intraoperative sustained limited expansion (ISLE) as an immediate reconstructive technique. *Clin Plast Surg* 14(3):563, 1987.
47. Sasaki GH: Intraoperative expansion as an immediate reconstructive technique. *Facial Plast Surg* 5:362, 1988.
48. Shapiro AL, Hochman M, Thomas JR, Branham G: Effects of intraoperative tissue expansion and skin flaps on wound closing tensions. *Arch Otolaryngol Head Neck Surg* 122:1107, 1996.
49. Wee SS, Logan SE, Mustoe TA: Continuous versus intraoperative expansion in the pig model. *Plast Reconstr Surg* 90:808, 1992.
50. Futran ND: Closure of the fibula free flap donor site with the Sure-Closure™ skin-stretching device. *Laryngoscope* 106:1487, 1996.
51. Hirshowitz B, Lindenbaum E, Har-Shai Y: A skin-stretching device for the harnessing of the viscoelastic properties of skin. *Plast Reconstr Surg* 92:260, 1993.
52. Wickman M, Olenius M, Malm M, et al: Alterations in skin properties during rapid and slow tissue expansion for breast reconstruction. *Plast Reconstr Surg* 90:945, 1992.
53. Fisher J, Hammond DC: The combination of expanders with autogenous tissue in breast reconstruction. *Clin Plast Surg* 21(2):309, 1994.
54. Joss GS, Zoltie N and Chapman P: Tissue expansion technique and the transposition flap. *Br J Plast Surg* 43:328, 1990.
55. Wilmschurst AD, Sharpe DT: Immediate placement of tissue expanders in the management of large excisional defects on the face. *Br J Plast Surg* 43:150, 1990.
56. Austed ED: Complications in tissue expansion. *Clin Plast Surg* 14:549, 1987.
57. Reinisch J, Myers B: The effect of local anesthesia with epinephrine on skin flap survival. *Plast Reconstr Surg* 54:324, 1974.
58. Manders EK, Schenden MJ, Furrey JA, et al: Soft-tissue expansion: Concepts and complications. *Plast Reconstr Surg* 74:493, 1984.
59. Zoltie N, Chapman P, Joss G: Tissue expansion: A unit review of non-scalp, non-breast expansion. *Br J Plast Surg* 43:325, 1990.
60. Youm T, Margiotta M, Kasabian A, Karp N: Complications of tissue expansion in a public hospital. *Ann Plast Surg* 42:396, 1999.
61. Cohen KI, Roberts C: Lidocaine relieves pain with tissue expansion of the breast (letter). *Plast Reconstr Surg* 79:489, 1987.
62. Sinow JD, Cunningham BL: Intraluminal lidocaine for analgesia after tissue expansion: A double-blind prospective trial in breast reconstruction. *Ann Plast Surg* 28:320, 1992.
63. McGuire JJ, Caffee HH: In vivo diffusion of lidocaine through tissue expanders. *Plast Reconstr Surg* 89:675, 1992.
64. Derby LD, Sinow JD, Bowers LD, Cunningham BL: Quantitative analysis of lidocaine hydrochloride delivery by diffusion across tissue expander membranes. *Plast Reconstr Surg* 89:900, 1992.
65. Calobrace MB, Downey SE: Calvarial deformity and remodeling following prolonged scalp expansion in a child. *Ann Plast Surg* 39:186, 1997.
66. Paletta CE, Bass J, Shehadi SI: Outer table skull erosion causing rupture of scalp expander. *Ann Plast Surg* 23:538, 1989.

Selected Readings in Plastic Surgery

PUBLISHER Selected Readings in Plastic Surgery
411 North Washington, Suite 6900
Dallas, Texas 75246-1777
(214) 824-0154 FAX (214) 824-0463
srps@swbell.net

EDITORIAL STAFF Jeffrey M Kenkel MD, *Editor*
Fritz E Barton Jr MD, *Editor Emeritus*
Grace Darling MS, ELS(D), *Managing Editor*
John L Darling, *Associate Editor*
Sheri Quisenberry, *Business Manager*

EDITORIAL BOARD	RG Anderson MD	FL Hackney MD, DDS	JC O'Brien MD
	G Broughton MD	L Hollier MD	RJ Rohrich MD
	HS Byrd MD	J Janis MD	MC Snyder MD
	D Gonyon MD	JM Kenkel MD	J Thornton MD
	A Gosman MD	JE Leedy MD	RIS Zbar MD
	KA Gutowski MD	A Lipschitz MD	
	JR Griffin MD	JA Masson FRACS	
	RY Ha MD	AR Muzaffar MD	

INFORMATION FOR SUBSCRIBERS A SELECTED READINGS IN PLASTIC SURGERY (ISSN 0739-5523) volume consists of 30 numbers, issued approximately 15 times per year. A subscription entitles you to receive 15 numbers, so to obtain an entire volume, you must subscribe for 2 consecutive years.

ANNUAL SUBSCRIPTION RATES: A 15-issue subscription is \$300 US. CDs of volume 9, numbers 1-20 and 21-40, are also available for \$300 each. CME quizzes are \$60 for 15 issues. Modules (please inquire) are \$200 each. International subscribers, add \$50 to the above. Single issues are \$40 US, \$50 non-US. Binders with tabs are available for domestic shipping only at \$20 each. We accept payment by check (US funds), purchase order, or VISA/MasterCard charge. Please allow 8 to 10 weeks for receipt of your first issue.

SHIPPING We mail 8 times a year, two issues per mailing. Claims for lost copies will be honored for 3 months after publication for domestic subscribers and 6 months for subscribers outside the U.S. Please note that all sales are final – no returns will be accepted.

BACK ISSUES To obtain back issues you may write to us at 411 North Washington, Suite 6900, Dallas TX 75246; e-mail srps@swbell.net; or fax 214-824-0463. Please inquire about availability and price before placing your order. Prepayment or credit card information must accompany all requests.


COPYRIGHT © 2005 by SELECTED READINGS IN PLASTIC SURGERY. Published under the auspices of the University of Texas Southwestern Medical Center and Baylor University Medical Center, Dallas, Texas.



ISSN 0739-5523

Printed on recycled paper using soy-based ink; 100% recyclable.

SOUTHWESTERN
THE UNIVERSITY OF TEXAS
SOUTHWESTERN MEDICAL CENTER
AT DALLAS

 **BAYLOR UNIVERSITY
MEDICAL CENTER**
An Affiliate of the
Baylor Health Care System