

Selected Readings in Plastic Surgery

Volume 10, Number 7 Part 2

2005

BURNS AND POSTBURN RECONSTRUCTION

**George Broughton MD PhD
and
Ross I S Zbar MD**

BURNS AND POSTBURN RECONSTRUCTION

George Broughton MD PhD and Ross I S Zbar MD

ACUTE BURNS

A report from the U.S. Centers for Disease Control and Prevention indicates that an estimated 25,717 residential fire-related injuries were treated in U.S. emergency departments (ED) in 2001.¹ Although common injuries included anoxia and burns, patients with fire-related injuries also are at risk for having nonphysical injuries related to mental health (eg, post-traumatic stress disorder). These emotional consequences can have a lasting impact, especially on children.² Burn deaths have declined rapidly probably as a result of successful prevention strategies and improved burn care. It must be noted, however, that the epidemiologic data on household burns is most likely underreported.^{1,3}

In 1993 the LA₅₀ (defined as burn size lethal to 50% of patients) in most burn units approached 75% total body surface area (TBSA) burn.^{4,5} This was ascribed to a number of factors such as early excision and skin grafting; improved ICU care, ventilation, and nutrition; antibiotics; and, as always, the “team approach” in dedicated burn units. Infection continues to be the leading cause of morbidity and mortality in patients with thermal injury. The lung is now the primary source of infection, while burn wound sepsis has virtually disappeared.⁶

Saffle and colleagues⁷ reviewed 6417 patients with a mean burn size of 14.1% TBSA who were treated in 28 burn centers in the United States between 1991 and 1993, and noted 95.9% survival. For young adults in this group, the LA₅₀ was 81% TBSA. Deaths associated with inhalation injury amounted to 29.4%. The mean length of hospital stay (LOS) was 13.5 days, and average total charges per stay were \$39,533.

McGwin and coworkers⁸ evaluated differences in mortality among adult burn patients over a 25-year period according to age. All patients admitted to a regional burn center between 1973 and 1997

were sorted into three age groups: 18–34, 35–54, and 55 and older. Mortality rates in these patients were compared over time. The proportion of patients in each age group remained consistent, as did the type of burns. The average TBSA burned declined steadily from 31.6% in the 1970s to 18.2% in the late 1990s, and paralleled declines in mortality among adult burn patients across the age spectrum.

A review of 3118 patients admitted to the Los Angeles County–University of Southern California Burn Center in the last 10 years⁹ arrived at the following statistics: A majority of patients were young adults (60%) or small children (17%); 48% of injuries were <5% TBSA and 2% were >60% TBSA; 82% were accidental burns; 60% of admitted patients underwent skin grafting; and mortality was negligible in the group with <10% TBSA burn and 79% in the most severely burned group. There was a high correlation between age and mortality.

Danks¹⁰ offers a comprehensive review of the epidemiology and treatment of burn victims.

Natural History

There are three zones of burn.¹¹ The central area is called the *zone of coagulation* and is composed of nonviable tissue. Surrounding this central area is the *zone of stasis*. Initially blood flow is present here, but over the subsequent 24 hours hypoperfusion and ischemia prevail and part of this area combines with the zone of coagulation. Surrounding the zone of stasis is the outer *zone of hyperemia*, which contains viable tissue.

Along with the extent of burn and age of the patient, the depth of the burn wound is a primary determinant of mortality following thermal injury. Wound depth is also a major determinant of a patient's long term appearance and function after a burn. At this time the most accurate way to determine depth of burn is clinical assessment based on experience. The changing perfusion in the zone of

stasis and the fact that burn depth is not uniform everywhere make it difficult for the physician to accurately determine the depth of burn for the first 24–48h. Immersion scalds in very young children are particularly difficult to assess for depth. A number of techniques such as burn biopsy, vital dyes, fluorescein, and laser Doppler flowmeter have been tried in an attempt to aid clinical observation, but none has been completely successful.¹²

Thanks largely to the prevalence of topical antimicrobial agents, burn wound sepsis in most burn units in this country is of minor clinical importance. Topical antimicrobials, however, by decreasing the bacterial concentration of the burn wound, have resulted in prolonged separation of the eschar. As a result, surgical excision with skin grafting of not only full-thickness but also partial-thickness burns is aggressively followed.

Triage of the Burn Patient

Minor burns, those that are superficial and do not exceed 10%–15% of total body surface area, generally do not require hospitalization. Larger burns than these may be treated on an outpatient basis, but only in unique circumstances.¹³ Survival after this type of burn is not an issue and scarring is not a problem.

A **partial-thickness burn** will reepithelialize spontaneously over a period of time that varies with depth of the burn. Superficial partial-thickness burns can be treated in a variety of ways. Most authors recommend application of a topical antimicrobial agent. Once the wound has been cleaned and debrided, it may be “closed” with pig skin or Biobrane to help relieve pain and simplify wound care.¹⁴ The dressing is left on the burn wound until the wound begins to spontaneously reepithelialize, at which time the dressing membranes separate from the underlying epidermis and are peeled or cut off. Very deep burns that are allowed to heal spontaneously scar severely, so that most surgeons recommend surgery for coverage once the depth is ascertained. Children with scalding wounds who are under 1 year of age must be examined daily, and if by 14 days there is no gross evidence of reepithelialization, surgical excision should be considered.

Full-thickness burns may extend into fat, fascia, muscle, and even bone, and all must be excised

and skin grafted. If only the dermis or superficial fat is involved, tangential excision into fat is recommended. Early wound closure has obvious benefits, but factors contributing to surgical morbidity, especially age and burn location, should be considered in the decision.¹⁵ Only isolated reports have shown that mortality decreases with early (first 24h) total excision of full-thickness burns in patients with massive injuries.¹⁶

The following burns should be treated in a specialized center:¹⁷

- 2° and 3° burns >10% TBSA in patients <10 or >50yo
- 2° and 3° burns >20% TBSA in other age groups
- 3° burns >5% TBSA in any age group
- 2° and 3° burns involving the face, hands, feet, genitalia, perineum, or major joints
- electric burns, including lightning injury
- chemical burns with serious threat of functional or cosmetic impairment
- inhalation injuries
- lesser burns in patients with preexisting medical problems that could complicate management
- combined mechanical and thermal injury in which the burn wound poses the greater risk

If an adult burn victim is within 20min of a hospital, there is no need to start an intravenous drip on site which may delay transport. For the young pediatric patient, it is best to “scoop and run” if transport time is under 1h.

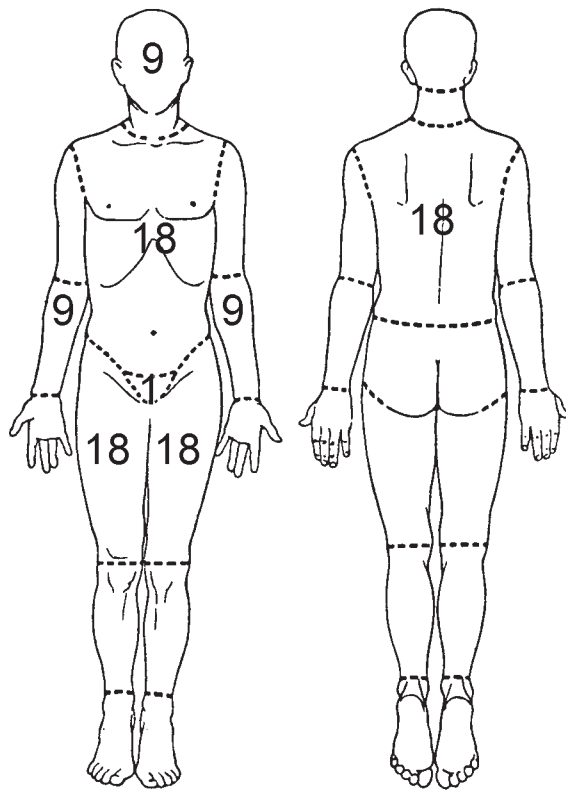
On admission to the hospital, the burn victim is treated as any trauma patient, ie, is evaluated for **A**irway, **B**reathing, and **C**irculation. Burn patients generally have normal vital signs (if there is no other associated trauma) and are able to communicate with the examiner. At the hospital two large-bore *peripheral* catheters are inserted, preferably through unburned skin. This avoids the complications that may ensue with central lines, such as pneumothorax (subclavian a), inadvertent arterial injury (femoral a), and venous thrombosis.

Burn Resuscitation

The successful management of burn shock is critical to a patient’s survival. Burn shock is both hy-

povolemic and cellular in nature, and is characterized by specific hemodynamic changes including decreased cardiac output and plasma volume, increased extracellular fluid, and oliguria.

Fluid replacement. Both the depth and extent of burn determine the volume of fluid needed for resuscitation. The “rule of nines” is a simple and relatively accurate way to estimate the percentage of total body surface area burn in patients >15yo (Fig 1).



Head and neck	9%
Anterior trunk	18%
Posterior trunk	18%
Left arm	9%
Right arm	9%
Left leg	18%
Right leg	18%
Genitalia and perineum	1%

Fig 1. The “Rule of Nines” for estimating percent of total body surface area burn (%TBSA) in adults.

The goal of therapy is to replace the fluid sequestered as a result of the injury. Ideally one should administer the least amount of fluid necessary to

maintain adequate organ perfusion. The best guide to adequacy of resuscitation in the first 24–48h is the hourly urine output. The volume infused should be continually titrated to avoid both under-resuscitation and overresuscitation.

The main ingredient of any resuscitation fluid is salt replacement. Crystalloid in the form of lactated Ringer’s solution at a concentration of 130mEq/L is the most popular and easily used resuscitation fluid. Warden¹⁸ discusses several formulas used to resuscitate burn patients. The one generally recommended is the Parkland formula, which calls for lactated Ringer’s, 4mL/kg/% burn in the first 24h. Colloid is usually unnecessary at this time because protein leaks from the capillaries into the extravascular space. A urine output of 0.5mL/kg/h indicates adequate tissue perfusion so long as there is no glycosuria.

Burn size and low weight are associated with greater fluid requirements during the first 24h but do not follow a linear relationship. Mechanical ventilation has supplanted TBSA by 24h as a predictor of high fluid intake.¹⁹ One of every 5 adult patients requires more or less fluid than calculated.

During the second 24h, a 5% albumin solution is administered in a volume of 0.1mL/kg/% burn. The fluid is infused over 2–3h.

In some situations it may be appropriate to monitor the central venous pressure of burn patients with a Swan-Ganz catheter. These circumstances include failure to resuscitate according to the prescribed urine output; extremes of age, particularly the elderly; preexisting cardiac disease if the patient is symptomatic—eg, angina—or there is evidence of pump failure; and patients with severe inhalation injury or pulmonary insufficiency where high positive end expiratory pressure is required.²⁰

Children. Because of differences in proportion of body parts between children and adults and larger surface area per unit weight in children, the Berkow chart is used for calculating % TBSA in pediatric burn patients (Table 1).

The Parkland formula must be modified in pediatric patients by adding maintenance fluid to the resuscitation volume, 1500mL/m². A urine output of 1mL/kg/h is considered evidence of adequate resuscitation in children.

During the second 24h, a solution of either 0.25% or 0.45% sodium chloride is given as fluid replace-

TABLE 1
The Berkow Formula for Calculating % TBSA in Children and Adolescents

AREA	1 YR	1-4	YRS5-9	YRS	10-14 YRS	15	YRS
Head	19	17	13	11	9		
Neck	2	2	2	2	2		
Ant. Trunk	13	13	13	13	13		
Post. Trunk	13	13	13	13	13		
R. Buttock	2½	2½	2½	2½	2½		
L. Buttock	2½	2½	2½	2½	2½		
Genitalia	1	1	1	1	1		
R.U. Arm	4	4	4	4	4		
L.U. Arm	4	4	4	4	4		
R.L. Arm	3	3	3	3	3		
L.L. Arm	3	3	3	3	3		
R. Hand	2½	2½	2½	2½	2½		
L. Hand	2½	2½	2½	2½	2½		
R. Thigh	5½	6½	8	8½	9		
L. Thigh	5½	6½	8	8½	9		
R. Leg	5	5	5½	6	6½		
L. Leg	5	5	5½	6	6½		
R. Foot	3½	3½	3½	3½	3½		
L. Foot	3½	3½	3½	3½	3½		

ment because of the small intravascular volume of children. If only 5% dextrose in water is used and the infusion rate is too rapid, hyponatremia and seizures may occur.

Children <3y, especially infants <6mo, have a limited amount of glycogen stored in the liver, which may be rapidly depleted under conditions of burn stress. Blood glucose in young children should be measured every hour for the first 24h postburn because of the high risk of hypoglycemia.

Management of Edema

Significant fluid shifts occur from the intravascular to the extravascular space soon after a burn that persist for the first 24h. The rate and amount of edema formation depends on burn depth and size.

In small burns edema peaks early, while in large burns edema development continues for 18–24h. With burns >35%–40% TBSA, edema also occurs in unburned tissue.

Early increased vascular permeability is in part related to histamine, but many of the local effects are similar to a reperfusion injury.²¹ The reestablishment of blood flow to ischemic areas triggers a sequence of events that produce irreversible damage. The mechanism accounting for this increased vascular permeability is likely related to polymorphonuclear leukocytes (PMN) and their adhesion to the endothelium. PMN have been identified as contributing to the microvascular occlusion seen both systemically and locally following burn injury. The adherence of PMN to vascular endothelial cell surfaces creates a microenvironment in which PMN-

derived proteases and toxic oxygen radicals, hydrogen peroxide and hydroxyl radicals are released by both endothelial cells and PMN. These radicals trigger peroxidation of lipids in cell membranes and resultant cell lysis, to the detriment of vessel lining. Intercellular gap formation, which increases the microvascular permeability, results in edema and thrombosis.²²

Fluid is lost through a “capillary leak” in the burn wound and underlying tissue. The pathophysiology of the loss of capillary integrity is complex and only partially understood.²³ Local vascular damage is the direct result of heat applied to the tissues, but more profound vascular effects are related to both systemic and local factors. Endothelial cells swell, form gaps, and allow extravasation of fluid into the perivascular space. The altered cell transmembrane potential causes sodium to be drawn into cells, which consequently swell. At the same time significant hypoproteinemia causes a decrease in capillary hydrostatic pressure and plasma oncotic pressure, with a corresponding increase in interstitial oncotic pressure.

Any injury, and burns are no exception, elicits a massive systemic inflammatory response “in which cytokines and other metabolic products of activated leukocytes can act either beneficially to provide for enhanced host resistance or deleteriously to depress the function of remote organs.”²⁴ Local tissue trauma, ie, the burn, activates the release of an array of systemic mediators such as complement, arachidonic acid, and cytokines, particularly IL-1 and TNF. A number of local mediators, including oxidants and arachidonic acid metabolites, appear to be involved in burn edema.²⁵ These local mediators of inflammation also influence the production of systemic mediators, with resultant increases in substances such as PGE₂. Hypermetabolism develops along with muscle catabolism, all common to the large cutaneous burn victim.

Experimental administration of catalase and superoxide dismutase, two antioxidant enzymes, is associated with less edema and decreased fluid requirements in burns.²⁶ Vitamin C and platelet activating factor (PAF) show similar effects.^{27,28} Therapeutic manipulation of monoclonal antibodies against neutrophil membrane glycoprotein CD-18 (important in neutrophil adhesion to microvascular endothelium) is being evaluated in clinical trials.²⁹

Inhalation Injury

Some 10%–20% of all hospitalized burn patients have an associated inhalation injury. The consequences of such injury are not only to increase fluid requirements during resuscitation³⁰ but also to increase mortality significantly.^{31,32} An inhalation injury can damage all levels of the respiratory tract, from the oropharynx—evidenced by airway edema and occlusion—to the lung—where it manifests as alveolar derangement with associated acute respiratory distress and bronchopneumonia.

Any patient who has had smoke exposure is suspected of having inhalation injury. A history and physical examination, coupled with laboratory tests and bronchoscopy, aid in identifying those patients at risk for developing pulmonary problems. The typical clinical profile is that of a patient who was burned in a closed space and who inhaled smoke, has a facial burn, singed nasal hairs, erythema, and carbonaceous material in the back of the throat. Bronchoscopic findings are those of erythema and sooty deposits in the airway.³³ In addition, the carboxyhemoglobin level may be elevated (>15%) and hypoxemia may or may not be present.

The treatment of a patient with inhalation injury is supportive.^{34–36} The upper airway must be protected. Prophylactic intubation is indicated when there is a question of upper airway edema and swelling.³⁷ Either nasotracheal or endotracheal intubation is preferable to early tracheostomy.³⁸ Once an airway is made secure, ventilation should be gently maintained using a volume ventilator. Prophylactic antibiotics and steroids are not indicated. Again, greater than predicted fluid requirements are the rule rather than the exception in patients with inhalation injuries.

Due in part to the success in reducing the incidence of sepsis, early surgery and fluid resuscitation, and new advances in nutritional support, pulmonary failure has emerged as one of the leading causes of mortality in burned children. Barrow and colleagues³⁹ reviewed the records of 3179 burned children admitted to the Shriners Hospitals for Children in Galveston, Texas, from 1985 to 2001. The authors sought to evaluate the effect of pulmonary injury, age, sex, race, and burn size on mortality. Children up to 3y with ≤20% TBSA burns had a 10% mortality rate, compared with rates of 5% for children 3–12 and 4% for 13–18. Children of all ages with 21–80% TBSA burns plus inhalation injury

had a mortality rate of 14%, compared with 3% mortality for those with burn only. The authors conclude that inhalation injury remains one of the primary contributors to burn mortality. Children <3y are at a higher risk both with and without inhalation injury.

ACUTE BURN SURGERY

Escharotomy and Fasciotomy

The circumferentially burned extremity is at risk for becoming vascularly compromised. Continuous evaluation of the peripheral circulation is mandatory for the first 24–48h. The Doppler flowmeter is the only reliable means of doing this, as the physical signs of arterial insufficiency are obscured either by overlying burn or tissue edema.⁴⁰

Numbness and tingling of the limb are the earliest signs of ischemia. Arterial flow in the upper extremity must be assessed in the superficial palmar arch of the hand as well as in the ulnar and radial arteries. The development of an “intrinsic minus” hand is an indication for decompression of the deep muscle compartment of the hand. Decompression of this compartment involves making three radial incisions in the dorsum of the hand then bluntly dissecting deep into the hand with a hemostat. Both medial and lateral incisions are required for decompression of the arm and leg.

Occasionally chest escharotomies are required to permit appropriate ventilatory expansion. Figure 2 illustrates the preferred escharotomy sites.

Excision

The surgical principles of burn care are

- preservation of life
 - prevention and control of infection
 - conservation of all viable tissue
 - maintenance of function
 - timely closure of the burn wound
- Early burn wound closure is instrumental in fulfilling the first four principles.

Since Janzekovic's classic paper in 1970,⁴¹ a number of articles have been published both for and

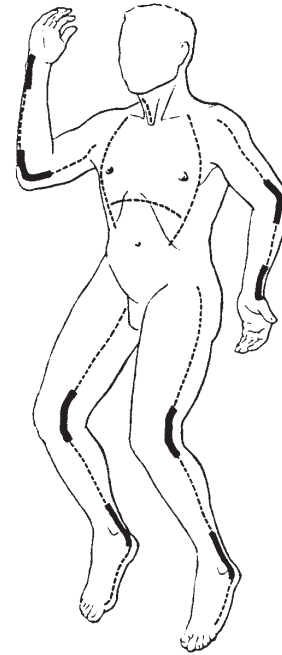


Fig2. Preferred sites for escharotomy. (Reprinted with permission from Moylan JA Jr, Inge WW Jr, Pruitt BA Jr: Circulatory changes following circumferential extremity burns evaluated by the ultrasonic flowmeter. An analysis of 60 thermally injured limbs. *J Trauma* 11:763, 1971.)

against early excision of partial and 3° burns. Most burn surgeons currently favor early excision and grafting of burn wounds. The only caveat to this practice is that a wound must not be excised unless it can be immediately closed. Sheridan and colleagues⁴² review the technique and outcome of prompt excision and closure of burn wounds.

Does early excision of large burns have any effect on morbidity and mortality? Cryer and others⁴³ noted markedly improved survival of patients 41–60yo with burns over 20%–65% TBSA treated with early excision and grafting. Early wound closure may decrease overall mortality⁴⁴ but does not change the patterns of morbidity or causes of death of patients who die more than 3 days postburn.⁴⁵

A retrospective study from the Shriners Burns Institute⁴⁶ in Galveston failed to confirm the benefit of massive burn wound excision. Pediatric patients whose burns were <50% TBSA showed no significant change in length of stay, blood requirements or mortality. Patients with burns >50% TBSA (without inhalation injury) had decreased mortality when their burn wounds were excised early.⁴⁶ As the size of the burn injury increases beyond 20% TBSA,

the importance of surgical excision of burns becomes more difficult to quantify.⁴⁷

Herndon and Parks⁴⁸ compared serial debridement and autografting of burns with early massive excision and coverage by cadaver skin in the treatment of burns. The latter protocol consisted of wound excision to fascia in the first 3d postburn, followed by immediate coverage with meshed autograft overlaid by ABO-matched fresh or frozen allograft. The authors found no difference in patient survival with either treatment. The only tangible improvement of early excision and allograft placement over conventional treatment was a decrease in hospital stay and interval to final wound coverage. Differences in the number of procedures, operating room time and blood loss between the two groups were not statistically significant.⁴⁸

Tangential or full-thickness excision into fat or to fascia should be performed with the Humby knife under tourniquet control to prevent massive blood loss.⁴⁹ Full-thickness excision to fascia is ideal for minimizing blood loss in areas such as the back and chest, but is cosmetically unsightly.⁴⁵ The cosmetic deformity created by excision to fascia is of such magnitude that tangential excision into fat is preferable in these cases. When operating on preadolescent females, the nipple and underlying breast tissue should be preserved whenever possible.

Excellent functional results are reported after early excision of deep hand burns.⁵⁰

The decision to undertake early eschar excision in patients with inhalation injuries presents a clinical dilemma. Early excision is probably warranted in burn patients who have inhalation injury or chronic obstructive pulmonary disease⁵¹ if the following conditions are met:

- pulmonary function can be maintained
- the patient is hemodynamically stable
- operating room and body temperatures are kept above 37°C
- anesthesia time is limited to 2h
- no more than 25% TBSA is excised at one time

Closing the Burn Wound

In the interim between admission to the burn center and grafting session(s) under anesthesia, patients benefit from having their burn wounds

closed for relief of pain and to avoid infection. In the absence of sufficient autograft, the standard for wound closure after massive burn excision is cadaver allograft.

Janzekovic⁴¹ noted better esthetic and functional outcome of burn scars with early excision and grafting than with conservative management. Jonsson and Dalsgaard⁵² note faster healing and less scarring when early tangential excision and grafting is used in the face. Selection criteria for early excision of burns of the face include wounds expected to take >3 weeks to granulate spontaneously. Only deep dermal and subdermal burns are excised. Split-thickness skin grafts must be 0.012–0.014in thick. The authors believe that conservative management can lead to necrosis of the dermis from infection or desiccation, eventually yielding a hypertrophic scar, whereas early excision and grafting improves the outcome.

An excellent study by Fraulin and colleagues⁵³ demonstrates that early tangential excision and grafting of the face results in better scars compared with prolonged spontaneous granulation.

Hypertrophic scarring after burns remains a major and frequent problem. Pressure garments are commonly used as treatment even though there is little sound data that they reduce the prevalence or magnitude of the scarring. A review of the literature by Bombaro and associates⁵⁴ clearly showed that the prevalence of hypertrophic scarring is really unknown. Their own retrospective study of 110 burn survivors of all races found the prevalence of hypertrophic scarring to be 67%, which conflicts with the published reports and suggests that further research is necessary.

Numerous physiologic dressings have been developed^{55–59} to temporarily cover the burn wound until definitive closure can be managed. The advantages and disadvantages of some of the most popular dressings in use today are listed in the Appendix. An attractive though expensive alternative is Integra Dermal Regeneration Template, which is applied to fresh, clean, surgically excised burn wounds.⁶⁰ Within 2–3 weeks the dermal layer regenerates and a thin epidermal autograft can be placed. The median take rate of Integra in a multicenter clinical trial was 95% and the median take rate of the epidermal graft was 98%.⁶⁰

Dealing with Infection

Before the advent of effective topical antimicrobials, partial-thickness burns frequently became infected and converted to full-thickness injuries. Twenty-five years ago silver nitrate, mafenide acetate, and silver sulfadiazine were introduced and changed the epidemiology of burn wound sepsis.⁶¹

The use of prophylactic antibiotics such as penicillin offers no protection against the development of either cellulitis or burn wound sepsis, but does promote the selection of antibiotic-resistant bacteria.⁶² The importance of environment in the spread of infection cannot be overemphasized. McManus and associates⁶³ report a profound decrease in gram negative bacteremia when burn patients were moved from open wards to single-bed isolation environments where no cross infection or colonization by endemic resistant bacteria occurred.

Burn wound sepsis is defined as $>10^5$ organisms per gram of tissue. Bacteremia is not synonymous with burn wound sepsis, and many “clinically septic” patients never have evidence of bacteremia.⁶⁴ Serial blood cultures are often negative in the presence of burn wound sepsis, and positive burn wound cultures are generally not recovered until 5–10d after proven heavy bacterial wound infection.

Group D streptococci (*Enterococcus spp*) are important pathogens in the severely burned patient. Secondary enterococcal bacteremia has been associated with 50% mortality.⁶⁵ Once blood cultures are positive, therapeutic intervention appears to have little effect on mortality.

Fungi and yeasts are often late colonizers of the burn wound. Pensler⁶⁶ reported 32% mortality among 72 patients with fungal sepsis. Changes in topical antimicrobial therapy did not influence survival, and broad-spectrum antibiotics should not be used without specific indications in burns. Once fungal invasion was diagnosed by histology, the patients were taken to the operating room for surgical debridement.

Infection is the leading cause of death in burn patients, but over the past 25 years the primary cause of death has shifted from invasive burn wound infection to bronchopneumonia.⁶⁷ Merrell⁶⁸ showed a significant decrease in postburn septic mortality to 0.7% by successfully managing infection in burn patients. Susceptibility to infection increases with the extent of burn injury, especially when $>30\%$ TBSA. Other risk factors include⁶⁹

- 3° or deep 2° burns
- patient age <16 or >60 y
- preexisting disease (diabetes mellitus, COPD, malnutrition)
- a hot, moist wound environment
- impaired blood supply (shock, thick avascular eschar)
- low wound pH

Robson,⁷⁰ Luterman and others,⁷¹ and Pruitt and McManus⁶⁷ provide excellent overviews of burn sepsis and its control.

A case-control study of the attributable direct costs of infection with multidrug-resistant *Acinetobacter baumannii* in the burn unit of a public teaching hospital⁷² showed the total hospital cost for care of these patients to be \$98,575 higher than that of control patients with identical burns. The cost-effectiveness of specific interventions designed to control this emerging nosocomial pathogen becomes clear.

BURNS IN CHILDREN

Physicians involved in pediatric burn care are urged to familiarize themselves with the typical signs of inflicted injuries so that they may recognize them and intervene appropriately. Approximately 10% of burned children admitted to hospitals have purposely inflicted injuries, primarily scald burns. These injuries can often be recognized by their patterns and distribution.⁷³ Data from a regional burn center in Washington⁷⁴ reveal bilateral lower extremity tap water immersion scalds occurred in 100% of abusive and 29% of unintentional injuries. Likewise, buttock/perineal immersions were more common with abuse than with unintentional injury. Craniofacial immersion injury was infrequent and its etiology equivocal.

Scalds caused by children pulling a grease fryer onto themselves result in more extensive and deeper injuries and greater consumption of hospital resources than those from other liquids. For example, in one study 56% of children burned with grease required skin grafting, compared with only 34% of those burned by other liquids, and 20% of patients burned by grease required ventilator support vs 6% of those with non-grease burns.⁷⁵

Foglia and associates⁷⁶ at St Louis Children's Hospital reviewed the records of children with burns admitted to their facility between 1993 and 2002. Data collected included sex, age, burn depth and TBSA, inpatient days, and outpatient visits. Outcome measures included length of stay, incidence of infection, and hospital charges. Analysis revealed a significant reduction in resource utilization and a low incidence of infection despite increased numbers of patients. This was due in large part to a shift to ambulatory burn care and the introduction of procedural sedation over that decade.

IMMUNOLOGIC FUNCTION

Virtually every aspect of the immune system is disturbed by the burn injury. Humoral as well as cell-mediated immunity is impaired and manifests as depressed levels of immunoglobulin, reduced activation of complement to form membrane-attacking complexes,⁷⁷ and diminished stimulation of lymphocyte proliferation and response. Therapeutic interventions to enhance the immune state are still experimental. "The redundancies of the cell populations and the cytokines and other metabolites produced by the cells predictably limit the effectiveness of any single agent and make clinical evaluation of such agents difficult."⁷⁸

METABOLISM AND NUTRITION

All large burns are associated with hypermetabolism. The metabolic rate can exceed 200% of normal in extremely large or septic burns.⁷⁹ This increase in metabolic rate is proportional to burn size up to approximately 60% TBSA, leveling off thereafter. Decrease in wound size either by spontaneous reepithelialization or by excision and grafting does not appear to change energy expenditure in a predictable manner.^{80,81} An excellent overview of nutritional support in the burn patient is presented by Waymack and Herndon.⁸²

Formulas recommended for calculating the metabolic requirements of hospitalized patients do not apply to burn patients whose clinical status is in constant flux. Although a number of formulas have been devised for estimating nutritional requirements in burn patients, it is possible to quantify actual energy expenditure by indirect calorimetry using a portable unit.^{83,84} Indirect calorimetry helps

identify patients who receive either too much or too little nutrition and allows for prompt correction. The measured energy expenditure (MEE) at rest reveals that a mean nutritional intake 1.4X the estimated energy expenditure (EEE) is associated with satisfactory maintenance of body weight in the majority of patients. Using measured energy expenditures,⁸⁵

$$EEE(v) = 1925 - 10(A) + 5(W) + 281(S) + 292(T) + 851(B)$$

$$EEE(s) = 629 - 11(A) + 25(W) - 609(O)$$

where EEE = estimated energy expenditure (kcal/day); v = ventilatory dependency; s = spontaneously breathing; A = age (y); W = body weight (kg); S = sex (male 1, female 2); T = 1 for diagnosis of trauma; B = 1 for burn; and O = 1 for obesity.

Pediatric burn patients have very different energy requirements from those of adults, and their diets should be adjusted accordingly.⁸⁶ Bell and others⁸⁷ found that most burned children maintained 90% of their pre-morbid body weight when given caloric intakes of basal metabolic rate X2 (Wolfe's formula⁸⁸) in conjunction with a generous protein intake and aggressive early excision and grafting procedures.

The daily protein requirement can be met with 1–2g/kg body weight/d for adults and 2–3g/kg/d for infants.⁸⁹ Fat emulsions are best limited to 4g/kg/d because of the inability of the liver to clear fat more rapidly. Diets that have a nonprotein kcal:nitrogen ratio of 100:1 promote a positive energy balance.⁹⁰

Excessive glucose administration is detrimental to burn patients. Unlike normal persons, burn patients appear to have an upper limit of glucose utilization of approximately 6.2mg/kg/min, which represents about 60%–70% of a burn patient's caloric requirements. Excessive glucose is converted to fat, while excessive carbon dioxide and water production may cause fluid overload or inability to wean the patient from mechanical ventilation.

When possible the gastrointestinal tract should be used to provide the needed nutrition because spontaneous food intake appears to be close to preinjury level. Enteral tube feeding is frequently necessary in burn patients.

TOXIC EPIDERMAL NECROLYSIS

Toxic epidermal necrolysis (TEN) is characterized by epidermal sloughing, usually in conjunction with mucosal inflammation and ulceration. The

epidermis separates at the epidermis-dermis junction, and the extent of slough varies from minimal to 100% TBSA. The precipitating event is uncertain, but TEN may follow nonspecific infections or drug administration. Commonly implicated drugs include phenobarbital, diphenylhydantoin, sulfonamides, various antibiotics, and nonsteroidal anti-inflammatory agents.

While spontaneous reepithelization does occur following an episode of toxic epidermal necrolysis, the reepithelialization process is *very slow*, so that patients whose epidermal slough is greater than 10% TBSA are best treated in a burn center.

The management of TEN wounds is very similar to that of burn wounds. Appropriate fluid resuscitation, nutritional support, and prevention of infection are the goals of therapy. Early wound debridement and coverage with a biologic dressing (allograft, xenograft or Biobrane) give excellent results.^{91,92} Corticosteroids are *not* recommended because of the increased risk of infection.⁹³

NECROTIZING FASCIITIS

Necrotizing fasciitis is a soft tissue infection that causes necrosis of subcutaneous tissue and fascia but usually spares skin and muscle. Management consists of early diagnosis, broad spectrum antibiotic coverage, aggressive surgical debridement, wound closure, and intensive supportive care administered at a burn center. In a study of 12 patients with necrotizing fasciitis, Redman and colleagues⁹⁴ report that 4 (33%) died of multiorgan failure. Their findings suggest that early referral to a burn or wound care center improves patient outcome.

SPECIAL BURNS

Electrical

An electrical injury occurs when electricity is converted into heat as it travels through tissue.⁹⁵ Acute electrical injuries constitute the primary reason for hospitalization in about 2% of admissions to a burn center. Approximately 15% of these patients have associated multiple trauma.

In a 20-year review from Parkland Memorial Hospital's Burn Unit,⁹⁶ work-related activity among linemen and electricians was responsible for the

majority of high-voltage injuries, which were also associated with the highest rate of complications, longest stays in the hospital, and greatest number of operations required. High-voltage injuries have far reaching social and economic impact because they tend to affect younger men in the prime of their working lives.

Although the mean cutaneous injury is only 10%–15% TBSA,⁹⁷ the cutaneous injury usually does not reflect the presence of deep tissue damage. Muscle damage should be suspected if the urine is grossly pigmented (light pink to deep brown). Damaged muscle is most commonly found directly underneath or adjacent to contact points, but the exact location and extent of the muscle damage can be ascertained with a technetium-99m stannous pyrophosphate muscle scan.⁹⁸

The fluid replacement needed for resuscitation is calculated from the size of the cutaneous injury plus an undetermined additional amount when muscle damage is present. If gross urinary pigment is present, 2 ampules of sodium bicarbonate and 2 ampules of mannitol are initially given in addition to intravenous Ringer's lactate. Further use of diuretics is avoided. Urine output should be maintained at 100–125mL/h until clear.

Acute electrical injuries may precipitate cardiac arrhythmia, which is nearly always diagnosed before or during admission. Routine cardiac monitoring is not necessary unless the patient suffered cardiac arrest at the scene of the accident, has an abnormal electrocardiogram, or arrhythmia was documented during transport.⁹⁹ Vigorous resuscitation, continuous hemodynamic and metabolic support, and early aggressive surgical intervention limit mortality in patients with electrical injuries to the heart.¹⁰⁰

Muscle injury is often associated with the development of increased compartmental pressures and decreased peripheral perfusion, and therefore the status of the soft-tissue compartments should be continually evaluated for the first 24h. Fasciotomy is selectively performed on the basis of clinical symptoms and should be done in the operating room with the patient under general anesthesia.¹⁰¹ Regional anesthesia should be avoided. Initial operative debridement is carried out 24–48h after injury. Exposed neurovascular bundles, tendons, and bone must be covered early with either remote or local muscle flaps. Mafenide acetate (Sulfamylon®) is the antimicrobial agent of choice for

the contact points and areas of deep injury by virtue of its excellent tissue penetration and anti-gram-negative bacterial action.

Chemical

Chemical burns can be roughly classified as those involving alkalis, acids, or special chemicals. Alkaline substances such as sodium and potassium hydroxides and cements are the most common causes of chemical burn.¹⁰² Chemical agents usually injure the skin by direct chemical reaction rather than by production of heat, but inadequate irrigation or neutralization may cause a thermal burn to compound the original chemical injury.¹⁰³ Immediate treatment consists of lavaging the area with copious amounts of tap water.

The severity of a chemical burn is often underestimated on first examination.¹⁰⁴ Care of the patient burned by a specific chemical substance is discussed by Broughton in *SRPS* volume 10, number 7, part 1.¹⁰⁵

POSTBURN RECONSTRUCTION

Feldman¹⁰⁶ lists the basic tenets of reconstruction after a burn, as follows:

- Analyze the deformity and note distorted and absent tissue.
- Generate a long-range plan for reconstruction that establishes priorities and addresses both functional and esthetic concerns.
- Delay reconstruction until the scars and grafts have matured. Use splints and elastic garments to minimize scar hypertrophy.
- Release extrinsic contracture before intrinsic contracture.
- Orient scars parallel to relaxed skin tension lines.
- Identify and ration potential donor site skin.
- Resurface according to regional esthetic units. If possible, adjacent units should be covered with a single large graft to avoid seams between territories.
- Match donor skin according to thickness, color, and texture. Thicker skin grafts lead to less post-operative contracture.

- Protect new scars and grafts from ultraviolet radiation to decrease the chance of hyperpigmentation.

RECONSTRUCTIVE LADDER

Direct closure is the simplest form of scar revision. The releasing incision should be oriented so that the new scar falls within the lines of minimal skin tension. Tension on the wound closure is unacceptable.

Adjacent tissue transfer (Z-plasty) is particularly helpful in burn surgery because there is an overall gain in length along the scar after the skin flaps are rotated. Understanding the geometry of the Z-plasty is paramount. The limbs must be of equal length with identical angles. Rohrich and Zbar¹⁰⁷ review the Z-plasty and its many uses.

Skin grafts provide skin when local tissue is simply inadequate. Full thickness skin grafts (FTSG) are preferred because they prevent future tissue contracture by virtue of the inhibitory properties of the transferred dermis. Split thickness skin grafts (STSG) are commonly used for large-surface defects, but STSG tend to shrink considerably, leading to secondary wound and burn wound contracture. The donor site skin should be of similar texture and color to that of the recipient site; hair-bearing skin should be transferred only when appropriate or unavoidable. Grafted skin should be transferred in sheets and used to replace entire esthetic units (Fig 3), as Gonzalez-Ulloa recommends.¹⁰⁸

Tissue expansion facilitates reconstruction when similar skin is desired to cover a defect. By expanding the skin peripheral to the scar, sufficient skin of ideal color, texture, thickness, and sensation can be obtained while minimizing the donor defect. A major disadvantage of tissue expansion is the need to have at least two surgical procedures. Although the technique is straightforward, there is a risk of complications including exposure or extrusion of the tissue expander, neuroapraxia, pain, and infection.

A study by Youm¹⁰⁹ illustrates the problems of tissue expansion in a public hospital. Complications occurred in 65% of the 34 expanders in their series. Major complications included deep infection (32%), exposure (21%), and deflation (3%), resulting in premature removal of 13 expanders (38%). Minor complications occurred in 9 (27%) and consisted of

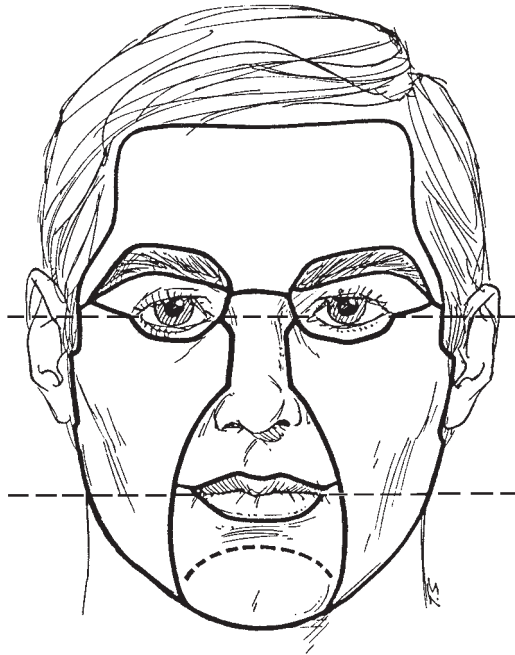


Fig 3. Regional esthetic units of the face. (Modified from Gonzalez-Ulloa M: Restoration of the face covering by means of selected skin in regional aesthetic units. *Br J Plast Surg* 9:212, 1956.)

wound dehiscence, cellulitis, and drainage. Risk factors for major complications in this series were pediatric patients and placement of multiple expanders.

A report from Children's Medical Center in Dallas confirms this observation.¹¹⁰ Friedman and colleagues¹¹⁰ demonstrate an increased risk of failure when placing tissue expanders in children <7yo. Other risk factors uncovered by this study include the use of internal ports with the tissue expanders and a history of at least two prior expansions.

The use of **pretransfer tissue expansion followed by microvascular free tissue transfer** increases the versatility of both techniques. Not only is a large amount of vascularized tissue available for the burn scar defect, but donor site closure is also possible. Entire esthetic units can be replaced with this technique. Spence¹¹¹ describes using tissue expansion at FTSG donor sites prior to harvest to obtain large amounts of skin and still close the donor site primarily. The transferred skin behaves like a regular FTSG.

Flaps are indicated in burn patients who have exposed bone, tendon, or cartilage, particularly in

an extremity, and in patients whose wounds cannot be covered by other means.¹¹² The flaps used in reconstruction may be pedicled or freely vascularized, musculocutaneous or fasciocutaneous. Age is not a contraindication to free flap use. Free flaps offer single stage reconstruction with rapid transfer of tissue, early wound closure, early mobilization, and decreased hospitalization. Free flaps also allow for better esthetic contouring than pedicled flaps.

Platt and associates report that of 604 patients who required surgical intervention for burns from 1989–93, only 1.5% needed free tissue transfer.¹¹³ The rate of flap loss in these patients was higher than the average in a non-burn population. The authors believe that incomplete debridement and poor recipient site vessels led to the higher rate of failure in burn patients. On the other hand, Abramson and colleagues¹¹⁴ performed 45 free-tissue transfers in 35 burn patients during a similar period (1987–1994) and report 96% flap survival.

RECONSTRUCTION BY ANATOMIC SITE

Scalp

The redundant vascularity of the scalp allows for several options in burn wound closure. Primary closure can close defects 2–3cm in diameter. Skin grafts will result in alopecia and abnormal contour, but have excellent take and are technically easy. If small portions of cranium are exposed, the outer table of the cranium can be removed to expose the blood vessels of the central diploe and allow grafting over it.

Local flaps are used to cover small to medium sized defects (4–10cm diam). Wide undermining and galeal scoring can be used to stretch the flap further—approximately 1–2mm extra for each galeal incision.

Burn alopecia differs from hereditary hair loss in that the scalp is tight, thin, and poorly vascularized secondary to burn cicatrix. Despite these obstacles, there are reports of successful hair micrografting in burn patients directly into scar.^{115,116} If burn scar excision is required and the resulting defect is small, it may be closed using classic rotational flaps as described by Juri¹¹⁷ and Orticochea.¹¹⁸ A common problem with these techniques is improper hair follicle orientation.

Tissue expansion is an ideal method of reconstruction in large areas of burn alopecia encompassing up to 50% of the scalp. The transferred hair is of similar texture and color and the scars are easily camouflaged. Tissue expansion is commonly used for secondary reconstruction of the scalp to replace grafts or correct unesthetic primary repairs. Expanders are placed in the subgaleal plane and expanded weekly for 2–4mo, after which time the expanded tissue is advanced, transposed, or rotated to fill the defect.¹¹⁹ Negatives of tissue expansion include prolonged treatment duration, temporary external disfigurement from the expanders, and multiple surgical procedures.^{120,121}

Larger burns may require free tissue transfer for appropriate coverage, especially when there is calvarial or dural involvement. Free flaps are typically used for very large defects, defects high on the vertex of the scalp, or those involving bone resection. Classic choices include the parascapular flap, the radial forearm free flap, and the latissimus dorsi flap.^{122–124} An omental free flap has also been successfully used to cover large areas of burned scalp.^{125,126} When osteomyelitis of the calvarium is present, a free muscle transfer is superior to a fasciocutaneous transfer because of the recognized scavenger effect of muscle.

Forehead

Inelasticity of the forehead soft tissue limits primary closure to defects 2–3cm wide. For small burns of the forehead, primary excision with direct approximation or transfer of adjacent tissue is best.

When more than 50% of the forehead is involved in the burn, resurfacing of the *entire esthetic unit* with a thick STSG or FTSG leads to a good reconstructive result. The forehead esthetic unit extends from eyebrows to hairline and to the outer canthi bilaterally. Only thick skin grafts should be used because of esthetic concerns with stepoffs and mismatched skin. Care must be taken to preserve the temporal branch of the facial nerve during dissection.

Local flaps can be used for select small defects (2–3cm) oriented along normal skin tensions lines to minimize distortion.

Tissue expansion is a reasonable option for secondary correction of deformities no greater than

50% of the forehead. The expander is placed under the frontalis muscle.

Free tissue transfers are for defects larger than one third of forehead area. The radial forearm fasciocutaneous flap is a practical choice because it is thin and pliable. When exposed bone is present, free tissue transfer or Millard's crane principle¹²⁷ is required. The crane principle calls for a scalp flap to be rotated into the defect and allowed to mature for 2–3 weeks, at which time it is returned to its native position at the donor site while leaving soft tissue over the previously exposed calvarium. The soft tissue is allowed to granulate for 5–7d and the site is then grafted.

Ear

Undermining and primary closure of ear defects is possible only on the posterior surface, where the subcutaneous layer allows the skin to slide over the underlying perichondrium. Small helical defects with intact cartilage can be repaired with linear layered closures. Primary closure can also be used for larger defects with missing cartilage by trimming the exposed cartilage, so long as the patient can accept the size discrepancy this creates.

Defects on most aspects of the helix can be repaired by wedge excision and closure. The inner angle should be 30° to minimize dog ear creation. For larger defects, full-thickness Burrow triangles can be excised superiorly and inferiorly to form a star¹²⁸ and the wedge is closed in layers with vertical mattress sutures. The helix must be meticulously realigned to prevent notching. The ear wedge always makes the ear smaller. Larger ears can tolerate larger wedge excisions and vice versa.

Small defects can heal by second intention whether or not the perichondrium is intact. If the perichondrium is absent, small holes should be made through the cartilage to facilitate healing from the posterior skin. Concave or flat surfaces are ideal for second intention healing because the resultant scar is usually slightly depressed. If the defect extends into the external auditory canal, an STSG should be placed to prevent strictures of the canal.

Skin grafts are useful in covering a wide variety of ear defects. If the perichondrium is present, a full-thickness skin graft can be applied. Donor sites include the retroauricular, preauricular, contralateral postauricular sulcus, and supraclavicular skin.

If the perichondrium is missing or damaged, split-thickness skin grafts may be used, although the color and texture match may not be as good as with other methods.¹²⁹ STSG can be applied directly onto the cutaneous vascular bed of the opposite auricular surface after the remaining cartilage is excised. There is enough structural support even without the cartilage. Grafts placed in the concha should be generously sized to compensate for the profound concavity.

Defects confined to the helix with or without a cartilage defect can also be repaired with the chondrocutaneous advancement flap (Antia-Buch).¹³⁰ Defects up to 2.5cm diameter can be successfully treated in this manner. Details of flap indications, design, elevation, and transfer can be found in SRPS volume 9, number 16.¹³¹

Defects on the superior aspect of the helix are ideal for repair with banner transposition flaps. Originally described with postauricular skin, the flaps can also be raised from the loose preauricular skin. The flap base is superior to and contiguous with the defect, over which it is draped. The transposition flap can be converted to a tubed pedicled flap if the defect is not immediately adjacent. Other options in ear reconstruction are detailed in SRPS 9(16).¹³¹

The biggest concern regarding burns of the ear is suppurative chondritis caused by *Pseudomonas*. Prevention is far preferable to treatment, and consists of topical Sulfamylon for its deep eschar penetration.¹³² Protective ear cups are also helpful in preventing infection.

Symptoms of impending chondritis include severe ear pain, erythema, warmth, and edema. Once the diagnosis of chondritis is made, incision and drainage is mandatory and all necrotic tissue must be debrided. Scar excision is followed by reconstruction as above.

Cheek

Postburn contracture of the cheek is best corrected with a large full-thickness graft, a skin flap, or tissue expansion. The entire esthetic unit should be replaced to prevent a quilt-like appearance postoperatively. Care is taken to avoid traction on the lower lid that might cause ectropion afterwards.¹³³ Compression garments help decrease the likelihood of hypertrophic scar.

Eyelids and Eyebrows

The eyelids should take precedence in the reconstructive plan in order to protect the globe and preserve vision. Corneal exposure is a dreaded complication from burn and must be prevented. Lubricating drops and ointment must be used if necessary. Generally, tarsorrhaphy is inadequate in these situations because of the lack of sufficient unburned tissue to do the job properly.

Ectropion is the most common sequela of burn to the eyelid. To treat it successfully, the surgeon must differentiate between the causes of contracture. If the contracture is *external*, releasing incisions are required. These incisions are placed 1–2mm away from the ciliary margin, taking care not to violate the supratarsal fold while working in the upper eyelid. Skin deficiencies of the upper eyelid may be replaced with a FTSG harvested from the contralateral upper eyelid. A FTSG harvested from the retroauricular region works well to replace lower eyelid skin.¹³⁴

A variety of adjacent tissue transfers may also be used to replace missing skin of the eyelid after external contracture release. A modified Tripiet flap keeps the donor upper eyelid skin and orbicularis oculi muscle pedicled to the lateral canthal region, and can be used to resurface the lower eyelid.¹³⁵ A Fricke flap, which uses pedicled forehead skin in a similar manner, is also useful when replacing skin in the upper eyelid. The technique of regional resurfacing dictates use of separate skin grafts for each esthetic subunit around the eye.

Intrinsic contractures requires entire eyelid reconstruction. For burns of the upper eyelid, and only if the ipsilateral lower eyelid skin is of good quality, the Cutler-Beard¹³⁶ and Hughes flap methods¹³⁷ are excellent alternatives. For burns of the lower eyelid, Mustarde cheek advancement flaps¹³⁸ are suitable provided that unburned skin is available in the donor area. In the event that complex burns have destroyed all local tissue, reconstruction with temporoparietalis fascia pedicled flap or free flap may be required.¹⁴⁰

Eyebrow reconstruction is accomplished with either strip grafts or micrografts.^{115,116} Advances in hair transplantation and micrografting have improved graft survival despite the poor quality of the recipient bed. The surgeon must respect the esthetic landmarks of the eyebrow.¹⁴¹ Alternatively, vascularized island pedicle flaps from the temporal scalp

may be tunneled subcutaneously to the brow area.¹⁴² These flaps are based on the anterior branch of the superficial temporal artery. Follicular misalignment is a problem with this technique.

Tattooing has been suggested as an alternative to hair-bearing surgical flaps.¹⁴³ Although simple, this technique has obvious limitations.

Nose

The goal in the repair of nasal defects is to restore the natural appearance and projection of the nose and to maintain airway support. All three components of the nose need to be replaced by similar tissue. Primary closure is usually not possible.

Skin grafts yield good results in thin-skinned patients with defects of the upper two thirds of the nose, although full-thickness skin grafts can be used on the tip and lobule too. Donor sites for FTSGs include the nasolabial, preauricular, postauricular, supraclavicular, and upper eyelid skin, which provide good color match and an easily hidden donor site. Because of the sebaceous nature of the lower third of the nose, a FTSG may heal with a contrasting, shiny and flattened appearance.¹⁴⁴ It is best to excise enough normal tissue to allow replacement of an entire nasal subunit to avoid a patched appearance. Dermabrasion of the area 3 months after grafting will further improve texture match between the graft and its recipient site.¹⁴⁵

Flap options in nasal reconstruction are reviewed in *SRPS* volume 9, number 13.¹⁴⁶

Postburn scar contracture of the nose produces the typical facies of foreshortened nose with elevated tip and everted nostrils. Lesser burn scars can be excised within an esthetic unit and the resulting defect covered with FTSG. Severe contracture involves the underlying nasal skeleton, and the reconstruction must address all layers: the mucosa, the cartilage, and the skin envelope.

Since neighboring skin of the face is generally involved in the burn, adjacent tissue transfers are often impossible. Free flaps offer tissue for lining, support, and surface coverage in one operation.¹⁴⁷ Free flaps of retroauricular¹³⁹ or temporoparietal fascia,^{148,149} radial forearm,^{150,151} dorsalis pedis,¹⁵² lateral arm fascia,¹⁵³ and ear helix^{154,155} have all been reported in nasal reconstruction.

Lips and Perioral Region

Burn ectropion of the upper lip is released by incising both nasolabial folds and the base of the nose to let the lip fall back into its native position. As described by Gonzalez-Ulloa,¹⁰⁸ the regional esthetic unit of the upper lip extends from the nasolabial folds to the vermilion margin, to the nasal sill and columellar base, including the two nasojugal triangles. Within this unit are three subunits: the two lateral lip elements and the philtrum. Resurfacing must respect these subunits.

Mustache restoration is possible by using a composite strip graft from the scalp¹⁵⁶ or with a pedicled or free scalp flap based on the superficial temporal artery.^{157,158} Several authors^{115,116} have described microplug hair transplantation for burn patients with alopecia. Proper orientation of hair follicles is crucial to the success of this technique. See *SRPS* volume 9, number 15 for details of this and other techniques of lip and cheek reconstruction.¹³³

The lower lip and chin respond well to esthetic unit replacement. A sufficient quantity of soft tissue should remain on the pogonion for prominence of the chin and a sufficient amount of scar should be carved from the labiomental crease to mark this break. Unless associated contractures of the neck are also released, recurrence of lower lip ectropion can be expected.

Functional disabilities of the mouth resulting from lip ectropion include drooling, oral incontinence, constriction, feeding difficulty, and poor hygiene. Usually the lower lip is released first because contractures here are more disabling and contribute to extrinsic contractures of the upper lip.

True commissure burns are commonly seen when young children chew on electrical cords. Advances in oral splinting^{159,160} have been associated with improved outcomes when the wound is managed conservatively. Appliances are typically worn for 6–12mo. Younger children tend to fare poorly because treatment depends on the patient's cooperation. Patients and their families must be informed of the risk of subsequent labial artery bleeding, which may occur 7–10d after the injury as the eschar dries. When surgical reconstruction is required, the Gillies-Millard commissure repair¹⁶¹ or a V-Y advancement is indicated.¹⁰⁵ Other methods have been described that use mucosal transposition flaps or tongue flaps.^{162–164}

Neck

The skin of the neck is prone to flexion contracture, and burn scars here tend to produce significant extrinsic contracture of the lower face and mechanical disability. Mentosternal synechiae are not uncommon, and in children can lead to micrognathia.^{165,166} At times the mentosternal synechia is so severe that neck extension for endotracheal intubation is impossible. In these cases the neck scar should be released first under local anesthesia with intravenous sedation before attempting induction of general anesthesia.

A wide, isolated burn scar can be released by a single or multiple Z-plasties. Excision of all burn scar, including the platysma if appropriate, is mandatory. When incising platysma muscle, care must be taken not to injure the marginal mandibular branch of the facial nerve.

Large burn scars may require resurfacing with a skin graft. Either a thick STSG or a FTSG is applied to limit secondary contracture and recurrence of the deformity. Skin grafts are hidden under the jaw shadow or low on the neck when possible. Vertical scars are to be avoided.

When skin adjacent to the burn is available, tissue expansion is an option. Multiple expanders are best placed subcutaneously in the lateral neck or infraclavicular region. Ninkovic et al¹⁶⁷ successfully used preexpanded groin or scapular free flaps to improve esthetic and functional outcomes in the reconstruction of severe anterior neck burn deformities.

Postoperatively the patient is fitted with a neck splint to simultaneously extend the neck and mold its contour. Splinting is maintained for at least 6 months. Because both extension and pressure are important to the eventual functional and esthetic outcome, the splint may need frequent readjustment.

In the event of massive burn scars of the neck, contour is best restored with sheet grafts or large deltopectoral advancement flaps. Excellent results have also been obtained with free flaps, which require multiple defatting procedures.^{168,169}

Breast

Burns of the anterior chest wall in prepubescent girls can cause significant deformity and hamper subsequent breast development, partly from the

burn itself and partly from its treatment. When the nipple-areola complex (NAC) is directly burned, progenitor cells of the breast bud may be destroyed, but as long as the NAC is intact, breast tissue is likely to be undamaged, as the progenitor cells lie deep. Later, contracture of the skin envelope of the breast may impede normal breast development. Lastly, excessive debridement during acute burn care can aggravate the breast deformity.

The ideal time to reconstruct a young girl's breast is before the burn scar has constricted breast development. Neale and colleagues¹⁷⁰ describe the protocol of breast reconstruction in female burn patients. The breast mound should be fully released before growth is restricted. The breasts should be outlined bilaterally to plan a symmetric release, using any palpable mammary structures as landmarks for the release. Once the scar is released and the breast is sculpted, skin grafts are used to cover the defect. An inframammary incision will release most contractures, although superior and lateral incisions are sometimes indicated too.

For the postadolescent female with a burn of the breast, treatment follows a reconstructive algorithm based on the severity of the defect,¹⁷¹ namely:

1. If breast parenchyma is intact but asymmetric, local scar release is required. Maneuvers to obtain symmetry in cases of extrinsic contracture of the skin envelope include scar excision, Z-plasty, STSG, and FTSG.
2. If the breast parenchyma is burned, glandular volume becomes an issue. In these cases the reconstructive plan is similar to that of a postmastectomy defect, with the added complication that surrounding tissue is constricted and scarred from the burn, somewhat similar to a postradiation breast reconstruction. Tissue expansion and prosthesis placement, both with and without muscle coverage, can be considered, although the esthetic outcome is inferior because of poor surrounding skin quality. Breast reconstruction with a TRAM flap and contralateral breast reduction for symmetry are reliable options.
3. For adult women who were burned as children and failed to get adequate release of the breast scars during puberty, significant tissue expansion is often required. In these cases mammary development is likely to be impaired and a great

deal of volume is needed. Because the surrounding skin is typically contracted and of poor quality, expansion is plagued by problems such as skin ulceration, prosthesis exposure, necrosis of expanded skin, and prolonged course of expansion.¹⁷¹⁻¹⁷³

Ozgur and associates¹⁷¹ report 14% exposure rate of expanders in this setting and recommend liberal use of the latissimus dorsi muscle flap for coverage. Garner and Smith¹⁷⁴ stress the importance of covering the tissue expanders with muscle so as to essentially encase the expanders with padding to keep them from eroding through the thin, damaged skin.

Burns of the breast present similar challenges to the irradiated postmastectomy defect: skin of poor quality and a poor vascular supply. As in mastectomy, reconstruction with autogenous tissue is preferable when the patient is a good candidate for TRAM flap coverage. Slator and colleagues¹⁷⁵ opt for tissue expansion first, then release of contractures over the expander and reconstruction with thick STSG. The expander is left in place for several months to serve as a stent and counteract the contraction forces before inserting a permanent prosthesis. Neale and Kurtzman¹⁷⁶ disagree with this protocol and state that improved symmetry can only be obtained if the contracture is excised prior to tissue expansion. They support excisional scar release following subunit principles where possible to prevent a patchwork appearance.

An inframammary fold incision perpendicular to the chest wall creates a natural cleavage plane and allows for breast sculpting. Neale and Kurtzman¹⁷⁶ argue that if tissue expansion is still required, scar tissue has been removed already and expansion is easier.

Delayed nipple reconstruction is advisable. The technique is similar to that used in postmastectomy nipple reconstruction, with the added complication that the chest wall vascularity may be impaired. Medical tattooing of nipple and areola is a useful adjunct to the reconstruction.

Upper Extremity

Successful treatment of upper extremity burns requires an aggressive physical therapy program combined with surgical reconstruction when nec-

essary. Physical therapy is mandatory before commencing any postburn reconstruction. Therapy not only helps to decrease skin and joint contracture preoperatively, but is a useful predictor of patient involvement in the treatment postoperatively. Even in the face of a technically perfect procedure, all patients will experience postoperative contracture if physical therapy and joint splinting are not pursued appropriately. Elastic garments are also helpful during the recovery period.

Upper extremity contractures are best released in a proximal-to-distal direction, from axilla to fingers. Adduction contracture of the axilla is preventable through early splinting and range of motion exercises, yet remains a frequent problem in burns of the upper chest wall and arm. Kurtzman and Stern¹⁷⁷ describe three types of axillary contracture, as follows:

Type 1 contractures involve either the anterior (1A) or posterior (1B) axillary fold;

Type 2 contractures involve both the anterior and posterior axillary folds; and

Type 3 contractures involve both axillary folds and the axillary dome.

Type 1 and 2 injuries can be managed by sequential release and resurfacing with either thick STSG or FTSG. Type 3 injuries require large amounts of skin for resurfacing and are best reconstructed with well-vascularized, flexible, non-contracting flaps. A pedicled parascapular fasciocutaneous flap will do the job well and can be easily rotated into the axilla. The surgeon should avoid displacing the axillary hair and sweat glands during axillary reconstruction. Release of the axillary scar must be deep enough to penetrate through the burn scar to the normal tissue underneath. Postoperative physical therapy and splinting are essential to prevent recurrence of the contracture.

Roberts and Dickson¹⁷⁸ use fasciocutaneous flaps to resurface the axilla. Pitfalls of the technique include rotating the flaps through more than 90° and failing to undermine the flap adequately to allow easy rotation. Good donor sites of fasciocutaneous tissue include the parascapular and latissimus dorsi territories.^{179,180} These flaps are thin but sturdy, pliable, and reach the anterior axillary fold on their pedicles.

Burn scars of the elbow are best resurfaced with a thick STSG as long as there is no exposed bone,

cartilage, nerve, or vessel. When vascularized tissue is required, a fasciocutaneous flap such as a reverse radial forearm¹⁸¹ or reverse ulnar flap¹⁸² is indicated so long as adequate perfusion to the distal extremity is assured. Local, random fasciocutaneous flaps have been described based parallel to the longitudinal axis of the perifascial circulation.¹⁸³ In the event no local or regional fasciocutaneous tissue of suitable quality is available, free flap transfer may be contemplated. Muscle-containing flaps are generally too bulky to use in joints, and may interfere with elbow flexion.

Heterotopic ossification of the elbow is a recognized complication of upper extremity burn that produces an immobile joint. Treatment consists of surgical excision.

From a functional point of view, burns of the hand are devastating. It is far easier to prevent than to treat burn contractures of the hand. Aggressive and early tangential excision of the burned hand, combined with splinting and mobilization therapy, leads to improved long term results.^{184,185}

Recovery depends upon the depth of injury, adequacy of acute care given, and choice of reconstruction.¹⁸⁶ Permanent joint stiffness results from prolonged extremity edema with accompanying immobility, and must be avoided. Some authors support radical debridement with early free flap coverage¹⁸⁷ in the belief that rapid removal of damaged tissue decreases overall inflammation and produces a better functional outcome. The problem with this approach is how to identify damaged muscle at risk of necrosis. Schiller and colleagues¹⁸⁸ report using laser Doppler imaging to predict which wounds will be slow to heal.

The most common secondary deformity of the burned hand is postburn syndactyly. Many procedures have been devised to address this problem; none is completely successful. Alexander and associates¹⁸⁹ compare the various operations used to treat burn syndactyly in children including excision, Z-plasty, rotational flaps, VY-plasties, and skin grafts (Fig 4). No single procedure worked in all cases, and the authors describe a VM-plasty with postoperative splinting as an alternative (Fig 5).¹⁹⁰

A shortage of skin at the flexion creases manifests as contracture bands. Before the scar is released, the joint is manipulated to check for mobility. If the joint is supple, the scar bands are released with simple or multiple Z-plasties (Fig 6). Occasionally a

K-wire is required to help keep the digits in proper position. For the thenar web space, a four flap Z-plasty is appropriate (Fig 7).¹⁰⁷

Skin grafts are required to treat patients with severe skin shortage of the hand after a burn. Clinicians are divided regarding the merits of FTSG versus thick STSG versus tissue-expanded FTSG donor sites.¹⁹⁰ For cases requiring bone, cartilage, tendon, nerve, or vessel coverage, a pedicled or free fasciocutaneous flap is indicated.

When the joint is fixed and immobile because of adhesion of deeper tissues, simple scar release is inadequate for correction. These cases require joint capsulectomy with or without release of the scarred tendons,^{191,192} followed by early postoperative range of motion exercises and aggressive physical therapy.

Lower Extremity

Adequate care of lower extremity burns in the acute setting makes postburn reconstruction significantly easier. Early recognition of compartment syndrome can prevent limb loss. As in the upper extremity, many problems with joint contracture can be averted by early wound closure and aggressive physical therapy, to include both range of motion exercises and compression garments and splints.

When scar release is required, narrow bands are divided and lengthened with Z-plasty. Larger postburn contractures may require skin grafts to cover denuded areas after the scar is released. Long-term postoperative splinting, particularly at night, is necessary to prevent recurrence of contracture. Exposed vital structures should be protected and covered with flap tissue, either pedicled or transferred by microvascular anastomosis.¹⁹³ Chronic lymphedema is best managed by elastic compression garments.

Perineum

Operative procedures for perineal reconstruction range from contracture release to complete external genital reconstruction. As in other burn sites, the etiology of the distortion must be analyzed. Extrinsic contracture can be corrected with scar release and resurfacing. Meshed STSG are more pliable than standard sheet grafts and adapt better to the contour of the perineal region, but tend to contract more with time.

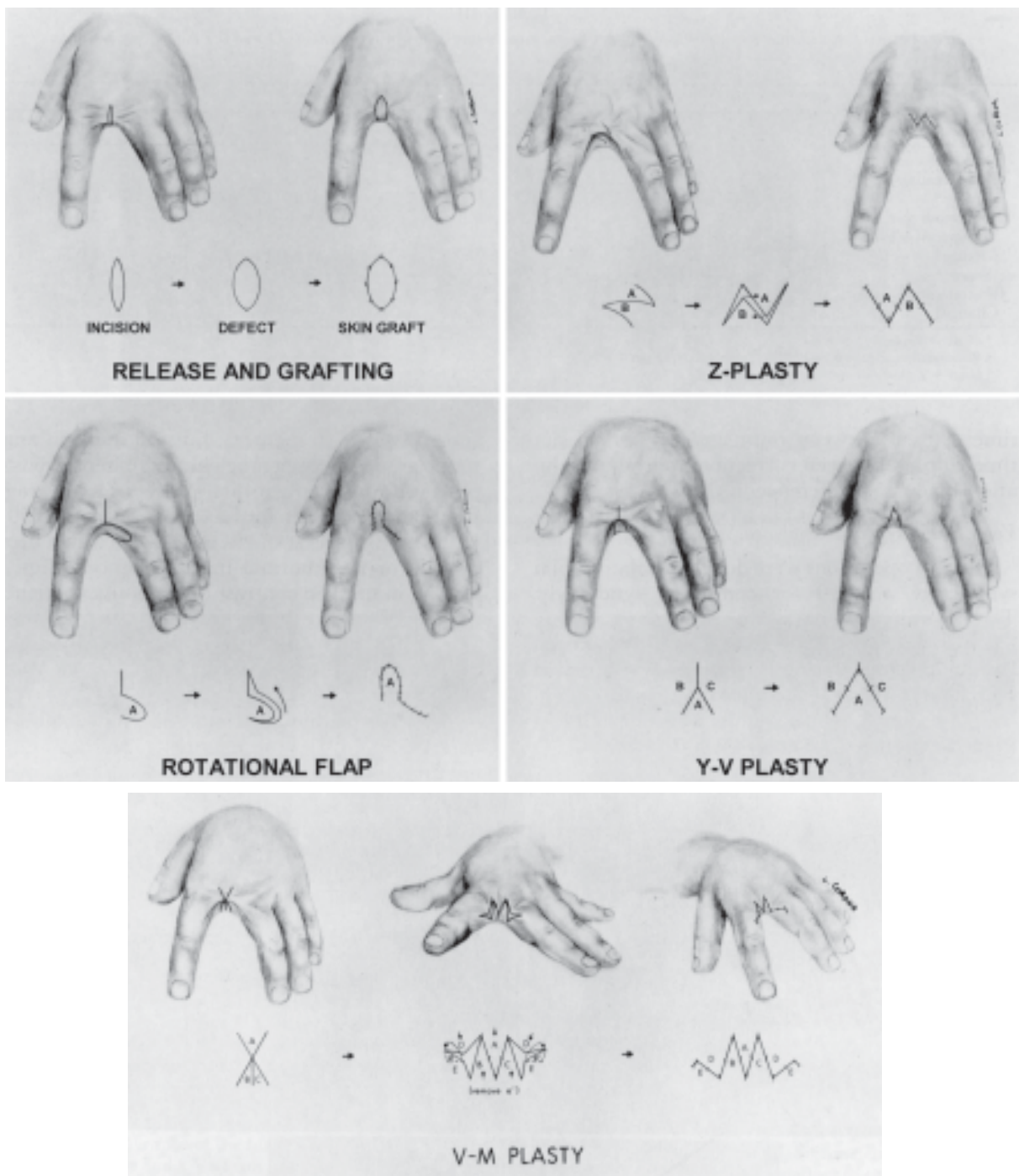


Fig 4. Various methods described to treat postburn syndactyly. (Reprinted with permission from Alexander JW, MacMillan BC, Martel L: Correction of postburn syndactyly: an analysis of children with introduction of the VM-plasty and postoperative pressure inserts. *Plast Reconstr Surg* 70:345, 1982.)

Sheet grafts, if bolstered properly, give a good esthetic result. Isolated scar bands may be released by Z-plasty.^{174,194}

Surgical reconstruction of the external genitalia is a complex and sophisticated undertaking. Of

particular importance is the creation of a neourethra. In male patients the available techniques include multistaged, tubed pedicle flaps,¹⁹⁵ axial musculocutaneous flaps, and free flaps.^{196,197} A penile prosthesis to allow erectile function is also an option.

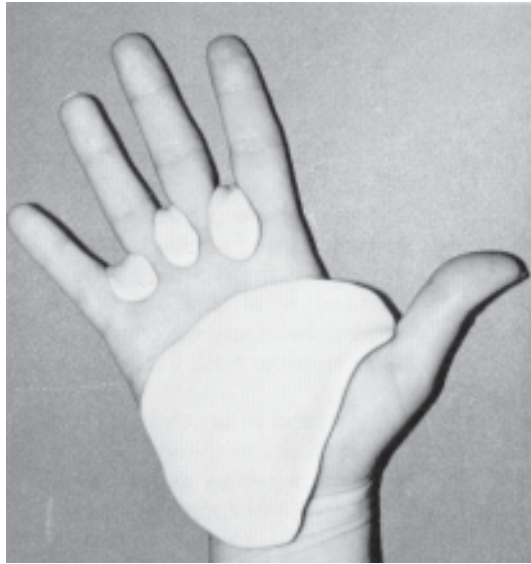


Fig 5. Elastomer inserts placed under compression garments help reduce post burn contracture. (Reprinted with permission from Dado DV, Angelats J: Management of burns of the hands in children. *Hand Clin* 6:711, 1990.)

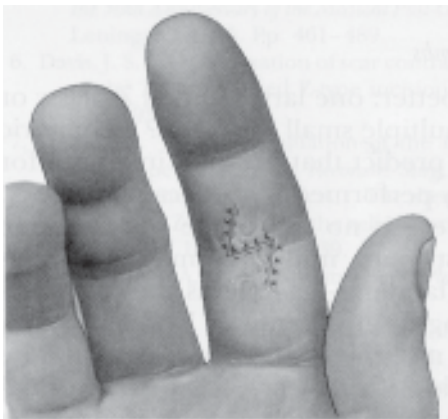
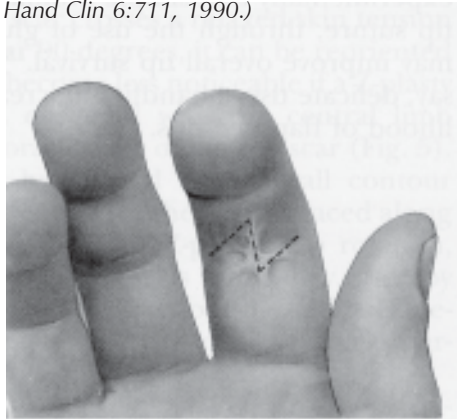


Fig6. Use of the Z-plasty maneuver to lengthen a scar contracture of the volar surface of the right index finger proximal interphalangeal joint. (Reprinted with permission from Rohrich RJ, Zbar RIS: A simplified algorithm for the use of Z-plasty. *Plast Reconstr Surg* 103:1513, 1999.)

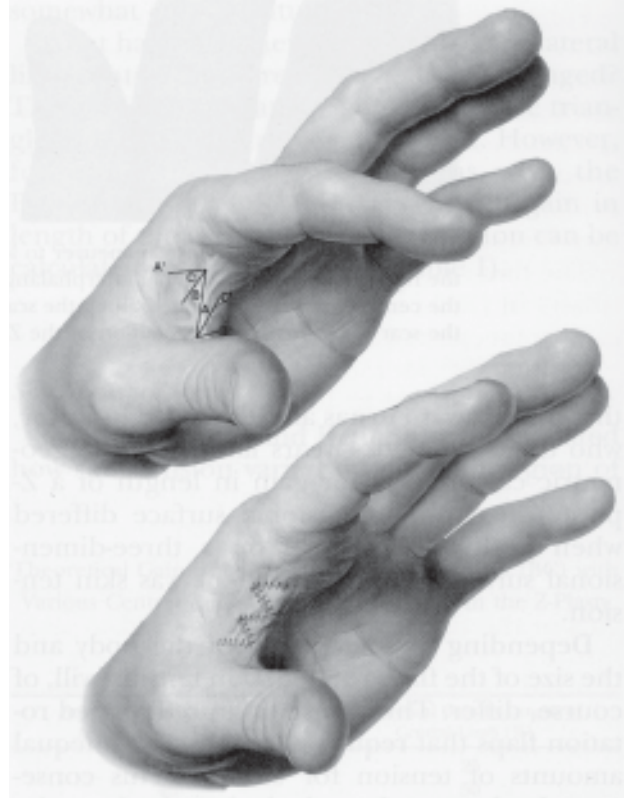

Fig 7. (Above) The four-flap Z-plasty is used to change the contour of a web of the left adductor space. (Below) Execution of this maneuver effaces the web. (Reprinted with permission from Rohrich RJ, Zbar RIS: A simplified algorithm for the use of Z-plasty. *Plast Reconstr Surg* 103:1513, 1999.)

POSTBURN RECONSTRUCTION IN THE DEVELOPING WORLD

The great majority of burn injuries occur in developing countries, where many people still use open fires for cooking and heat. Children especially are commonly injured as they stumble into fires. Most of these injuries are preventable. Due to the scarcity of medical facilities and insufficient personnel, adequate acute burn care is simply not available in many cases. At other times, local beliefs concerning burn care add to the delay in treatment.¹⁹⁸ The people affected are mostly of poor socioeconomic status, and the cost of managing these injuries is high. The upshot of these circum-

stances is that many patients end with severe morbidity or even death.¹⁹⁹

Scar hypertrophy and synechiae are the rule rather than the exception in the developing world. Typically burn wounds heal by secondary intention, and survivors develop massive contractures as their wounds are allowed to granulate. Severe finger-in-palm-on-forearm deformities, mento-sternal synechia, and even sternum-to-thigh

deformities that prevent walking are commonly seen. Physical therapy and splinting are keys to successful postburn reconstruction, and should be made available to all burn patients by the international community. Some measures that have worked in reducing burn injuries in some advanced countries and that may be appropriate to the developing world are suggested by Olaitan and coworkers.¹⁹⁹

BIBLIOGRAPHY

1. Nonfatal residential fire-related injuries treated in emergency departments — United States, 2001. *MMWR* 52(38):906, Sep 26, 2003.
2. Meyer WJ 3rd, Blakeney P, Russell W, et al: Psychological problems reported by young adults who were burned as children. *J Burn Care Rehabil* 25:98, 2004.
3. Brigham PA, McLoughlin E: Burn incidence and medical care use in the United States: estimates, trends, and data sources. *J Burn Care Rehabil* 13:573, 1992.
4. Cryer HG et al: Effects of early tangential excision and grafting on survival after burn injury. *Surg Gynecol Obstet* 173:449, 1991.
5. Deitch E: A policy of early excision and grafting in elderly burn patients shortens the hospital stay and improves survival. *Burns* 12:109, 1985.
6. Luteran A, Dacso CC, Curreri PW: Infections in burn patients. *Am J Med* 81:45, 1986.
7. Saffle JR, Davis B, Williams P, The American Burn Association Registry Participant Group: Recent outcomes in the treatment of burn injury in the United States: a report from the American Burn Association Patient Registry. *J Burn Care Rehabil* 16:219, 1995.
8. McGwin G Jr, Cross JM, Ford JW, et al: Long-term trends in mortality according to age among adult burn patients. *J Burn Care Rehabil* 24:21, 2003.
9. Garner WL, Reiss M: Burn care in Los Angeles, California: LAC+USC experience 1994-2004. *Burns* 31(Suppl 1):S32, 2005.
10. Danks RR: Burn management. A comprehensive review of the epidemiology and treatment of burn victims. *JEMS* 28:118, 2003.
11. Arturson MG: The pathophysiology of severe thermal injury. *J Burn Care Rehabil* 6:129, 1985.
12. Heimbach D, Engrav L, Grube B, Marvin J: Burn depth: a review. *World J Surg* 16:10, 1992.
13. Warden GD, Kravitz M, Schnebly A: The outpatient management of moderate and major thermal injuries. *J Burn Care Rehabil* 2:159, 1981.
14. Gerding RL et al: Outpatient management of partial-thickness burns: Biobrane® versus 1% silver sulfadiazine. *Ann Emerg Med* 19:121, 1990.
15. Hunt JL, Purdue GF: The elderly burn patient. *Am J Surg* 164:472, 1992.
16. Herndon DN et al: A comparison of conservative versus early excision. *Ann Surg* 209:547, 1989.
17. Demling RH, DeSanti L, Orgill DP: Initial management of the burn patient. Part 2. Section 9. *BurnSurgery.org/Modules/initial/part_two/sec9.htm*. Accessed 6/13/05.
18. Warden GD: Burn shock resuscitation. *World J Surg* 16:16, 1992.
19. Cancio LC, Chavez S, Alvarado-Ortega M, et al: Predicting increased fluid requirements during the resuscitation of thermally injured patients. *J Trauma* 56:404, 2004.
20. Morehouse JD, Finkelstein JL, Marano MA, et al: Resuscitation of the thermally injured patient. *Crit Care Clin* 8(2):355, 1992.
21. Zimmerman BJ, Granger DN: Reperfusion injury. *Surg Clin North Am* 72:65, 1992.
22. Mileski W, Borgstrom D, Lightfoot E, et al: Inhibition of leukocyte-endothelial adherence following thermal injury. *J Surg Res* 52:334, 1992.
23. Dziewulski P: Burn wound healing: James Ellsworth Laing memorial essay for 1991. *Burns* 18:466, 1992.
24. Cioffi WG, Burleson DG, Pruitt BA Jr: Leukocyte responses to injury. *Arch Surg* 128:1260, 1993.
25. Youn YK, LaLonde C, Demling R: The role of mediators in the response to thermal injury. *World J Surg* 16:30, 1992.
26. Thomson PD et al: Superoxide dismutase prevents lipid peroxidation in burned patients. *Burns* 16:406, 1990.
27. Ono I et al: Effects of platelet activating factor antagonist on oedema formation following burns. *Burns* 19:202, 1993.
28. Mileski W et al: Inhibition of leukocyte (WBC) adherence in a rabbit model of major thermal injury. *Presented at the Annual Meeting of the American Burn Association, Cincinnati, Ohio, 1993*.
29. Tanaka H et al: How long do we need to give antioxidant therapy during resuscitation when its administration is delayed for two hours? *J Burn Care Rehabil* 13:567, 1992.
30. Navar PD, Saffle JR, Warden GD: Effect of inhalation injury on fluid resuscitation requirements after thermal injury. *Am J Surg* 150:716, 1985.
31. Thompson PB et al: Effect on mortality of inhalation injury. *J Trauma* 26:163, 1986.

32. Sobel JB, Goldfarb IW, Slater H, Hammell EJ: Inhalation injury: a decade without progress. *J Burn Care Rehabil* 13:573, 1992.
33. Hunt JL, Agee RN, Pruitt BA Jr: Fiberoptic bronchoscopy in acute inhalation injury. *J Trauma* 15:641, 1975.
34. Herndon DN et al: Respiratory injury. Part I: Incidence, mortality, pathogenesis, and treatment of pulmonary injury. *J Burn Care Rehabil* 7:184, 1986.
35. Herndon DN et al: Inhalation injury in burned patients: Effects and treatment. *Burns* 14:349, 1988.
36. Herndon DN, Thompson PB, Trayber DL: Pulmonary injury in burn patients. *Crit Care Clin* 1:79, 1988.
37. Lund T et al: Upper airway sequelae in burn patients requiring endotracheal intubation or tracheostomy. *Ann Surg* 201:374, 1985.
38. Hunt JL, Purdue GF, Gunning T: Is tracheostomy warranted in the burn patient? Indications and complications. *J Burn Care Rehabil* 7:492, 1986.
39. Barrow RE, Spies M, Barrow LN, Herndon DN: Influence of demographics and inhalation injury on burn mortality in children. *Burns* 30:72, 2004.
40. Moylan JA Jr, Inge WW Jr, Pruitt BA Jr: Circulatory changes following circumferential extremity burns evaluated by the ultrasonic flowmeter: An analysis of 60 thermally injured limbs. *J Trauma* 11:763, 1971.
41. Janzekovic Z: A new concept in the early excision and immediate grafting of burns. *J Trauma* 19:1103, 1970.
42. Sheridan RL, Tompkins RG, Burke JF: Management of burn wounds with prompt excision and immediate closure. *J Intensive Care Med* 9:6, 1994.
43. Cryer HG et al: Effects of early tangential excision and grafting on survival after burn injury. *Surg Gynecol Obstet* 173:449, 1991.
44. Peck MD, Heimbach DM: Does early excision of burn wounds change the mortality? *J Burn Care Rehabil* 10:7, 1989.
45. Foy HM, Pavlin E, Heimbach DM: Excision and grafting of large burns: Operation length not related to increased morbidity. *J Trauma* 26:51, 1986.
46. Thompson P et al: Effective early excision on patients with major thermal injury. *J Trauma* 27:205, 1987.
47. Monafo WW, Bessey PQ: Benefits and limitations of burn wound excision. *World J Surg* 16:37, 1992.
48. Herndon DN, Parks DH: Comparison of serial debridement and autografting and early massive excision with cadaver skin overlay in the treatment of large burns in children. *J Trauma* 26:149, 1986.
49. Rosenberg JL, Zawacki BE: Reduction of blood loss using tourniquets and "compression" dressings in excising limb burns. *J Trauma* 26:47, 1986.
50. Frist W, Ackroyd F, Burke J, Bondoc C: Long-term functional results of selective treatment of hand burns. *Am J Surg* 149:516, 1985.
51. Demling RH: Effect of early burn excision and grafting on pulmonary function. *J Trauma* 24:830, 1984.
52. Jonsson CE, Dalsgaard CJ: Early excision and skin grafting of selected burns of the face and neck. *Plast Reconstr Surg* 88:83, 1991.
53. Fraulin FO, Illmayer SJ, Tredget EE: Assessment of cosmetic and functional results of conservative versus surgical management of facial burns. *J Burn Care Rehabil* 17:19, 1996.
54. Bombaro KM, Engrav LH, Carrougner GJ, et al: What is the prevalence of hypertrophic scarring following burns? *Burns* 29:299, 2003.
55. Gallico GG III: Biologic skin substitutes. *Clin Plast Surg* 17(3):519, 1990.
56. Atnip RG, Burke JF: Skin coverage. *Curr Probl Surg* 20, No 10, Oct 1983.
57. Pruitt BA Jr, Levine NS: Characteristics and uses of biologic dressings and skin substitutes. *Arch Surg* 119:312, 1984.
58. Thornton JF, Gosman AA: Skin grafts and skin substitutes and principles of flaps. *Selected Read Plast Surg* 10(1), 2004.
59. Zawacki BE: Temporary wound closure after burn excision. *J Burn Care Rehabil* 7:138, 1986.
60. Heimbach DM, Warden GD, Luterma A, et al: Multicenter postapproval clinical trial of Integra dermal regeneration template for burn treatment. *J Burn Care Rehabil* 24:42, 2003.
61. Pruitt BA Jr: The burn patient: II. Later care and complications of thermal injury. *Curr Problem Surg* 16, No 5, May 1979.
62. Mason AD Jr, McManus AT, Pruitt BA Jr: Association of burn mortality and bacteremia. A 25-year review. *Arch Surg* 121:1027, 1986.
63. McManus AT, Mason AD Jr, McManus WF, Pruitt BA Jr: A decade of reduced gram-negative infections and mortality associated with improved isolation of burned patients. *Arch Surg* 129:1306, 1994.
64. Marvin JA et al: Usefulness of blood cultures in confirming septic complications in burn patients: Evaluation of a new culture method. *J Trauma* 15:657, 1975.
65. Jones WG et al: Enterococcal burn sepsis. A highly lethal complication in severely burned patients. *Arch Surg* 121:649, 1986.
66. Pensler JR et al: Fungal sepsis: An increasing problem in major thermal injuries. *J Burn Care Rehabil* 7:488, 1986.
67. Pruitt BA Jr, McManus AT: The changing epidemiology of infection in burn patients. *World J Surg* 16:57, 1992.
68. Merrell SW et al: The declining incidence of fatal sepsis following thermal injury. *J Trauma* 29:1362, 1989.
69. Pruitt BA Jr: The diagnosis and treatment of infection in the burn patient. *Burns* 11:79, 1984.
70. Robson MC: Burn sepsis. *Crit Care Clin* 4:281, 1988.
71. Luterma A, Dacso CC, Curreri PW: Infections in burn patients. *Am J Med* 81:45, 1986.
72. Wilson SJ, Knipe CJ, Zieger MJ, et al: Direct costs of multidrug-resistant *Acinetobacter baumannii* in the burn unit of a public teaching hospital. *Am J Infect Control* 32:342, 2004.
73. Purdue GF, Hunt JL, Prescott PR: Child abuse by burning—an index of suspicion. *J Trauma* 28:221, 1988.
74. Daria S, Sugar NF, Feldman KW, et al: Into hot water head first: distribution of intentional and unintentional immersion burns. *Pediatr Emerg Care* 20:302, 2004.
75. Allen SR, Kagan RJ: Grease fryers: a significant danger to children. *J Burn Care Rehabil* 25:456, 2004.
76. Foglia RP, Moushey R, Meadows L, et al: Evolving treatment in a decade of pediatric burn care. *J Pediatr Surg* 39:957, 2004.
77. Heideman M, Begtsson A: The immunologic response to thermal injury. *World J Surg* 16:53, 1992.
78. Cioffi WG, Burleson DG, Pruitt BA Jr: Leukocyte responses to injury. *Arch Surg* 128:1260, 1993.

79. Wilmore DW et al: Stress in surgical patients as a neuro-physiologic reflex response. *Surg Gynecol Obstet* 142:257, 1976.
80. Ireton CS et al: Do changes in burn size affect measured energy expenditures? *J Burn Care Rehabil* 6:419, 1985.
81. Rutan TC et al: Metabolic rate alterations in early excision and grafting versus conservative treatment. *J Trauma* 26:140, 1986.
82. Waymack JP, Herndon DN: Nutritional support of the burned patient. *World J Surg* 16:80, 1992.
83. Ireton-Jones CS et al: Equations for the estimation of energy expenditures in patients with burns with special reference to ventilatory status. *J Burn Care Rehabil* 13:330, 1992.
84. Ireton CS et al: Evaluation of energy expenditures in burn patients. *J Am Diet Assoc* 86:331, 1986.
85. Saffle JR et al: Use of indirect calorimetry in the nutritional management of burned patients. *J Trauma* 25:32, 1985.
86. O'Neil CE, Hutsler D, Hildreth MA: Basic nutritional guidelines for pediatric burn patients. *J Burn Care Rehabil* 10:278, 1989.
87. Bell SJ, Molnar JA, Krasker WS, et al: Weight maintenance in pediatric burned patients. *J Am Diet Assoc* 2:207, 1986.
88. Wolfe RR: Caloric requirements of the burned patient. *J Trauma* 21:712, 1981.
89. Alexander JW et al: Beneficial effects of aggressive protein feeding in severely burned children. *Ann Surg* 192:505, 1980.
90. Matsuda T et al: The importance of burn wound size in determining the optimal calorie:nitrogen ratio. *Surgery* 94:562, 1983.
91. Heimbach DM et al: Toxic epidermal necrolysis: A step forward in treatment. *JAMA* 257:2171, 1987.
92. Souder LL: Biobrane dressing used in the treatment of toxic epidermal necrolysis: A case report. *J Burn Care Rehabil* 11:237, 1990.
93. Halebain P et al: Improved burn center survival of patients with toxic epidermal necrolysis managed without corticosteroids. *Ann Surg* 204:503, 1986.
94. Redman DP, Friedman B, Law E, Still JM: Experience with necrotizing fasciitis at a burn care center. *South Med J* 96:868, 2003.
95. Hunt JL et al: The pathophysiology of acute electric injuries. *J Trauma* 16:335, 1976.
96. Arnoldo BD, Purdue GF, Kowalske K, et al: Electrical injuries: a 20-year review. *J Burn Care Rehabil* 25:479, 2004.
97. Hunt JL, Sato RM, Baxter CR: Acute electric burns. Current diagnostic and therapeutic approaches to management. *Arch Surg* 115:434, 1980.
98. Hunt JL et al: The use of technetium-99m stannous pyrophosphate scintigraphy to identify muscle damage in acute electric burns. *J Trauma* 19:409, 1979.
99. Purdue GF, Hunt JL: Electrocardiographic monitoring after electrical injury: Necessity or luxury. *J Trauma* 26:166, 1986.
100. Hanumadass ML et al: Acute electrical burns: A 10-year clinical experience. *Burns* 12:427, 1986.
101. Mann R, Gibran N, Engrav L, Heimbach D: Is immediate decompression of high voltage electrical injuries to the upper extremity always necessary? *J Trauma* 40:584, 1996.
102. Sykes RA, Mani MM, Hiebert JM: Chemical burns: retrospective review. *J Burn Care Rehabil* 7:343, 1986.
103. Barillo DJ, Cancio LC, Goodwin CW: Treatment of white phosphorus and other chemical burn injuries at one burn center over a 51-year period. *Burns* 30:448, 2004.
104. Saydjari R et al: Chemical burns. *J Burn Care Rehabil* 7:404, 1986.
105. Broughton G II, Rohrich RJ: Wounds and scars. *Selected Read Plast Surg* 10(7 Part 1), 2005.
106. Feldman JJ: Reconstruction of the Burned Face in Children. In: Serafin D, Georgiade NG (eds), **Pediatric Plastic Surgery**. St Louis, Mosby, 1984, Vol 1, Ch 32.
107. Rohrich RJ, Zbar RIS: A simplified algorithm for the use of Z-plasty. *Plast Reconstr Surg* 103:1513, 1999.
108. Gonzalez-Ulloa M: Restoration of the face covering by means of selected skin in regional aesthetic units. *Br J Plast Surg* 9:212, 1956.
109. Youm T, Margiotta M, Kasabian A, Karp N: Complications of tissue expansion in a public hospital. *Ann Plast Surg* 42:396, 1999.
110. Friedman RM, Ingram AE, Rohrich RJ, et al: Risk factors for complications in pediatric tissue expansion. *Plast Reconstr Surg* 98:1242, 1996.
111. Spence RJ: Experience with novel uses of tissue expanders in burn reconstruction of the face and neck. *Ann Plast Surg* 28:453, 1992.
112. Grotting J, Walkinshaw M: The early use of free flaps in burns. *Ann Plast Surg* 15:127, 1985.
113. Platt AJ, McKiernan MV, McLean NR: Free tissue transfer in the management of burns. *Burns* 22:474, 1996.
114. Abramson DL, Pribaz JJ, Orgill DP: The use of free tissue transfer in burn reconstruction. *J Burn Care Rehabil* 17:402, 1996.
115. Barrera A: The use of micrografts and minigrafts for the treatment of burn alopecia. *Plast Reconstr Surg* 103:581, 1999.
116. Moreno-Arias GA, Campos-Fresneda A: Hair grafting in postburn alopecia. *Dermatol Surg* 25:412, 1996.
117. Juri J: Use of parieto-occipital flaps in the surgical treatment of baldness. *Plast Reconstr Surg* 55:456, 1975.
118. Orticochea M: New 3-flap scalp reconstruction. *Br J Plast Surg* 24:184, 1971.
119. Nordstrom RE, Devin JW: Scalp stretching with a tissue expander for closure of scalp defects. *Plast Reconstr Surg* 75:578, 1985.
120. Cohen M et al: The role of tissue expansion in the reconstruction of secondary burn defects. *J Burn Care Rehabil* 10:220, 1989.
121. Neligan PC, Peters WJ: Advances in burn scar reconstruction: The use of tissue expansion. *Ann Plast Surg* 22:203, 1989.
122. Norkus T, Klebanovas J, Viksraitis S, et al: Deep electrical burns of the calvarium: early or delayed reconstruction? *Burns* 24:569, 1998.
123. Chui DTW, Sherman JE, Edgerton BW: Coverage of the calvarium with a free parascapular flap. *Ann Plast Surg* 12:60, 1984.
124. Chicarilli ZN, Ariyan S, Cuono CB: Single stage repair of complex scalp and cranial defects with the free radial forearm flap. *Plast Reconstr Surg* 77:577, 1986.
125. Losken A, Carlson GW, Culbertson JH, et al: Omental free flap reconstruction in complex head and neck deformities. *Head Neck* 24:326, 2002.

126. Lee B, Bickel K, Levin S: Microsurgical reconstruction of extensive scalp defects. *J Reconstr Microsurg* 15:255, 1999.
127. Millard DR: The crane principle for the transport of subcutaneous tissue. *Plast Reconstr Surg* 43:451, 1969.
128. Brent B: The acquired auricular deformity. A systematic approach to its analysis and reconstruction. *Plast Reconstr Surg* 59:475, 1977.
129. Wines N, Ryman W, Matulich J, Wines M: Retrospective review of reconstructive methods of conchal bowl defects following Mohs micrographic surgery. *Dermatol Surg* 27:471, 2001.
130. Antia NH, Buch VI: Chondrocutaneous advancement flap for the marginal defect of the ear. *Plast Reconstr Surg* 39:472, 1967.
131. Hackney FL: Plastic surgery of the ear. *Selected Read Plast Surg* 9(16), 2001.
132. Purdue GF, Hunt HL: Chondritis of the burned ear: a preventable complication. *Am J Surg* 152:257, 1986.
133. Adams WP Jr, Beran SJ: Lip, cheek, and scalp reconstruction; hair replacement. *Selected Read Plast Surg* 9(15), 2001.
134. Kenkel JM: Eyelid reconstruction. *Selected Read Plast Surg* 9(14), 2000.
135. Tripier L: Musculocutaneous flap in the form of a bridge, applied to the reconstruction of the eyelids. *Compt Rend Acad Sc (Paris)* 109:620, 1889.
136. Cole JG: Reconstruction of large defects of the upper eyelid. *Am J Ophthalmol* 64:376, 1967.
137. Rohrich RJ, Zbar RIS: The evolution of the Hughes tarsoconjunctival flap for lower eyelid reconstruction. *Plast Reconstr Surg* 104:518, 1999.
138. Mustarde JC: Reconstruction of eyelids. *Ann Plast Surg* 11:149, 1983.
139. Washio H: Retroauricular-temporal flap. *Plast Reconstr Surg* 43:162, 1969.
140. Stamatopoulos C, Panayotou P, Tsigirigou S, Ioannovich JD: Use of free flaps in the aesthetic reconstruction of face and neck deformities. *Microsurgery* 13:188, 1992.
141. Ellenbogen R: Transcoronal eyebrow lift with concomitant upper blepharoplasty. *Plast Reconstr Surg* 71:490, 1983.
142. Pensler JM, Dillon B, Parry SW: Reconstruction of the eyebrow in the pediatric patient. *Plast Reconstr Surg* 76:434, 1985.
143. Coessens B, Van Geertruyden J, De Mey A: Surgical tattooing as an aesthetic improvement in facial reconstruction with a free radial forearm flap. *J Reconstr Microsurg* 9:331, 1995.
144. Burget GC: Aesthetic reconstruction of the tip of the nose. *Dermatol Surg* 21:419, 1995.
145. Burget GC: Aesthetic restoration of the nose. *Clin Plast Surg* 12(3):463, 1985.
146. Muzaffar AR, English JM: Nasal reconstruction. *Selected Read Plast Surg* 9(13), 2000.
147. Swartz WM: Microvascular approaches to nasal reconstruction. *Microsurgery* 9:150, 1988.
148. Acikel C, Bayram I, Eren F, Celikoz B: Free temporoparietal fascial flaps and full-thickness skin grafts in aesthetic restoration of the nose. *Aesthetic Plast Surg* 26:416, 2002.
149. Hirase Y, Kojima T, Takeishi M, et al: Nasal reconstruction using free temporoparietal fascial flap transfer (Upton's method). *Ann Plast Surg* 33:629, 1994.
150. Baumeister S, Koller M, Dragu A, et al: Principles of microvascular reconstruction in burn and electrical burn injuries. *Burns* 31:92, 2005.
151. Disa JJ, Liew S, Cordeiro PG: Soft-tissue reconstruction of the face using the folded/multiple skin island radial forearm free flap. *Ann Plast Surg* 47:612, 2001.
152. Bayramicli M: The distal dorsalis pedis flap for nasal tip reconstruction. *Br J Plast Surg* 49:325, 1996.
153. Yousif NJ, Warren R, Matloub HS, Sanger JR: The lateral arm fascial free flap: its anatomy and use in reconstruction. *Plast Reconstr Surg* 86:1138, 1990.
154. Ozek C, Gundogan H, Bilkay U, et al: Nasal columella reconstruction with a composite free flap from the root of auricular helix. *Microsurgery* 22:53, 2002.
155. Shenaq SM, Dinh TA, Spira M: Nasal alar reconstruction with an ear helix free flap. *J Reconstr Microsurg* 5:63, 1989.
156. Vallis CP: Hair transplantation to the upper lip to create a moustache. *Plast Reconstr Surg* 54:606, 1974.
157. Marks MW, Friedman RJ, Thornton JW, Argenta LC: The temporal island scalp flap for management of facial burn scars. *Plast Reconstr Surg* 82:257, 1988.
158. Lyons GB et al: Upper lip reconstruction: Use of the free superficial temporal artery hair-bearing flap. *Br J Plast Surg* 42:333, 1989.
159. Silverglade D, Zacher JB, Ruberg RL: Improved splinting of oral commissure burns: results in 21 consecutive patients. *Ann Plast Surg* 9:316, 1982.
160. Canady JW, Thompson SA, Bardach J: Oral commissure burns in children. *Plast Reconstr Surg* 97:738, 1996.
161. Gillies HD, Millard DR Jr: **Principles and Art of Plastic Surgery**. Boston, Little Brown, 1957.
162. Pensler JM, Rosenthal A: Reconstruction of the oral commissure after an electrical burn. *J Burn Care Rehabil* 11:50, 1990.
163. Ortiz-Monasterio F, Factor R: Early definitive treatment of electrical burns of the mouth. *Plast Reconstr Surg* 65:169, 1980.
164. Donelan MB: Reconstruction of electrical burns of the oral commissure with a ventral tongue flap. *Plast Reconstr Surg* 95:1155, 1995.
165. Herndon DN et al: Treatment of burns in children. *Pediatr Clin North Am* 32:1311, 1985.
166. Almaguer E, Dillon BT, Parry SW: Facial resurfacing at Shriners Burns Institute: A 16-year experience in young burned patients. *J Trauma* 25:1081, 1985.
167. Ninkovic M, Moser-Rumer A, Ninkovic M, et al: Anterior neck reconstruction with pre-expanded free groin and scapular flaps. *Plast Reconstr Surg* 113:61, 2004.
168. Economides NG, Ferrell TH: Neck resurfacing with free TRAM flap. *Microsurgery* 13:240, 1992.
169. Angrigiani C: Aesthetic microsurgical reconstruction of anterior neck burn deformities. *Plast Reconstr Surg* 93:507, 1994.
170. Neale HW et al: Breast reconstruction in the burned adolescent female (an 11-year, 157-patient experience). *Plast Reconstr Surg* 70:718, 1982.
171. Ozgur F, Gokalan I, Mavili E, et al: Reconstruction of postburn breast deformities. *Burns* 18:504, 1992.
172. Marks MW, Argenta LC, Thornton JW: Burn management: The role of tissue expansion. *Clin Plast Surg* 14:543, 1987.

173. Cohen M, Marschall MA, Schafer ME: Tissue expansion for the reconstruction of burn defects. *J Trauma* 28:158, 1988.
174. Garner WL, Smith DJ Jr: Reconstruction of burns of the trunk and breast. *Clin Plast Surg* 19:683, 1992.
175. Slator RC, Wilson GR, Sharpe DT: Postburn breast reconstruction: Tissue expansion prior to contracture release. *Plast Reconstr Surg* 90:668, 1992.
176. Neale HW, Kurtzman LC: Discussion of "Postburn breast reconstruction: tissue expansion prior to contracture release," by RC Slator, GR Wilson, DT Sharpe. *Plast Reconstr Surg* 90:672, 1992.
177. Kurtzman LC, Stern PJ: Upper extremity burn contractures. *Hand Clin* 6(2):261, 1990.
178. Roberts AHN, Dickson WA: Fasciocutaneous flaps for burn reconstruction: A report of 57 flaps. *Br J Plast Surg* 41:150, 1988.
179. Achauer BM, Spenler CW, Gold ME: Reconstruction of axillary burn contractures with the latissimus dorsi fasciocutaneous flap. *J Trauma* 28:211, 1988.
180. Tolhurst DE, Haeseker B: Fasciocutaneous flaps in the axillary region. *Br J Plast Surg* 35:430, 1982.
181. Salinas Velasco VM, Garcia-Morato V, Fregenal Garcia FJ: Burn of the elbow: the role of the radial forearm island flap. *Burns* 18:71, 1992.
182. Lovie MJ, Duncan GM, Glasson DW: The ulnar artery forearm free flap. *Br J Plast Surg* 37:486, 1984.
183. Hallock GG: Local random fasciocutaneous flaps for repair of the burned elbow. *J Burn Care Rehabil* 12:26, 1991.
184. Hunt JL, Sato R, Baxter CR: Early tangential excision and immediate mesh autografting of deep dermal hand burns. *Ann Surg* 189:147, 1979.
185. Quan PE, Bieringer R, Alston DW, Curreri PW: Control of scar tissue in the finger web spaces by use of graded pressure inserts. *J Burn Care Rehabil* 2:27, 1981.
186. Falcone PA, Edstrom LE: Decision making in the acute thermal hand burn: An algorithm for treatment. *Hand Clin* 6(2):233, 1990.
187. Chick LR, Lister GD, Sowder L: Early free-flap coverage of electrical and thermal burns. *Plast Reconstr Surg* 89:1013, 1992.
188. Schiller WR, Garren RL, Bay RC, et al: Laser Doppler evaluation of burned hands predicts need for surgical grafting. *J Trauma* 43:35, 1997.
189. Alexander JW, MacMillan BC, Martel L: Correction of postburn syndactyly: an analysis of children with introduction of the VM-plasty and postoperative pressure inserts. *Plast Reconstr Surg* 70:345, 1982.
190. Dado DV, Angelats J: Management of burns of the hands in children. *Hand Clin* 6:711, 1990.
191. Graham TJ, Stern PJ, True MS: Classification and treatment of postburn metacarpophalangeal joint extension contractures in children. *J Hand Surg* 15A:450, 1990.
192. Alexander JW et al: Surgical correction of postburn flexion contractures of the fingers in children. *Plast Reconstr Surg* 68:218, 1981.
193. Mani MM, Chhatre M: Reconstruction of the burned lower extremity. *Clin Plast Surg* 19:693, 1992.
194. Michielsen D, Van Hee R, Neetens C, et al: Burns to the genitalia and the perineum. *J Urol* 159:418, 1998.
195. Gillies H, Harrison RJ: Congenital absence of the penis. *Br J Plast Surg* 1:8, 1948.
196. Gottlieb LJ, Saunders JN: Perineal Burns. In: Achauer B (ed), **Burn Reconstruction**. New York, Thieme, 1991, p 165–183.
197. Hester JR, Hill HL, Jurkiewicz MJ: One stage reconstruction of the penis. *Br J Plast Surg* 31:279, 1978.
198. Manktelow A: Burn injury and management in Liberia. *Burns* 16:432, 1990.
199. Olaitan PB, Olaitan JO: Burns and scalds — epidemiology and prevention in a developing country. *Niger J Med* 14:9, Jan-Mar 2005.

Selected Readings in Plastic Surgery

PUBLISHER Selected Readings in Plastic Surgery
411 North Washington, Suite 6900
Dallas, Texas 75246-1777
(214) 824-0154 FAX (214) 824-0463
srps@swbell.net

EDITORIAL STAFF Jeffrey M Kenkel MD, *Editor*
Fritz E Barton Jr MD, *Editor Emeritus*
Grace Darling MS, ELS(D), *Managing Editor*
John L Darling, *Associate Editor*
Sheri Quisenberry, *Business Manager*

EDITORIAL BOARD	RG Anderson MD	FL Hackney MD, DDS	JC O'Brien MD
	G Broughton MD	L Hollier MD	RJ Rohrich MD
	HS Byrd MD	J Janis MD	MC Snyder MD
	D Gonyon MD	JM Kenkel MD	J Thornton MD
	A Gosman MD	JE Leedy MD	RIS Zbar MD
	KA Gutowski MD	A Lipschitz MD	
	JR Griffin MD	JA Masson FRACS	
	RY Ha MD	AR Muzaffar MD	

INFORMATION FOR SUBSCRIBERS A SELECTED READINGS IN PLASTIC SURGERY (ISSN 0739-5523) volume consists of 30 numbers, issued approximately 15 times per year. A subscription entitles you to receive 15 numbers, so to obtain an entire volume, you must subscribe for 2 consecutive years.

ANNUAL SUBSCRIPTION RATES: A 15-issue subscription is \$300 US. CDs of volume 9, numbers 1-20 and 21-40, are also available for \$300 each. CME quizzes are \$60 for 15 issues. Modules (please inquire) are \$200 each. International subscribers, add \$50 to the above. Single issues are \$40 US, \$50 non-US. Binders with tabs are available for domestic shipping only at \$20 each. We accept payment by check (US funds), purchase order, or VISA/MasterCard charge. Please allow 8 to 10 weeks for receipt of your first issue.

SHIPPING We mail 8 times a year, two issues per mailing. Claims for lost copies will be honored for 3 months after publication for domestic subscribers and 6 months for subscribers outside the U.S. Please note that all sales are final – no returns will be accepted.

BACK ISSUES To obtain back issues you may write to us at 411 North Washington, Suite 6900, Dallas TX 75246; e-mail srps@swbell.net; or fax 214-824-0463. Please inquire about availability and price before placing your order. Prepayment or credit card information must accompany all requests.


COPYRIGHT © 2005 by SELECTED READINGS IN PLASTIC SURGERY. Published under the auspices of the University of Texas Southwestern Medical Center and Baylor University Medical Center, Dallas, Texas.



ISSN 0739-5523

Printed on recycled paper using soy-based ink; 100% recyclable.

SOUTHWESTERN
THE UNIVERSITY OF TEXAS
SOUTHWESTERN MEDICAL CENTER
AT DALLAS

 **BAYLOR UNIVERSITY
MEDICAL CENTER**
An Affiliate of the
Baylor Health Care System