Lydia Thompson, RN, MSN
N124 Maternal Child Nursing

Musculoskeletal Alteration in the Pediatric Patient

- Talipes (Clubfoot)
- Developmental Dysplasia of the Hip
- Scolisis
- Muscular Dystrophy
- Leg-Calve-Perthes Disease
- Slipped Capital Femoral Epiphysis

Reflections from a Family

I was 35 years old when Juan was born, I had put off marriage until my career as an attorney was well established. I had two miscarriages before I became pregnant with Juan. My husband and I were so excited when this pregnancy did not end in a miscarriage. We both wanted a child so much. When Juan was born, he had bilateral clubfoot. We were so disappointed because we had waited so long for this event. Then our thoughts turned to the baby. We wondered if he would ever walk and run or if his feet would ever look like a normal child.

Talipes Deformities
Clubfoot
(talus-ankle, pes-foot)

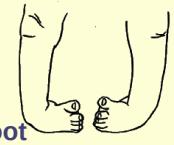

- Congenital deformity of the foot
- Involves bone, muscle, ligaments, nerves
- Unilateral or bilateral deviation (50%)
- Appears twisted out of its normal position

Pseudo-Talipes Deformity (positional)

- Developed from intrauterine position
- Can be manipulated into straight position

Talipes Deformities (*Clubfoot*)

Terms

- Deformities described according to the position of the ankle and foot.
  - **Varus**: foot points in
  - **Valgus**: foot points out
  - **Equinus**: plantarflexion
  - **Calcaneus**: dorsiflexion
- Most cases are a combination
  - **Talipes Equinovarus** *(TEV)*
  - **Talipes Calcaneovalgus**

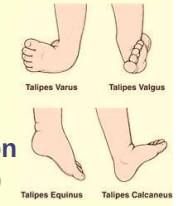

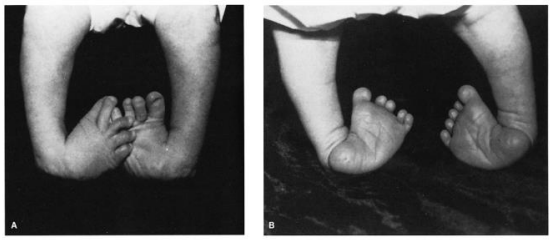

Figure 58-12 Severe clubfoot deformity. (**A**) The heel is in severe varus, and the forefoot is adducted and inverted. (**B**) The cavus deformity results from the slightly pronated position of the forefoot in relation to the hindfoot. (From Weinstein S.L., Buckwalter J.A. [1994]. *Turek's orthopaedics* [5th ed.]. Philadelphia: J.B. Lippincott.)

Copyright © 2005 Lippincott Williams & Wilkins. Instructor's Resource CD-ROM to Accompany *Porth's Pathophysiology: Concepts of Altered Health States*, Seventh Edition.

Talipes Deformities (*Clubfoot*)

- 1 in 700-1000 live births
- Boys > girls (2:1)
- Cause
  - Unknown, many theories
    - Heredity & race
  - At risk when seen with other congenital abnormalities such as:
    - myelomeningocele
    - cerebral palsy

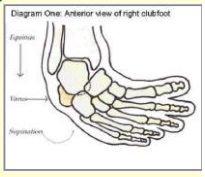

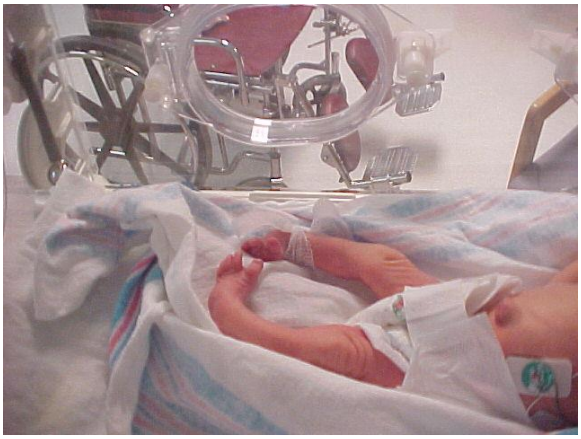

Talipes Deformities
(Clubfoot)

- **Diagnostic Evaluation**
  - **Visual Inspection**
    - Rigid limb that **cannot** be manipulated into a neutral position.
  - **Radiographs**
    - Not necessary for diagnosis
    - Measuring angles for pre and post surgical procedures

Talipes Deformities (*Clubfoot*)

Non-surgical Management

- **Serial Casting (Ponseti Casting Method)**
  - **The earlier the better!**
  - **Manipulate into correct anatomical position**
  - **Cast (plaster) change weekly for 2-3 mos**
  - **Then bar or brace for 3 mos-2 yrs**

Talipes Deformities (*Clubfoot*)

Non-surgical Management

- **French Physiotherapy Method**
  - **By experienced PTs only**
  - **Daily stretching/strengthening/taping/splinting**
  - **Splinting (orthotics) until 2-3 years of age**

Talipes Deformities

- **Follow-up Care (monitoring)**
  - **To prevent reoccurance**
  - **Until skeletal maturity**
  - **Surgical Intervention may be required**

Talipes Deformities (*Clubfoot*)
Surgical Treatment

- **Cutting of joint and tendon**
- **Restore bone to normal position**
- **Procedures differ**
  - *PMR*: posterior medial release
  - *PMS*: posterior medial stretching
  - *SLATTT:* Split lateral anterial tibial tendon transfer
- **Post –Op**
  - *Pinning* – hold position
  - *Casting* – protect pins
    –discourage weight bearing

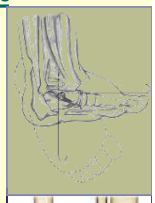

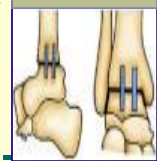

Surgical pinning

Talipes Deformities *(Clubfoot)*

- **Nursing Care**
  - **Assessment**
    - **S_____ N_____ P_____**
  - **Cast Care**
    - Drying Time
    - High Cast – cleanliness
    - Cast Marking
    - Elevate limb
    - Nerve and Circulation
  - **Pin Care**
  - **Emotional Support & Parent Teaching**
    - Pain
    - Mobility
    - Sleep Disturbances
    - Skin & N/C assessment

Eli at birth

Eli after serial casting (6mo)

Eli at 2 ½ years (after surgery)



Other success stories

Question?

Your patient with talipes equinovarus came back from surgery last night after a PMR procedure.

What signs and symptoms would you be concerned about?

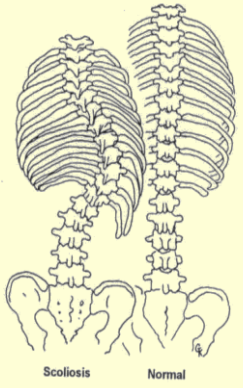

Scoliosis

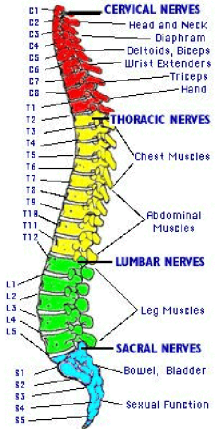

Spinal Deformities

Kyphosis	Lordosis	Scoliosis
Backward curve in the upper spine *Round back*	Inward curve in the lower back, excessive *Sway-back*	Lateral curvature, (side to side curve) *C-shaped* *S-shaped*

Scoliosis

- ***Definition ?***
  - **Lateral curvature >10 degrees**
- **Most common spinal deformity**
- **Incidence : 100 per 1,000 children**
  2 per 1,000 will require tx
- **Adolescent Idiopathic most common**
  - Occurs during rapid growth of adolescence (8-15 yrs)
- **Greater incidence in girls (5:1)**
- **30% have a family hx**

Types and Etiology of Scoliosis
Functional vs. Structural

- ***Functional* Scoliosis** (nonstructural)
  - Caused by a **secondary problem**
    - Pelvic tilt d/t unequal leg lengths
    - Inflammation/disease of the spine
    - Poor posture
    - Head tilt d/t poor vision
  - Small vertebrae changes on x-ray
- ***Treatment***
  - **Correct the cause**
  - Assure parents that it can be corrected

Structural Scoliosis (S-shaped)

Classifications

- Congenital
- Idiopathic
- Neuromuscular
- Syndromic

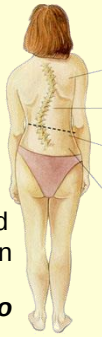

Pathophysiology

- Spinal rotation (C→ S curve)
- Muscles & ligaments are contracted & thickened on concave side
- Muscles (convex side) thin and atrophied
- Compensatory curve results to maintain erect posture.
- ***Curve is permanent and damaging to vertebrae***

Structural Scoliosis (S-shaped)

cont. Pathophysiology

- Rotational deformities may cause:
  - ***Pain***
  - ***Compromised thoracic growth***
  - ***Impair respiratory function***

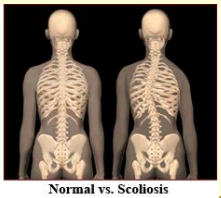

Normal vs. Scoliosis

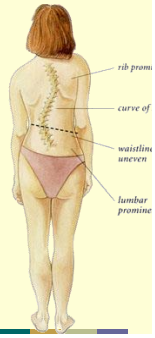

Assessment & Screening of Scoliosis

- **School Screening & Physical Examination**
  - Screening around 5th grade (10 yrs)
- **Early detection at home (8yrs)**
- **Palpation of spine and observe:**
  - **Shoulder height**
    - Uneven shoulders
    - Bra straps unequal lengths
  - **Scapular or flank shape**
    - Prominent shoulder blade(s)
  - **Hip height**
    - Uneven waist (skirt uneven)
    - Elevated hips
    - Leaning to one side

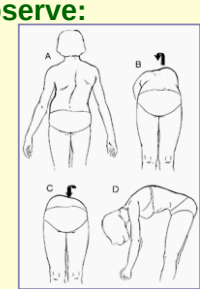

Assessment & Screening of Scoliosis

- **Assessment Tools**
  - **Scoliometer**
  - **Photographs**
  - **Standing xrays**

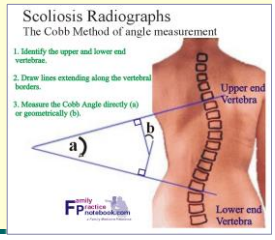

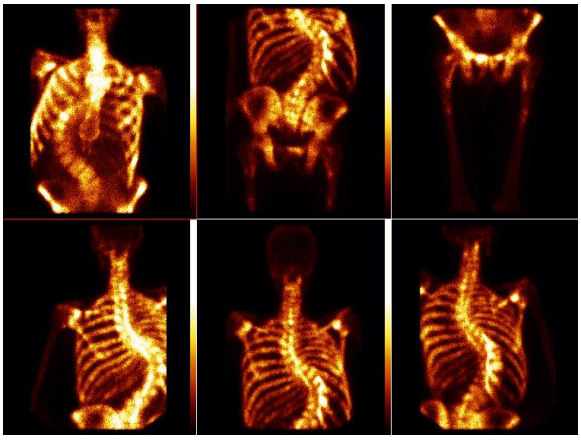

Treatment of Scoliosis

- **Functional Scoliosis**
  - **Correct the cause**
- **Structural Scoliosis**
  (dependent on severity)
  - **Do nothing (monitor)**
  - **Wear a brace**
  - **Surgery**

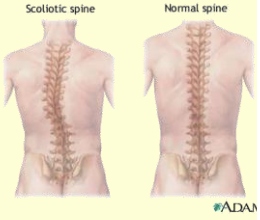

When is treatment for Structural Scoliosis necessary?

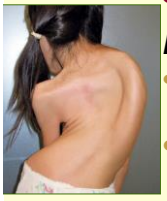

Dependent on:

- location and degree of curvature
- age & skeletal maturity

- **Curves<20-25°: Do nothing (monitor)**
- **Curves>30°: Bracing or traction**
- **Curves>40°: Spinal fusion-surgery**

Treatment for Scoliosis

- Exercise
- TLSO brace
- Boston brace
- Milwaukee brace

- Stops the progression only!

Treatment for Scoliosis

- **Bracing**
  - Custom made
  - Worn 18-23 hrs a day
  - Wear Tshirt under to prevent?
  - Xrays q 4-6 month
- **Discontinue near skeletal maturity**
  - Females: 18-24 mo post menarche
  - Males: later in teenage years

Surgical Intervention if:

- Bracing & exercise not effective
- Curves worsening
- Pre-teen with >30-40° curve
- Difficulty with balance or sitting
- Respiratory issues
- Pain or discomfort

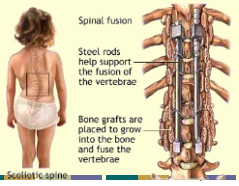

Surgical Procedure
Spinal Fusion

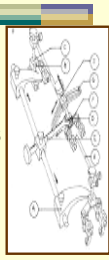

- Multiple techniques and approaches
- Hooks, nuts & rods to align spine
- Bone grafts used to provide fusion
- Harrington System
  - First internal spinal instrumentation device
- Others include L-rod and multi-hook
- *Risks?*
  - *Paralysis* • *Bleeding* • *Infection* • *Pain*

Spinal Fusion
Pre-op care

- **Radiographic series**
- **Labs:** PT, CBC, lytes, UA, *type & cross*
- **Pre-op teaching:**
  - What can they expect following surgery?
    - Pain
    - Log rolling
    - I/S (deep breathing)

Spinal Fusion
Post-op Care

- **Monitored in ICU**
- **Logroll (lock bed control)**
- **Assessments:**
  - ***VS (blood loss)***
  - **Neurovascular**
  - **Gastrointestinal**
    - NGT
  - **Renal**
    - Foley Catheter
  - **Pain** (PCA)
  - **Skin**

Potential complications:

- **Paralytic ileus**
  - NPO for few days/assess bowel sounds
  - NGT for decompression
- **Deep vein thrombosis**
  - Ted hose/compression boots/Homan sign's
- **Urinary Retention**
  - Assess for bladder distention
  - Urine output

Nursing Diagnosis for a patient with Scoliosis?

- **PRIMARY NURSING DIAGNOSIS**?
  - Psychosocial
  - Physiological
- **Remember**!!
  - Support groups available
  - Encourage family to get involved with care.

Muscular Dystrophy

- **Duchenne Muscular Dystrophy**
  - **X-linked recessive disorder**
  - **Onset: 3-7 yrs.** ▪ **Incidence: 1/3,000 Males**

- **Becker Muscular Dystrophy**
  - **X-linked recessive disorder**
  - Onset: **>5** yrs. ▪ Incidence: 1/20,000 males
- **Facioscapulohumeral MD**
  - **Autosomal dominant**
  - Onset: **later childhood/adolescence**
  - Incidence: 3-10/million
- **Emery-Dreifuss Muscular Dystrophy**
  - **X-linked recessive disorder**
  - Onset: **childhood**
- **Congenital Muscular Dystrophies**
  - **Autosomal recessive** group of disorders
  - Onset: **birth**

MD Duchenne's disease

X-linked Recessive Disorder

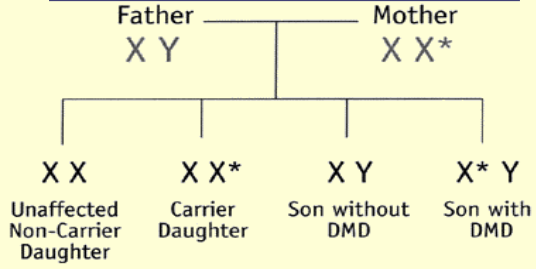

Muscular Dystrophy

X-linked Recessive Disorder

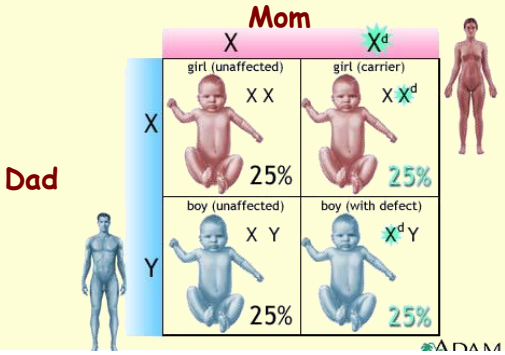

DMD (Psuedohypertrophy)
Pathophysiology

- No production of dystrophin (muscle protein)
- Necessary for muscle contraction
- Muscle fibers degenerate
- Replaced by fat and connective tissue
  - Psuedohypertrophy

- Progressive weakness
- Wasting of skeletal muscles
- Disability and deformity
- Cardiopulmonary complications

Duchenne Muscular Dystrophy
Manisfestations

- **Signs begin 3 to 7 years of age**
- **Initial weakness**
  - legs and hips
- **Muscle Wasting & Weakness**
  - Progressive
  - Symmetrical
  - No loss of sensation
- **Wide-based gait**
- **Calf muscles weak (hypertrophied)**
- **Gower's maneuver needed to rise**

Duchenne Muscular Dystrophy
Gower's Maneuver

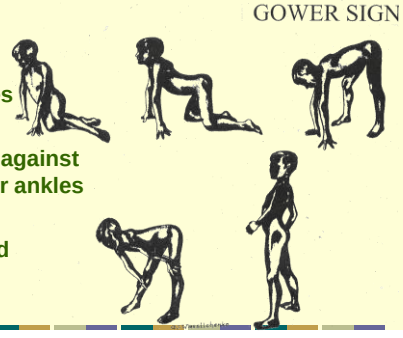

- **Push to knees**
- **Press hands against their knees or ankles**
- **Push to stand**

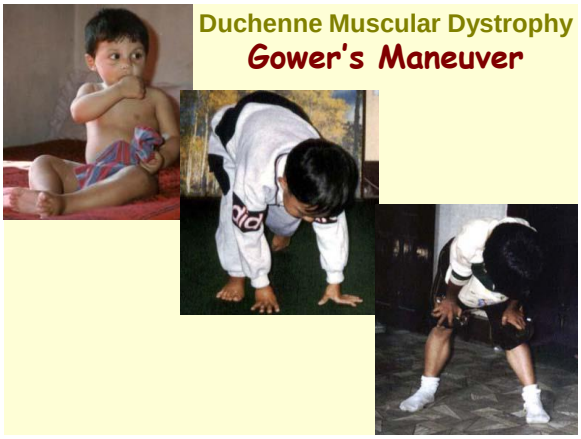

Duchenne Muscular Dystrophy cont. Manisfestations

- **Progressive disability & deformities**
  - Hip & knee contractures
  - Foot deformities
  - Scoliosis
  - Lordosis
  - Ambulation lost by 9-12 yrs
  - Moderate obesity
  - Cardiomyopathy

- **Cardiopulmonary complications**
  - Most common cause of death

Assessment

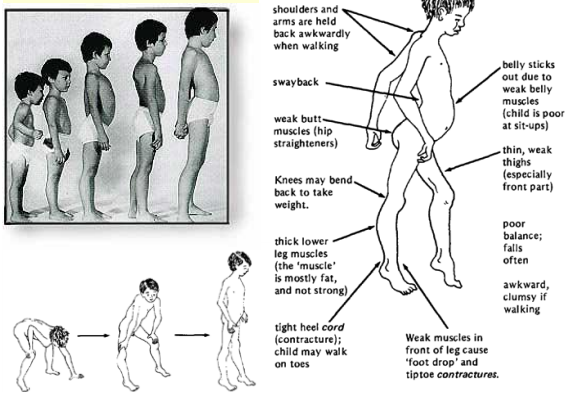

Duchenne Muscular Dystrophy
Diagnostic Evaluation

- Elevated CK (serum creatine kinase)
- EMG (electromyography)
- NCS (nerve conduction study)
- Muscle biopsy
- Genetic testing
- Clinical signs

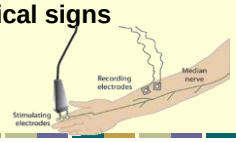

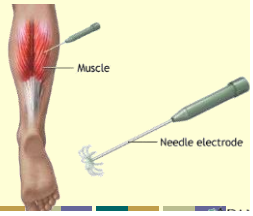

MD Therapeutic Management

- **No cure**
- **Goal:**
  - **Maintain**
    - Ambulation
    - Independence
  - **Prevent or Minimize**
    - Infection
    - Spinal Deformities
    - Contractures
    - Constipation
- **Team Approach**

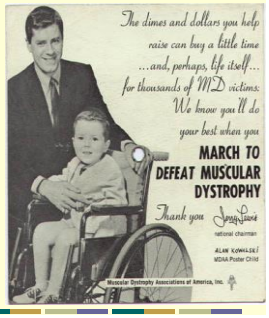

Chiro's play on this double ramp helps both to strengthen his leg muscles and to stretch his tight heel cords.

Therapeutic Management

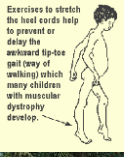

Exercises to stretch the heel cords help to prevent or delay the awkward tip-toe gait (way of walking) which many children with muscular dystrophy develop.

- Physical Therapy
  - Avoid over exercising
  - Daily ankle/foot stretches
- Surgical Procedures
  - Relieve contractures
- Medication
- Recreation and leisure

Duchenne Muscular Dystrophy
Nursing Considerations

- **Monitor cardiac, respiratory & mobility**
- **Parent Teaching**
  - **Maintaining healthy lungs**
    - Smoke free environment
    - Use of flu vaccines
    - Regular assessment of lung function
  - **Genetic screening and counseling**
  - **Accessible environment**
  - **Recreational, leisure activities**
  - **Encourage expression of feelings**
  - **Support Groups**

MUSCULAR DYSTROPHY FAMILY FOUNDATION®
No Boundaries®

Developmental Dysplasia of the Hip

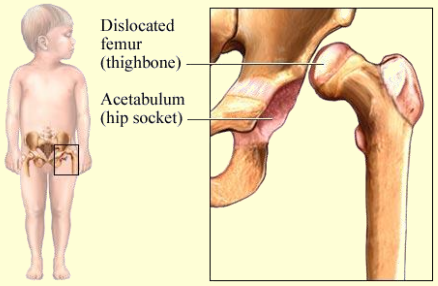

Developmental Dysplasia of the Hip
(AKA ***Congenital Hip Dysplasia***)

- **Abnormal development of the hip**
- **Flattened or shallow acetabulum**
  - *Hip joint instability*
  - *Potential dislocation*
- **Femoral head rides upward**

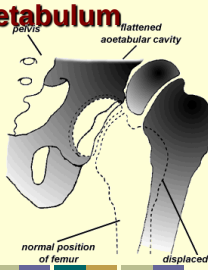

Developmental Dysplasia of the Hip (DDH)

- Hip Instability **1/100**
- Higher incidence in first born
- Girls 4-6x more than boys
- Left hip affected more than right hip (60%)
- Higher in Caucasians and native Americans
- Hip Dislocation **.1-.2/100**
- Breech infants
- Family hx
- Unilaterial (80%)
- Less seen in cultures that carry infants abducted on their hips or back

Types of DDH

- **Acetabular Dysplasia**
  - Mildest form
  - Remains in the acetabulum
  - Abnormal structural developmnt
- **Subluxation**
  - Partial dislocation (riding high)
  - Largest percentage
- **Dislocation**
  - Displaced posteriorly and superiorly
  - The ligamentum teres is elongated and taut

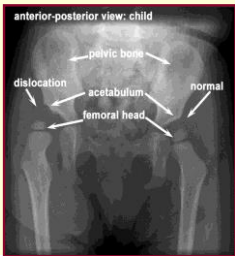

DDH
Diagnosis/Assessment

- Limited abduction of the affected hip
  - Ortolani maneuver
  - Barlow maneuver
  - Knee height
  - Gluteal folds
  - Less movement on affected side
- US
- Xray
- MRI

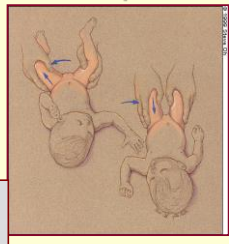

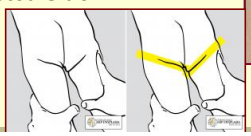

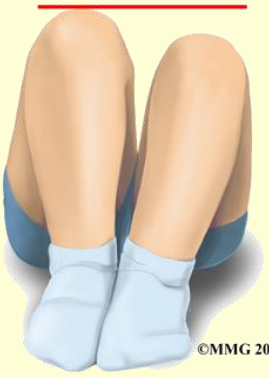

Galeazzi Test

Difference in knee height

DDH
Treatment

- Age Dependent
- Extent of dysplasia
- Correction involves:
  - positioning hip into a flexed, abducted position
  - Continuous pressure of femoral head against acetabulum to deepen contour.

DDH *Treatment*

- <3 months
  - Multiple diapers or splints
  - Pavlik harness (2-6 mo.)
- 4-18 months
  - Skin traction
  - Potential need for surgery
  - Spica Cast (Closed reduction)
- Older than 18 months – 4 yrs.
  - Open reduction surgery followed by Spica Cast
  - Osteotomies (reconstruct alignment)

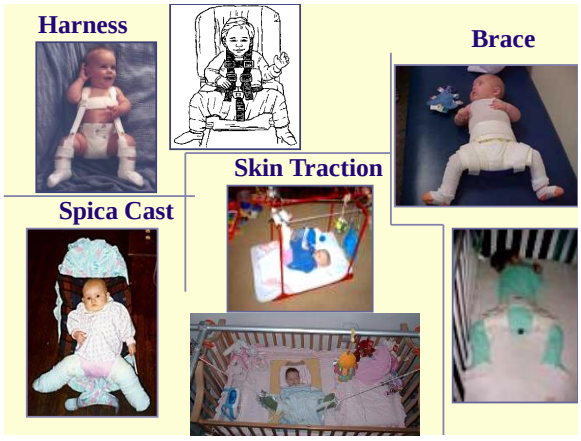

DDH
Treatment important to prevent….

- Weakness of the hip muscles and limping
- Stiffness and loss of movement of the hip
- Painful arthritis

DDH *Nursing Care*

- Cast/Traction/Brace Care
  - Maintain skin integrity
  - Nerve and Circulation
  - PC: Compartment syndrome

DDH Nursing Care

- Accurate Health History
- Teaching
  - Encourage bonding and stimulation
    - *May swaddle, but do not straighten legs*
  - Cast Care
  - Nerve/Circulation assessment
- Emotional Support

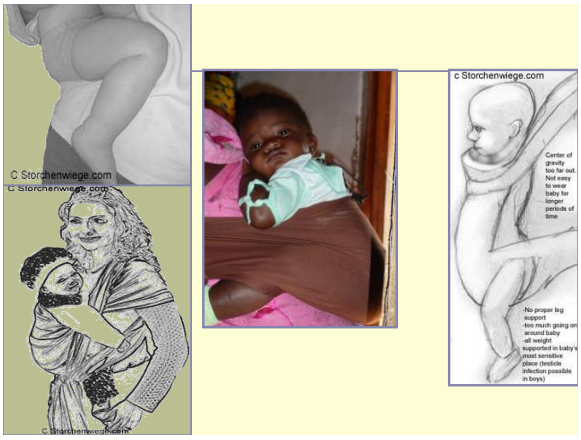

LEGG-CALVÉ-PERTHES DISEASE

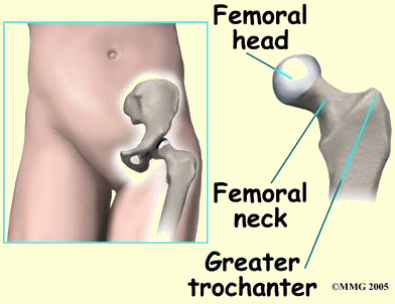

Legg-Calvé-Perthes Disease

- *Avascular* necrosis of the femoral head
- *Self-limiting* disorder of growth
- Incidence
  - **1:12,000** (2004)
  - **1.8:1,200** (2013)
  - **Boys>Girls** (5:1)
  - **2-10 yrs old** (7 yrs average)
  - **Unilateral>Bilateral** (8:2)

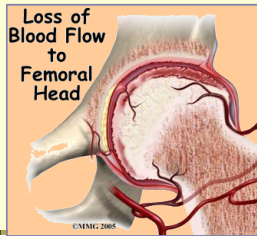

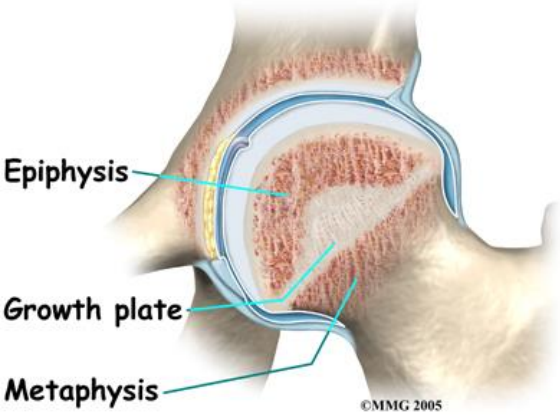

LEGG-CALVE-PERTHES DISEASE
Etiology

- **Interruption of blood supply to femoral epiphysis**
- **Etiology *unknown***
  - **Family history**
  - **Delayed skeletal maturation**
  - **Preceded by:**
    - Mild injury (17%)
    - Breech birth (10%)
    - Low birth weight
    - Coagulation disorder

LEGG-CALVE-PERTHES DISEASE
Pathophysiology

- Self-limiting interruption of blood supply to femoral epiphysis
- Five-stage progression
  - **Prenecrosis to remodeling (reconstitution)**
- Outcome is ***extremely*** variable
  - **Risk of permanent disability**
- Necrosis results in:
  - **Bone softening**
  - **Fracture**
  - **Collapse of femoral head**

LEGG-CALVE-PERTHES DISEASE
Stages – Clinical Manifestations

- Ischemia
- Necrosis (3-6 mo)
- **Revascularization** (1-4 yrs)
- Reossification (bone healing)
- Remodeling

LEGG-CALVE-PERTHES DISEASE
Clinical Manifestations

- **Early symptoms**
  - **Stiffness**
  - **Soreness**
  - **Limp**
  - **Aggravated by increased activity**
- **Later symptoms**
  - **Limited ROM**
  - **Pain (↓after revascularization)**
  - **Weakness**
  - **Muscle wasting**

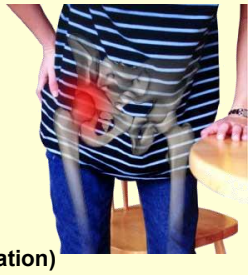

LEGG-CALVE-PERTHES DISEASE
Diagnostic Evaluation

- **Radiographs**
- **Bone Scan**
- **MRI**
- **WBC (rule out)**

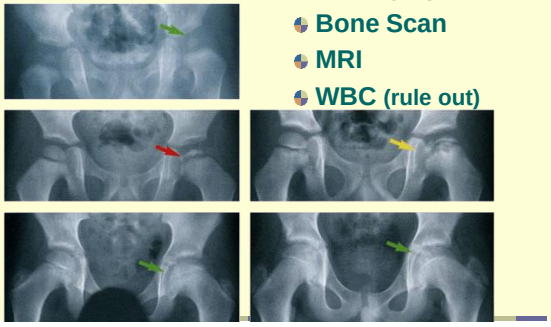

LEGG-CALVE-PERTHES DISEASE
Therapeutic Management

- ***Goal***:
  - **Maintain spherical shape of femoral head during regeneration**

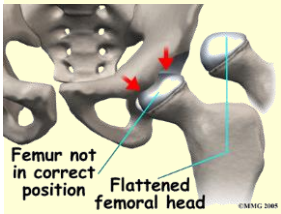

- **Avoid permanent conditions:**
  - Degenerative arthritis
  - Hip dysfunction

LEGG-CALVE-PERTHES DISEASE
Therapeutic Management

- ***Treatment:***
  - **Monitor**
  - **Anti-inflammatory meds**
  - **ROM exercises**
  - **Bracing (containment)**
  - **Nonweight-bearing** (controversial)
  - **Surgery (restore ROM)**
    - **Release adductor muscles**
    - **Treat acetabulum or femur (osteotomy)**

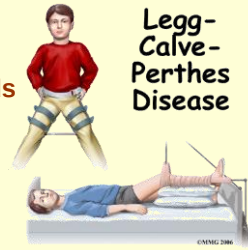

LEGG-CALVE-PERTHES DISEASE
Nursing Management

- **Assessment**
  - Loss of internal hip rotation
  - Limited abduction
  - Pain, Nerve/Circulation
  - Shortening of extremity
- **Ensure adherence to treatment**
  - Teaching (skin care, self-assess, braces)
  - Assess barriers (physical & psychosocial)
  - Collaborative (School RN, PT, OT)

SLIPPED CAPITAL FEMORAL EPIPHYSIS

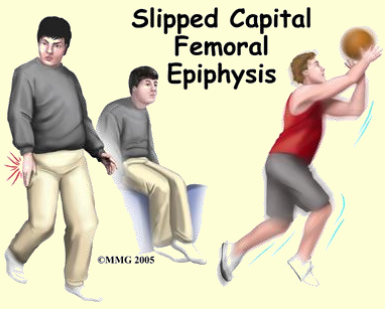

SLIPPED CAPITAL FEMORAL EPIPHYSIS

- ***Femoral head is displaced from femoral neck.***
- **Etiology *unknown***
  - **1:10,000**
  - **Initially unilateral**
    - 25% become bilateral
  - **Increased stress**
    - Sports injuries
    - Obese adolescence
    - 10-15 yrs old
    - Boys>girls

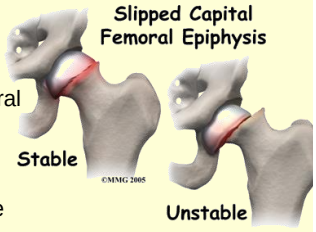

SLIPPED CAPITAL FEMORAL EPIPHYSIS
Pathophysiology

- **Epiphseal plate is thinning preparing for closure** (adolescent hormonal influences)
- **Slippage at proximal epiphyseal plate**
- **Usually gradual** (unless acute injury)
- ***If untreated***
  - Callous formation
  - Avascular necrosis
  - Long term limited ROM

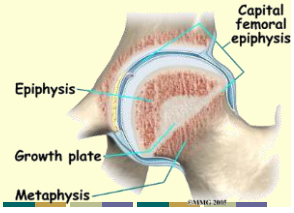

SLIPPED CAPITAL FEMORAL EPIPHYSIS
Clinical Manifestations

- **Limp**
- **Hip or knee pain**
  - **Worse with activity**
- **Loss of ROM**
- **Stable SCFE**
  - Ambulation possible (90%)
- **Unstable SCFE**
  - Ambulation not possible

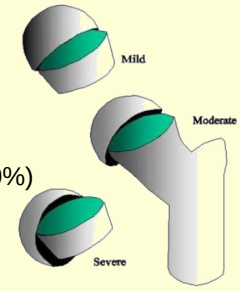

SLIPPED CAPITAL FEMORAL EPIPHYSIS
Diagnostic Evaluation

- **Radiographs (will confirm)**
  - anteroposterior
  - frog-lateral view
- **Verify extent of injury**
  - Bone Scan
  - Ultrasound
  - CT, MRI

SLIPPED CAPITAL FEMORAL EPIPHYSIS
Therapeutic Management

- **Usual treatment**
  - Internal Fixation
- **Severe slips**
  - Reconstruction of femoral head and pinning

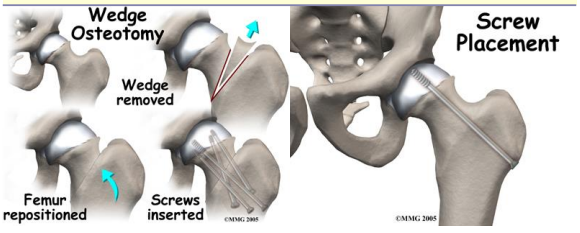

SLIPPED CAPITAL FEMORAL EPIPHYSIS
Nursing Management

Pre-op

- **Maintain alignment**
  - Bedrest
  - Buck's traction (if ordered)

Post-op

- **Nerve & Circ Assessment**
- **Spica cast or traction**
- **Crutches**
  - 4-6 wks
- **Teach**
  - crutch walking
  - skin care
  - weight-control

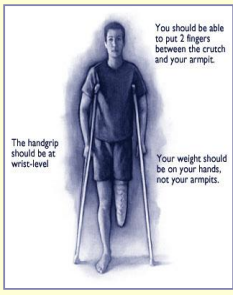

Conclusion

Nursing Assessment

- Child presents with
  - Limp?
  - Hip, thigh or knee pain?

Conclusion

Nursing Assessment

Causes of limp and hip, thigh or knee pain in children

Disorder	Age of onset	Gender (m:f)
Developmental hip dislocation	0 to 2	1:4
Legg-Calve-Perthes	2 to 10	4:1
Slipped capital femoral epiphysis	10 to 15	2:1

Musculoskeletal Problems

Questions

¿