ENT PROBLEMS

*TONSILLITIS

*OTITIS MEDIA

*CROUP

L. Thompson MSN, RN
N124 - Pediatrics

Children are different!



Nostril (Small)

O2 Consumption 2x adult at rest

Tongue (large)

Trachea and Bronchi (narrow)

Tonsils and Adenoids (large)

Oropharynx (less tone)

Alveoli (fewer and smaller)

Large occiput (neck flexion)

Respiratory rate (higher)

Eustachian tubes (horizontal)

TONSILS & ADENOIDS

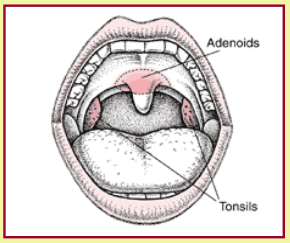

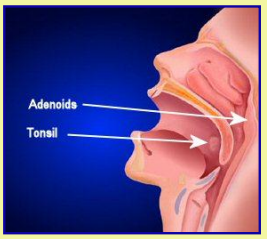

- WHAT ARE TONSILS & ADENOIDS?
- WHAT ARE THEIR FUNCTIONS?
- WHERE ARE THE TONSILS & ADENOIDS?

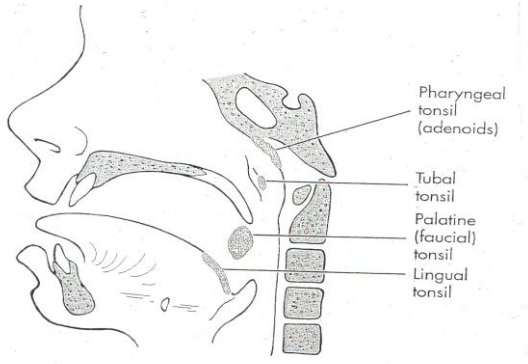

Fig. 32-2 Location of various tonsillar masses.

TONSILLITIS

What is the "Waldeyer's ring"?

- ***Adenoids*** **(pharyngeal tonsils)- nasopharynx**
- ***Palatine*** **Tonsils - both sides of the oropharynx**
- ***Tubal*** **Tonsils – entrance to the eustachian tubes.**
- ***Lingual*** **Tonsils - base of the tongue.**

Definitions

- ***Tonsillitis*** : Infection/inflammation of the palatine tonsils.
- ***Adenitis***: Infection/inflammation of the adenoids

ETIOLOGY

- **VIRAL**
  - Most common in children < 3 yrs. of age
- **Bacterial**
  - Grp. A beta-hemolytic strep in school age children (GABHS)
- Incidence peaks from 4-7 years old.

Why is there a higher incidence in children than adults?

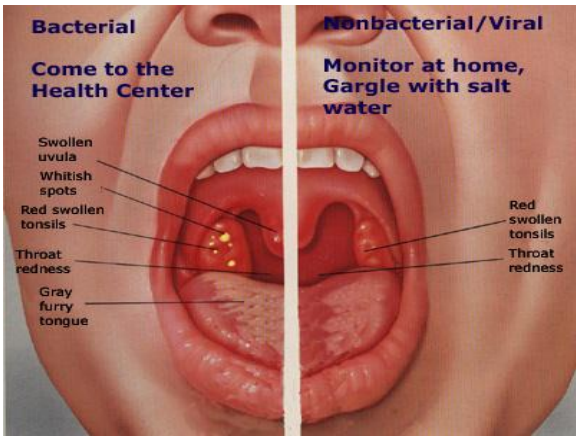

Tonsillitis (Palatine) Diagnostic Evaluation & Assessment

- Painful or difficulty swallowing
- Drooling
- High fever
- Tonsils swollen/red
- Pus

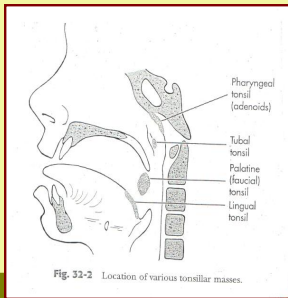

Fig. 32-2 Location of various tonsillar masses.

Adenoiditis Diagnostic Evaluation & Assessment (cont.)

(Pharyngeal tonsils)

- Nasal speech
- Mouth breathing
- Difficulty hearing
- Halitosis
- Sleep apnea

GABHS

(requires rapid strep screening)

- H/A
- Abdominal pain
- N/V

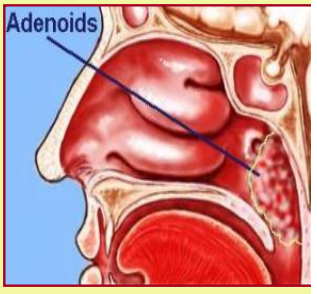

Tonsillitis — THERAPEUTIC MANAGEMENT

***MEDICAL TREATMENT* (non-surgical)**

- ***Viral***
  - Analgesic/antipyretic, fluids, rest
  - Saline gargles, throat sprays
- **Bacterial**
  - Antibiotics
    - Penicillin
    - Erythromycin

Tonsillitis — THERAPEUTIC MANAGEMENT

SURGICAL TREATMENT

- **Tonsillectomy** (palatine tonsils)
- **Adenoidectomy** (pharyngeal tonsils)

- ***INDICATIONS***
  - **Recurrent throat infections** (>3/yrs old, x3 yr)
  - **Hypertrophied tonsils/adenoids** interfere with:
    - ***Eating*** (causing obstruction, tonsillitis)
    - ***Sleeping*** (sleep apnea, adenoiditis)
    - ***Breathing*** (nasal passages blocked, adenoiditis)

Why do we wait until pt is well to remove the tonsils?

Tonsillitis & Adenoiditis — Nursing Diagnoses

- ***Pain*** r/t inflammation of the pharynx.
- ***Risk for ineffective breathing pattern*** r/t obstruction by enlarged tonsils
- ***Risk for fluid volume deficit*** r/t inadequate intake
- ***P.C. Bleeding*** (post-op and 4-5 days)
  - ***Monitor***
    - VS
    - frequent swallowing & throat clearing
    - anxiety
  - ***Position***- sidelying or prone w/ pillow under chest.

Post-op T & A

Discharge Instructions

- ENCOURAGE LIQUIDS (straws?)
- FOODS TO BE GIVEN & AVOIDED
- ACTIVITY
- BOWELS
- PAIN / EARACHE
- SIGNS / SYMPTOMS OF BLEEDING
- LOW GRADE TEMP
- CLINIC APPOINTMENT
- DOs and DON'Ts

Otitis Media

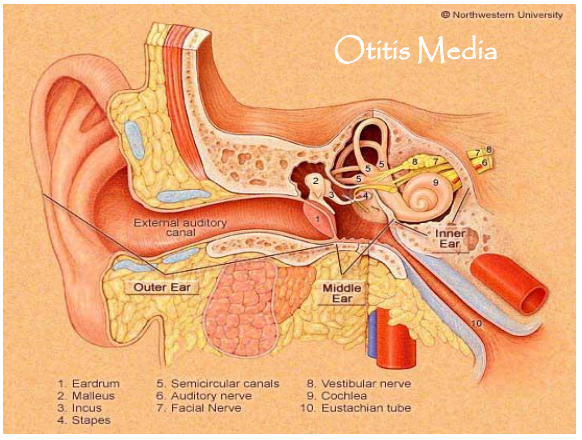

Otitis Media

- **Definition**: ***effusion or infection of middle ear***
  - Infection - viral or bacterial
  - Presence of uninfected fluid

- **Most prevalent childhood disorder after URI**
- ***If untreated***: permanent hearing loss and/or…?

Otitis Media

Increased incidence:

- Age between 6-36 mo & 4-6 yrs
- Males
- Alaskan and Native American
- Home w/smoker
- Cleft palate
- Formula fed infants
- Winter/Spring
- Pacifier use

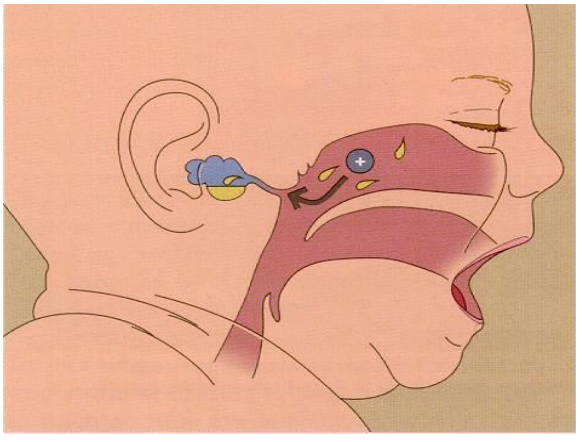

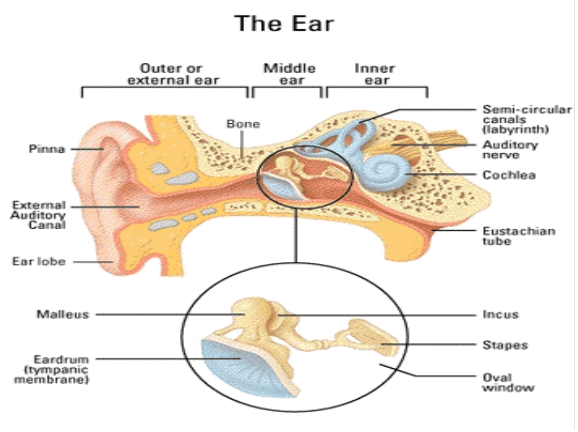

Assessment

- **Infant (preverbal)**
  - Tendency to rub, pulls affected ear
  - Rolls head from side to side
  - Crying, fussy, restless, irritable
  - Difficulty comforting child
  - Loss of appetite
- **Older child**
  - Verbalizes ear pain
  - Irritability
  - Lethargy
  - Loss of appetite

Assessment

- **Observe outer ear**
- **Examine ear canal**
  - Straighten ear canal
  - Choose otoscope tip that allows visualization
  - Rest instrument on a hand
- **Visualize tympanic membrane**
  - Outline of malleus, cone of light
  - Color is pinkish gray if tension is normal
- **Mobility of eardrum** **(inject air)**
  - Detect fluid



Assessment

Acute Otitis Media

***Assessment with otoscope*:**

- Membrane reddened, inflammed
- Malleus
- Cone of light
- If fluid present:
  - decreased mobility on pneumatic exam

Signs and Symptoms

- Rapid onset of:
  - Pain (sharp)
  - Rhinitis, URI
  - Sudden fever

Otitis Media

THERAPEUTIC MANAGEMENT

- **Acute Otitis Media (Causative Organism)**
  - Streptococcus pneumoniae
  - Haemophilus influenza type b
  - Moraxella catarrhalis
  - Staphylococcus (chronic OM)
- **If treatment *unsuccessful*:**
  - Tympanocentesis to obtain culture
- **Treatment**
  - "Watchful waiting" approach (low risk criteria)
  - Antibiotics (usually amoxicillin) 7-14 days
  - Analgesics, antipyretics
  - Nasal Decongestants for 3 days- open ET

Otitis Media

Parent Teaching

- Complete antibiotics
- Conductive hearing loss up to 6 mo.
- Do not clean ears with Q-tips
- Do not continue to use decongestants gtts >3 days
- Encourage parent to offer liquids and soft food
- Return to clinic if no improvement in 24-48 hrs.

Assessment — OME

Otitis Media with Effusion (Serous Otitis Media)

- Usually follows a AOM
- Children 3-10 yrs.

***Assessment with otoscope*:**

- Tympanic membrane retracted
- Malleus prominent
- Cone of light (light reflex) absent
- No movement (pneumatic exam)

Signs and Symptoms

- c/o fullness, ringing or popping
- Hearing loss 20-40 dB (*Conductive*)

OME — THERAPEUTIC MANAGEMENT

- ***Goal*** of Rx is to supply air
- ***Control the cause***: Allergies, enlarged adenoids

MEDICAL

- Meds: antihistamines, decongestants

SURGICAL (hearing loss >20dB greater than 3 mo)

- Tympanocentesis
- Tubal Myringotomy w/ pressure equalizing tube insertion

- **Tympanostomy Tubes (P.E.) tube**
  - Depending on tube size, last 6 mo to 2-3 years
  - As ear grows, tubes will fall out
  - Placed in 5-10 minutes under brief general anesthesia

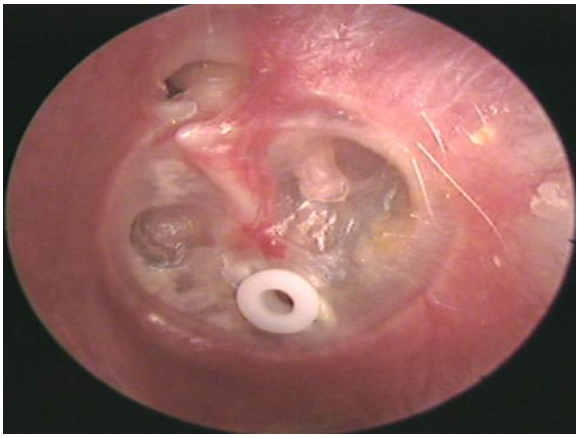

Myringotomy Post-op Management

Parent Teaching

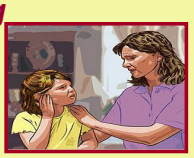

- **Caution parents**:
  - No water in ears!
  - Bathe rather than shower
  - Shower w/ear plugs
  - Swimming prohibited or with ear plugs
- **Hearing problem** (temporary)
  - Notify teacher, move child to front seat
  - Conductive vs. Perceptive Hearing Loss
  - Tympanostomy Tube (PE tube) falls out

Nursing Care

- ***Pain*** r/t inflammation and pressure on tympanic membrane.

  Interventions?

- ***Infection*** r/t to presence of pathogens.

  Interventions?

- ***Powerlessness*** r/t repeated episodes of Otitis Media.

  Interventions?

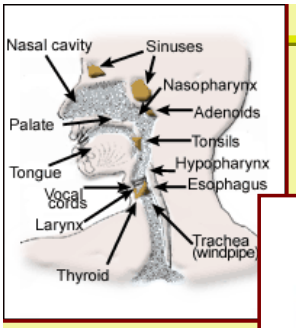

What is Croup?

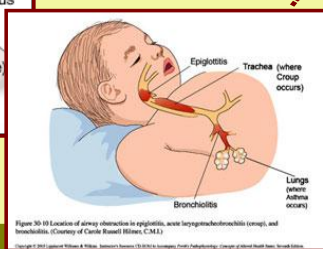

Figure 30-10 Location of airway obstruction in epiglottitis, acute laryngotracheobronchitis (croup), and bronchiolitis. (Courtesy of Carole Russell Hilmer, C.M.I.)

Copyright © 2015 Lippincott Williams & Wilkins. Instructor's Resource CD-ROM to accompany Porth's Pathophysiology: Concepts of Altered Health States, Seventh Edition.

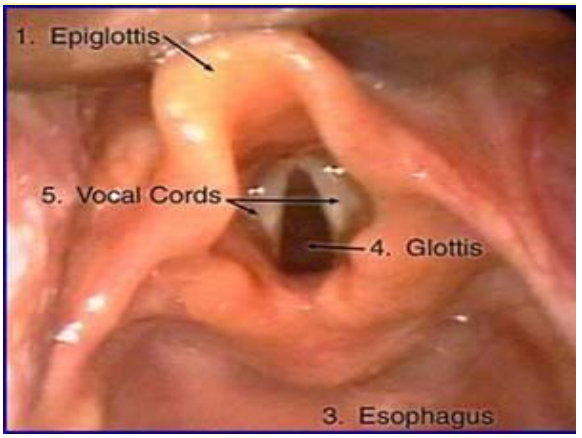

CROUP

Broad class of upper airway illnesses

- **Acute Laryngotracheobronchitis** (LTB)
- **Acute Spasmodic Laryngitis** (Spasmodic Croup)
- **Acute (Bacterial) Tracheitis**
- **Acute Epiglottitis**



CROUP

Diagnostic Evaluation

- **Respiratory Assessment**
  - **Croupy or barking cough**
  - **Inspiratory stridor**
  - **VS, SaO2**
  - **Respiratory distress**
    - Sound?
    - Video of 2-yr-old
- **History**
- **Xrays, labs, cultures**



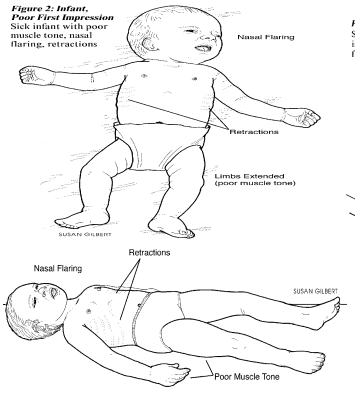

Figure 2: Infant, Poor First Impression
Sick infant with poor muscle tone, nasal flaring, retractions

Figure 4: Child, Poor First Impression
Sick child with poor muscle tone, nasal flaring, retractions

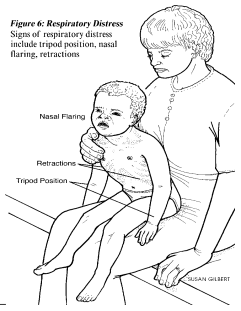

Figure 6: Respiratory Distress
Signs of respiratory distress include tripod position, nasal flaring, retractions

- **Agitated**
- **Symptoms worse at night**
- **Lasts 3-4 days**

CROUP

Treatment

- **Airway management**
  - Reposition
  - Corticosteroids
  - Racemic Epinephrine
  - Intubation
- **Fluids (IV or oral)**
- **Rest (calm environment)**
- **Humidification**
- **Humidified O2**
- **Antibiotics**

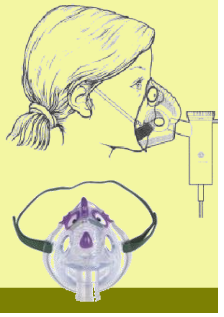

CROUP

- **Acute Laryngotracheobronchitis** (LTB)
  - **Cause**
  - **Assessment**
  - **Treatment**
- **Acute Spasmodic Laryngitis** (Spasmodic Croup)
  - **Cause**
  - **Assessment**
  - **Treatment**

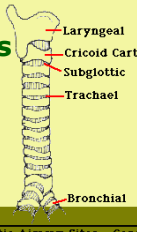

CROUP

- **Acute Tracheitis**
  - **Cause**
  - **Assessment**
    - recent URIs
    - stridor, croupy cough
    - purulent secretions
    - high fever
    - tripod position
  - **Treatment**
    - humidified 02, possible intubation
    - antipyretics, IV antibiotics, fluids

CROUP

- **Acute Epiglottitis**
  - **Cause (usually Hib)**
  - **Assessment**
    - **(4 Ds)**
      - ***D*rooling**
      - ***D*ysphagia**
      - ***D*ysphonia**
      - ***D*istress**
    - Fever
  - **Treatment**
    - *DO NOT INSPECT THROAT*
    - Humidified 02
    - Emergency intubation (have ready)
    - Antipyretics
    - IV antibiotics
    - Fluids

CROUP

Nursing Diagnosis

- Ineffective Airway Clearance
- Risk for Fluid Volume Deficit
- Fear r/t dyspnea & hospitalization

SUMMARY

Questions???