1

MALE CONGENITAL ANOMALIES

ROSLYN GARRIGAN NOTT MSNED RN
NURSING INSTRUCTOR
RNOTT@DHS.LACOUNTY.GOV

2 HYPOSPADIAS

- Definition:
  - Opening of the urethral meatus below the normal placement on the glans of the penis
- Degree can vary
- Chordee (downward curvature of the penal shaft is usually seen in more severe forms)

3 HYPOSPADIAS STATISTICS

- One of the most common congenital anomalies
- 1 in every 250 male children
- ↑ risk if father or sibling has hypospadias
- Other contributing factors
  - Maternal age ≥ 35
  - Intrauterine exposure to environmental chemicals
  - Possible genetic mutation

4 HYPOSPADIAS CLINICAL MANIFESTATIONS

- Diagnosis is based on physical exam
  - Ventral placement of the urethral opening
- Altered urinary stream

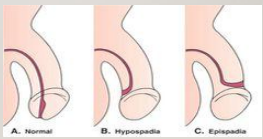

5 HYPOSPADIAS TREATMENT

- Surgical correction
  - Outpatient procedure
  - Chordee is released/ Urethra lengthened
  - Meatus is placed at the penile tip
  - Ideally done 6-12 months of age
  - Infant should not be circumcised because the foreskin may be used in the surgical reconstruction

6 EPISPADIAS

- Definition: Urethral meatus is above the normal placement on the glans of the penis

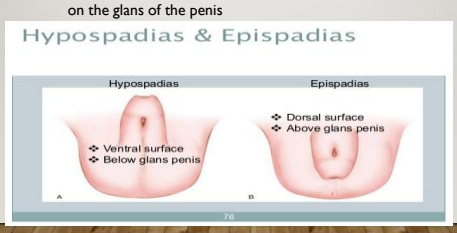

7 EPISPADIAS
ETIOLOGY

- Epispadias is rare
- Often associated with bladder exstrophy
  - Lower urinary tract structures are outside the abdominal wall

8 BLADDER EXSTROPHY

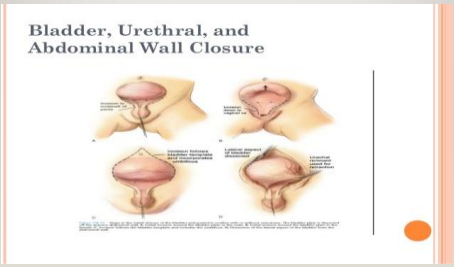

9 EPISPADIAS
TREATMENT

- Surgical correction
  - May include bladder neck reconstruction
  - Lengthening of the penis & urethra
- If bladder exstrophy is present surgical correction may occur in stages

10 HYPOSPADIAS/ EPISPADIAS
NURSING INTERVENTIONS

- Educate parents
  - Post-op care
    - **Pressure dressing to decrease edema**
      - MD will remove appox. 4 days after surgery

11 HYPOSPADIAS/ EPISPADIAS
NURSING INTERVENTIONS

- Educate parents (Post-op cont.)
  - Care of stent or urinary drainage bag system
    - Some infants may have a urinary stent which will drain into the diaper
    - Others require a closed drainage bag system

12 HYPOSPADIAS/ EPISPADIAS
NURSING INTERVENTIONS

- **Educate parents**
  - Postoperative care (cont)
    - Encourage **increased fluid intake**
      - Maintain hydration and free urine flow

13 HYPOSPADIAS/ EPISPADIAS NURSING INTERVENTIONS

- **Educate parents**
  - Postoperative care (cont)
    - Monitor for S/s of infection
      - Temp, urine cloudiness or foul smell
      - Report UTI immediately
    - Post op prophylactic antibiotics
    - Pain medication prn

14 HYPOSPADIAS/ EPISPADIAS NURSING INTERVENTIONS

- Educate parents
  - Postoperative care (cont)
    - Provide quiet diversional activities
    - Transport in wagon
    - Provide favorite toys/music etc

15 CRYPTORCHIDISM

- Definition: Occurs when one or both testes fail to descend through the inguinal canal into the scrotal sac
- Undescended or hidden testes

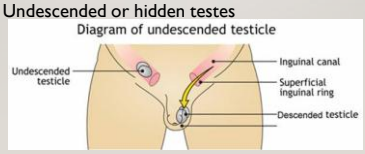

16 CRYPTORCHIDISM
ETIOLOGY

- Most common congenital testicular condition
- Approx. 4.5% of normal healthy boys have at least one undescended testis at birth

17 CRYPTORCHIDISM
ETIOLOGY

- Effects approx. 30% of premature male infants
  - Begin to descent from the abdomen between 32-36 weeks
- Potential factors
  - Maternal hormones, genetics, prematurity, low birth weight
  - Exact reason unknown

18 CRYPTORCHIDISM
CLINICAL MANIFESTATIONS

- Testes the are not palpable
  - Or easily guided into the scrotom
- Previously descended testis can ascend into the extrascrotal position
- ↑ Risk for testicular malignancy & infertility

19 CRYPTORCHIDISM
TREATMENT

- Initially observed for 6 months
  - Spontaneous descent is common
- Orchiopexy
  - Brings the testes down into the scrotal sac and suture it in place

20 CRYPTORCHIDISM
TREATMENT

Orchiopexy (cont)
- Laparoscopic & outpatient basis
- Most common complication is bleeding & infection
- Optimal surgical time frame
- Between 6-15 months
  - Goal: ↓ risk of infertility, malignancy & normal appearing scrotom
- Teaching: Adolescent male perform testicular self-examinations throughout life

21 CRYPTORCHIDISM
NURSING INTERVENTIONS

- Educate parents
- Provide resources
- Postoperative management
  - Pain & swelling
  - Urine output (UOP)
  - Bleeding
  - Infection

22 TESTICULAR TORSION

- Definition
  - Rotation of the testicle that interrupts blood flow
  - If not treated emergently will cause testicular damage (tissue death)
  - Surgical emergency

23 TESTICULAR TORSION
ETIOLOGY

- Most common:
  - Males < 20 years old
- Reasons:
  - Trauma
  - Spontaneously
  - Anatomical abnormality

24 TESTICULAR TORSION
CLINICAL MANIFESTATIONS

- Sudden severe pain
- Progressive scrotal pain
- Erythema & edema

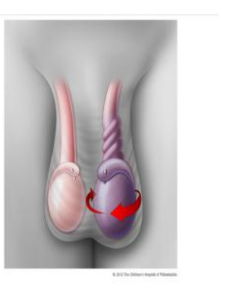

25 TESTICULAR TORSION TREATMENT

- Surgical emergency
  - Straightens & fixates the affected testicle and other testicle to prevent torsion
  - If testicle is necrotic
    - Removed

26 HYDROCELE

- Hydrocele
  - "Painless swelling of the scrotum caused by a **collection of fluid"**
  - Diagnosed: Transillumination
    - Shining flashlight through scrotom
      - Fluid will illuminate
  - If persists beyond 18 months should be surgically repaired
    - Aspiration or surgical drainage performed

27 HYDROCELE

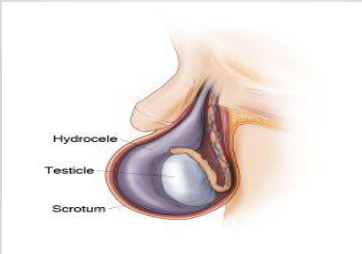

28 SPERMATOCELE

- "A firm, **sperm-containing painless cyst** of epididymis"
- May be visible with transillumination
- Cause: unknown
- Treatment: surgical removal

29 VARICOCELE

- "**Dilation of veins** that drain the testes"
- Cause: unknown
- Associated with infertility
- Treatment
  - Repaired: injection of sclerosing agent
  - Surgical ligation of spermatic vein

30 EPIDIDYMITIS

- "Acute painful inflammatory process of the epididymis"
- May be caused by:
  - Infection, trauma or urinary reflux (UTI)
    - Infection: Gonorrhea or chlamydia
- Treatment: antibiotics
  - If due to STD: antibiotics for both partners

31 EPIDIDYMITIS

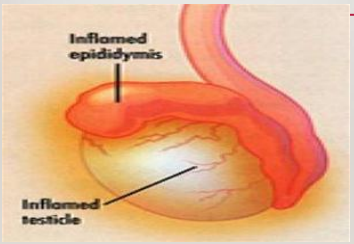

32 EPIDIDYMITIS

- Treatment
  - Elevation of scrotom
  - Ice packs
  - Analgesics

33 PHIMOSIS

- Phimosis
  - "Tightening or constriction of the foreskin around the **head of the penis**"

  - Caused: edema or inflammation of the foreskin

34 PHIMOSIS

- Phimosis
  - "Associated with poor hygiene"
  - Goal of treatment
    - Return foreskin to natural position
    - Manual reduction (push glans back)
    - Topical corticosteroid may be applied

35 PARAPHIMOSIS

- "**Tightness of the foreskin** resulting in the inability to pull it forward from the retracted position"
  - Preventing: return over the glans
  - Ulcer & edema can develop
- Treatment: Warm soaks, antibiotics, circumcision

36 THANK YOU

The End!