Thorax, lungs, and breasts

Percussion- https://www.youtube.com/watch?v=CLey562UDc4

Thorax, lungs, and breasts

Naira Arquell RN, MSN
N113 - Introduction to Medical Surgical Nursing

Objectives (refer to syllabus page 26)

- Identify questions when assessing the thorax, lungs, and breasts
- Discuss the four methods utilized for the assessment of the thorax, lungs, and breasts
- Describe the various characteristics associated with the thorax, lungs, and breasts
- Identify cultural variations related to the thorax, lungs, and breasts
- Discuss the thorax, lungs, and breasts variations with older adults
- Identify the thorax, lungs, and breasts
- Health promotion and associated patient/family teaching

Guide to Assessment of Lungs and Thorax

- Assemble Equipment
- Explain Procedure to the patient and Wash hands
- Position patient in **Semi-Fowler's or Fowler's**
- History-taking
- Gown or drape patient to prevent unnecessary exposure
- Provide a quiet place for patient comfort and for auscultation
- Provide adequate lighting

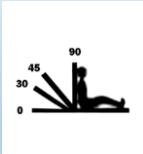

Guide to Assessment of Lungs and Thorax
Use of proper Techniques

- Compare symmetry of thorax – side to side comparison
- Start at neck, then posterior, right and left lateral, then anterior thorax
- Respiratory rate determination
- Rhythm determination
- Depth determination

Guide to Assessment of Lungs and Thorax
identify abnormalities

- Define boundaries of abnormality found
- Describe accurately what you see
- Do not allow patient to hyperventilate during the exam.
- Avoid bony prominences during the exam (poor sound conduction)
- Record findings accurately
- Be ready to report your findings

Identifying Assessment Questions

- Family history of illnesses
- Allergies
- Tuberculosis, COPD, Asthma
- Hx of smoking
- Occupational hazards (fumes)
- Medications
- Current problems (cough, pain, etc.)

Assessing the Thorax and Lungs

- Ideally examine posterior chest prior to anterior
- Sitting position is preferred (Semi-Fowler's or high Fowler)
  - Why?
- Explain to client what you are going to do
- Provide privacy
- Drape anterior chest when it is not being examined

Thoracic/ Chest landmarks

- The first consideration is being able to accurately count and localize the ribs.
- The round and curved rib shown on the very top of the thorax is the first rib. It is at the level of the clavicle. It's location behind the clavicle and the manubrium, makes it difficult to palate this rib.

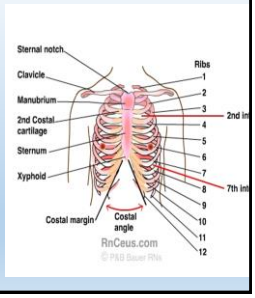

Thoracic/ Chest landmarks

- The space immediately below this 1st rib is the first intercostal space. Slide the finger down just a few centimeters from the suprasternal notch the 2nd rib will be found.
- The interspace just below this rib is the second intercostal space.

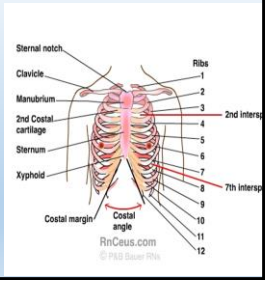

Thoracic/ Chest Landmarks

- Midsternal line
- Midclavicular line
- Anterior Axillary line
- Midaxillary line
- Right Scapular line
- Vertebral line

Please see Berman, page 553 for diagram (figure 30-21 and 30-22)

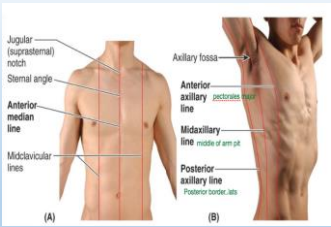

Methods and order utilized for chest assessment/examination

- General inspection and history of the patient
- Visual Inspection
- Palpation
- Percussion
- Auscultation

Client History

- The history is very important to obtain **before** you begin your examination.
- The nursing history may repeat some of the same items that the medical history has obtained but the nurse will have different objectives in mind when asking questions and gathering data

Client History

Following is a guide to the history-taking process. (Lehrer, 1990).

- Reason for Hospitalization (medical diagnosis from chart)
- Family Medical History -Family history (COPD, TB, allergy, asthma, smoking), Social history of family
- Occupational history -Type of work patient is engaged in; are they exposed to air or chemical pollutants, Exposure to exotic animals, birds; pigeons, parrots, parakeets
- Consider the part of the country they are from; some diseases are endogenous

Client History

- **General Patient Medical History**
  - Major medical problems; heart, GI, GU, respiratory surgery, etc.
  - Allergy
  - Childhood diseases
- **Specific Medical History** (specific to this hospitalization)
  - Pain – pulmonary pain, pleural pain, muscular pain, cardiac pain, describe in detail.
  - Cough – type of cough, type and character of sputum, blood in sputum
  - Hemoptysis
  - Dyspnea – ask circumstances surrounding trouble breathing
  - Hoarseness
  - Wheezing

THORAX and LUNGS: Initial Survey

- Observe Thorax for
  - Symmetry (ex. Patient has right sided pneumonia- asymmetric lungs excursion
  - Vital signs- respiratory rate, rhythm, depth
  - Sputum(color)
  - Respiratory excursion and efforts of breathing to assess chest movements
  - Tenderness
  - Anterior/posterior(AP) diameter approximation
- Assess patient's color
- Listen to patient's breathing
- Assessment: Overall oxygenation status

Chest Shape and Size

- Adults
  - Thorax is oval
  - AP diameter is half its transverse diameter(1:2)

(*Increased AP diameter is normal for COPD patients*)

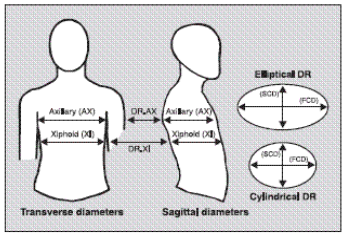

AX = axillary; DR = diameter ratio; FCD = front of child; SCD = side of child; XI = xiphoid.

Posterior Thorax

- Inspect-
  - Shape & symmetry
  - Spinal alignment
    - Note three normal curvatures
      - Cervical
      - Thoracic
      - Lumbar

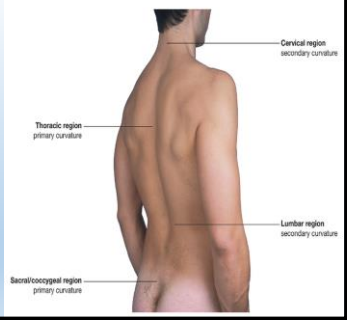

Posterior Thorax

- Palpate
  - Normal findings
    - Skin intact
    - Uniform temperature
    - No tenderness
    - No masses
    - No pain

Palpate: Respiratory Excursion

- Normal Findings
  - Full & symmetric chest expansion
  - Normal - thumbs should separate 1 1/2 to 2 inches during inspiration
- Abnormal Findings
  - Asymmetric and or decreased chest expansion

Palpation: Posterior Thorax (cont.)

- **Tactile Fremitus**
  - Definition: the faintly perceptible vibration felt through the chest wall when the client speaks
- Procedure
  - Place palm on landmarks
  - Have client repeat "one, two, three"
- Normal finding
  - Bilaterally symmetrical

Next step is to Percuss the Thorax

- Definition
  - A method of medical diagnosis in which various areas of the body, especially the **chest**, back, and abdomen, are tapped to determine by resonance the condition of internal organs.
  - Performed to determine whether underlying lung tissue if filled with air, liquid, or solid material and to determine the positions and boundaries of certain organs (Berman, pg. 558)

22

Percussion

- Percussion is performed from apex to the bases
- Normal Lung fields are resonant (drum)
- Dullness on percussion indicates consolidation
  - Pneumonia/ fluid filled
- Hyper-resonance
  - Excess air (pneumothorax)

- Demo:
  - Percussion of Thorax https://www.youtube.com/watch?v=CLey562UDc4

24

Question:
The doctor is percussing the thorax. Normal lung field will sound:

- 1. Dull
- 2. Resonant
- 3. Hyper-resonant
- 4. Adventitious

Auscultate the Chest

- Use flat disc of diaphragm
  - Best: high pitch sounds
- Use systematic side to side approach
- Ask client to take slow, deep breaths, through mouth

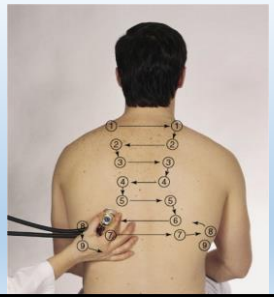

Anterior Thorax Assessment

- Inspect breathing pattern
  - Rate
  - rhythm
  - quality
  - effort
- Inspect costal angle

Anterior Thorax Assessment (cont.)

- Palpate anterior chest
  - Respiratory excursion
  - Tactile fremitus
- Auscultate
  - Anterior chest systematically

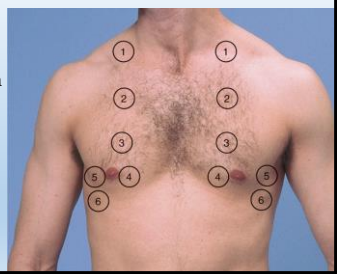

Thorax and Lung Assessment- chest auscultation

https://www.youtube.com/watch?v=43edNi0NkSg

Anterior Breath Sounds

Posterior Breath Sounds

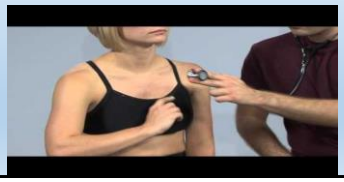

Chest Deformities

- Pectus Carinatum-
  - Pigeon Chest
    - Narrow transverse diameter
    - Increase AP diameter
    - Protruding sternum
    - Permanent deformity
    - Congenital disorder

30

Chest Deformities (cont.)

- Pectus Excavatum
  - Funnel Chest
    - Congenital defect
    - Depressed sternum
    - Narrowing AP diameter
    - Abnormal pressure on the heart may result in altered cardiac function

31

Chest Deformities

- Barrel Chest
  - Ratio of AP to transverse diameter is 1:1
    - Kyphosis
      - Excessive convex curvature of the thoracic spine
    - Emphysema
      - Chronic pulmonary condition in which the air sacs (alveoli) are dilated and distended

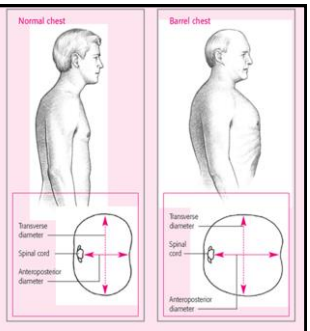

Question:
Which of the following physical assessment findings are normal for COPD patients?

- 1. Increased Antero-posterior chest diameter
- 2. Underdeveloped neck muscles
- 3. Collapsed neck veins
- 4. Increased chest excursion with respiration

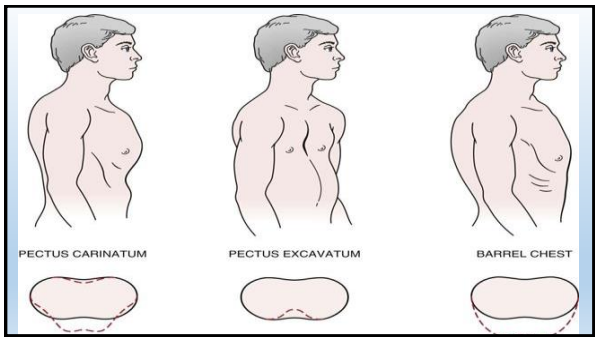

Scoliosis

- Lateral curvature/deviation of the spine
- Scoliosis in adults may be
- caused by trauma
- may have been present since birth
- or may be considered idiopathic scoliosis, which has no identifiable cause

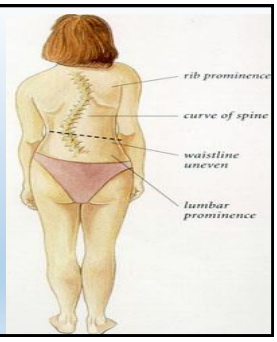

Do you have any questions so far?

Now Let's talk about….

Lungs

- The lungs are the cone-shaped organs located in the pleural spaces in the right and left sides of the bony thorax.
- The right lung is divided into three separate and distinct lobes by deep fissures.
- The left lung has only two lobes.
- The purpose of the lungs is most importantly the exchange of gases in the body.
- Air is moved into the lungs through the air passages by the use of the respiratory muscles.

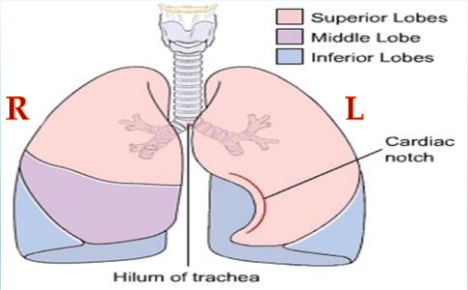

Terms used to document locations for chest physical assessment include:

- Supraclavicular - above the clavicles
  - Infra-clavicular - below the clavicles
- Inter-scapular - between the scapulae
- Infra-scapular - below the scapulae
- Bases of the lungs - the lowermost portions
- Upper, middle, and lower lung fields

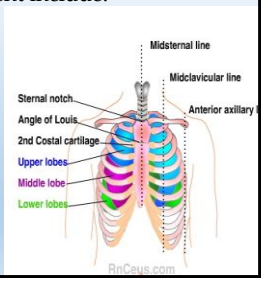

LUNGS "Normal Breath Sounds"

- Auscultate lungs for the following- breath sounds: breath sounds – side to side comparison

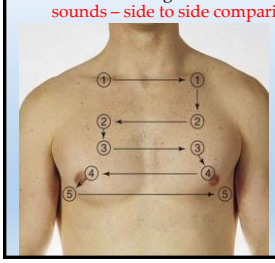

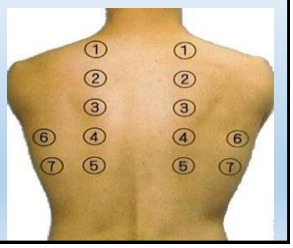

LUNGS "Normal Breath Sounds"

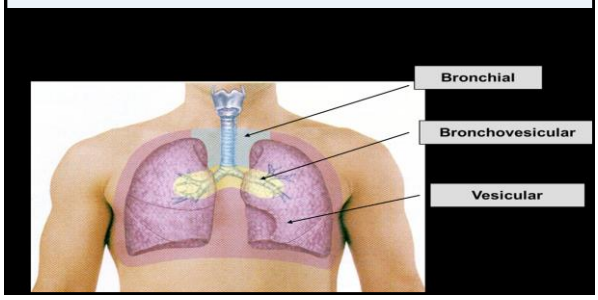

LUNGS "Normal Breath Sounds"(cont.)

- Auscultate lungs for the following- breath sounds
- Vesicular
  - Description
    - Soft-intensity
    - Low pitched (gentle sighing)
  - Best Location
    - Peripheral lung
    - Base of lung

Vesicular Breath Sounds

- Inspiration **longer** than expiration
- Inspiration is **louder** than expiration
- **No gap** between inspiration & expiration
- Heard best at **bases of lungs**

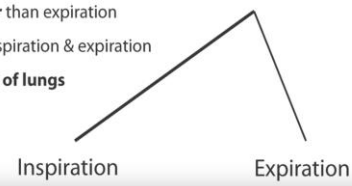

LUNGS "Normal Breath Sounds"(cont.)

- Broncho-vesicular
  - Description
    - Moderate intensity & pitch
    - "blowing" sound created by air movement through larger airway (Berman, pg. 555, table 30-7)
  - Location
    - Between scapulae and lateral to sternum
    - First and second intercostal spaces

LUNGS "Normal Breath Sounds"(cont.)

- Bronchial (tubular)
  - Description
    - High pitched, loud, harsh sounds
    - Created by air moving through trachea
  - Location
    - Over trachea
  - Not normally heard over lung tissue

Bronchial Breath Sounds

- **Mimicked** by listening over the trachea
- **Louder** than vesicular breath sounds
- Inspiration & expiration **same loudness**
- Inspiration & expiration **same duration**
- **Gap** between inspiration & expiration

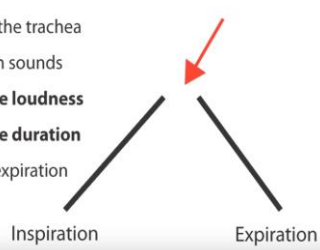

Bronchial (tubular) breath sounds should not be heard over normal lung parenchyma

Vesicular (normal) --> Bronchial (abnormal)

Found in:
- consolidated lung of pneumonia
- atelectasis
- pulmonary mass

LUNGS "Adventitious Breath Sounds"

- Four types of adventitious (abnormal) breath sounds
  - Crackles or (rales)
  - Wheezes
  - Rhonchi (gurgles)
  - Pleural friction rubs
  - Auscultation of rales, wheezes, rhonchi, or pleural friction in one or both lungs means patient condition is not improved)
  - Absent breath/lung sounds relates to pneumothorax (collapsed lungs)- in trauma patients

Crackles (Rales)

- Description
  - Fine, short, interrupted crackling sound
  - Usually high pitched
  - Simulate sound by rolling piece of hair near ear
    - (Berman, pg. 556, table 30-8)
- Cause
  - Air passing through fluid in any air passage
- Commonly heard at the bases on inspiration
- https://www.youtube.com/watch?v=K3NfdPhxSM4

Rhonchi (Gurgles)

- Description
  - Continuous, low-pitched, coarse, harsh sounds
  - "Snoring quality"
  - May decrease with coughing
    - (Berman, pg. 556)
- Cause
  - Air passing through narrowed air passages due to secretions, swelling or tumors
- Predominantly heard over trachea and bronchi
- Rhonchi vs Crackles (aka rales)

52

Wheezes

- Description
  - Continuous, high-pitched, squeaky musical sounds
  - Best heard on expiration
  - Not usually cleared by coughing
    - (Berman pg. 556)
- Cause
  - Air passing through a constricted bronchus as a results of secretions, swelling or tumors
- Heard over all lung fields
- https://www.youtube.com/watch?v=fKlH-kqc_tY

53

Friction Rub

- Description
  - Superficial grating or creaking sounds
  - Not relieved by coughing
    - (Berman, pg. 556)
- Cause
  - Rubbing together of inflamed pleural surfaces
- Commonly heard over areas of greater thoracic expansion e.g. lower anterior and lateral chest
- https://www.youtube.com/watch?v=vlg80ZpxqpU

54

Review of Sounds

- Review at home
- https://www.youtube.com/watch?v=O8OC7EiqBKQ
- www.easyauscultation.com
- https://www.youtube.com/watch?v=sszEaJ1selg&index=13&list=PLLKSXV1ibO86qgE2y9cMqNFmh6LfOa8RM

55

Lifespan Considerations- Infants

- Thorax is rounded
  - Anteroposterior and transverse diameters are equal
  - It is also cylindrical with the nearly equal diameter at the top and the base
  - Auscultated sounds will be louder and harsher
- Tend to be abdominal breathers not thoracic breathers using their diaphragm
- The right bronchial branch is short & angles down
  - Easier for small objects to be inhaled

Lifespan Considerations-Children

- By the age of 6 ratio of anteroposterior and transverse diameter is 1:2
- Tend to breath more abdominal breathing than thoracic
- During the rapid growth spinal curvature and rotation(scoliosis) may appear
- Children should be assessed for scoliosis by the age of 12 and annually until their growth slows

Variations in older adults

- Elderly
  - Thoracic curvature may be accentuated (Kyphosis) because of osteoporosis, which will change the shape of the thorax
  - Anteroposterior diameter widens giving the person a barrel-chested appearance
  - Alveoli losses elasticity(become fibrotic) decreasing exertional capacity and ↓ respiratory excursion
  - ↓ number and effectiveness of cilia (↓mucous removal)
    - Greater risk for pulmonary infection

Promotion of health screening, health maintenance including self care and associated teaching

- Health promotion plans need to be developed according to the needs, desires, and priorities of the client
- The client decides on the health promotional goals
- The nurse acts as a recourse person
  - Review and summarize data from assessment
  - Reinforce the strength and competences of the client
  - Identify health goals and behavior-change options
  - Identify health outcomes
  - Develop a behavior change plan
  - Reiterate the benefits of change

Promotion of health screening, health maintenance including self care and associated teaching

- Address environmental and interpersonal facilitators and barriers to change
- Determine the time frame for implementation
- Formalize the commitment to behavior-change plan
- Providing the health education
- Evaluation of outcomes

Lung and thorax assessment video.

Do you have any questions so far?

Please take a 15 min break

Assessment of the Breasts

- Video

Assessment of the Breasts

- Observe Breasts-
  - symmetry
  - nipple discharge and integrity
  - tenderness and masses

Breast Location & Assessment

- Location
  - Between the 2nd and 6th ribs between the sternal edge and mid-axillary line
- Methods of breast assessment
  - Inspection
  - Palpation

Breast Assessment

- Divided into four quadrants

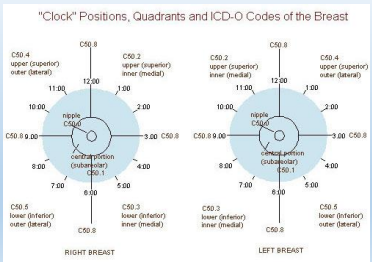

Breast Assessment

Axillary tail of Spence-Contains largest portion of glandular tissue

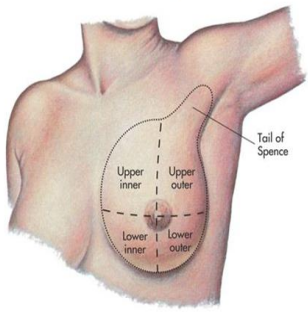

Breasts

Female:

- The largest portion of glandular tissue is located in the upper outer quadrant of each breast.
- A projection of breast tissue from the quadrant extends into axilla, called the tail of Spence.
- The majority of breast tumors are located in this upper quadrant including the tale of Spence

Male:

- Glandular tissue is located beneath each nipple (potential site for malignancy)

69

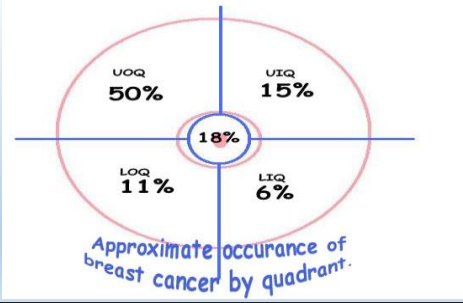

70

Current: Breast Health Guidelines

- Clinical breast exam & breast self-exam
  - Research does not show a clear benefit to clinical or self-exams
    - Currently not recommended
- Women should be familiar with how their breasts look and feel normally and report any changes to a health care provider ASAP
- **American Cancer Society 2015-2016**

71

Breast Health Guidelines

- **BEST PROTECTION IS EARLY DETECTION**
- Screening
  - "tests & exams used to find a disease in people who don't have any symptoms"
  - More likely to find breast cancers "smaller and confined to the breast"
- **American Cancer Society 2015-2016**

72

Breast Health Guideline (cont.)

- Women ages 40 to 44
  - Choice to start annual breast cancer screening with mammograms
- Women ages 45-54
  - Should get mammograms yearly
- Women ages 55 and older
  - Should switch to mammograms ever 2 years and have a choice for annual screening

(American Cancer Society 2015-2016)

73

Breast Assessment Preparation

- Explain
  - What you are going to do
  - Why
- Provide privacy
- Warm hands

74

Assessment of the Breast

- Inspect
  - Size/Symmetry
  - Shape
  - Skin discoloration
  - Nipple retraction
  - Dimpling

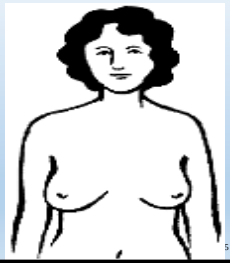

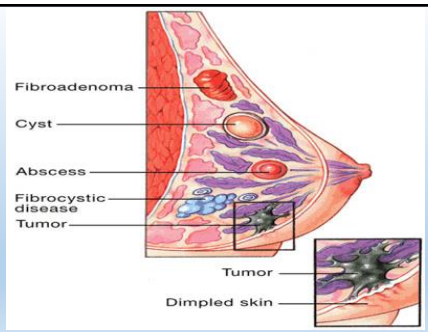

76

Inspection: Normal Findings

- Females:
  - Rounded shape, slightly unequal size, generally symmetric
- Males:
  - Breasts even with chest wall
  - If obese breast may be similar to females
- Skin uniform in color (back or abdomen)
- Skin smooth and intact

77

Inspection: Abnormal Findings

- Recent change in breast size, swelling, and marked asymmetry
- Localized discoloration or hyperpigmentation
- Nipple retraction or breast dimpling
- Localized unilateral hyper-vascular areas
  - Indicates increased blood flow
- Swelling or edema
  - Orange peel (exaggeration of the pores)

78

Nipple Retraction

79

Areola: Normal Findings

- Round or oval & bilaterally the same
- Color varies: Ethnicity
  - Light pink to dark brown
- Irregular placement of sebaceous glands
  - Montgomery's glands

80

Inspection: Nipples

- Size
- Shape
- Position
- Discharge
- Lesions

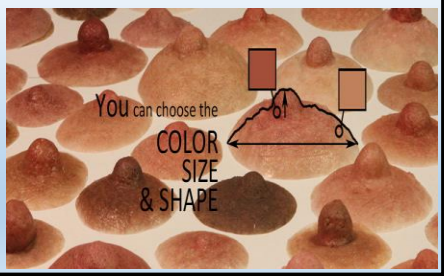

Nipples: Abnormal Findings

- Asymmetrical size and color
- Presence of discharge, crusts, or cracks
- Recent inversion of one or both nipples
  - It is Ok - if present since puberty
- Tenderness, masses, or nodules
- FYI- some medications cause nipple discharge (oral contraceptives, steroids, digitalis, and diuretics)

82

Educate your patients- Nationalbreastcancer.org



Palpation of the Breast

- Position of choice: Supine
- Choose one of three patterns for palpation
  - Hands of the clock
  - Concentric circles
  - Vertical strips pattern
- See Berman, p. 570
- Use a systematic approach to ensure all breast surfaces are assessed

Palpation of the Breast

- Palpation is done by using the flat surface of the middle three fingertips (held together) making gentle rotating motion on the breast
- Position of Choice
  - Client supine
    - Breasts flatten evenly against the chest wall
    - High risk patients examine in both supine and sitting position

85

Palpate the breast using one of the three different patterns

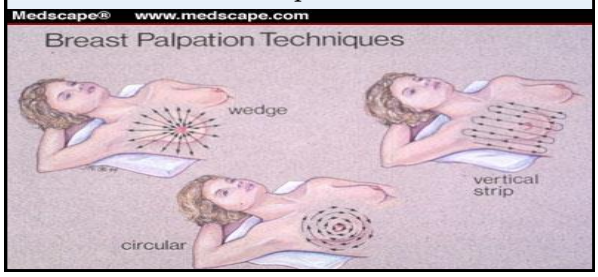

Circles Wedges Lines

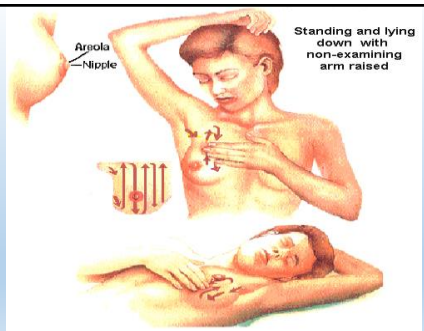

88

Normal Findings of Breast Examination

(skill 30-14)

- **Female:**
- Rounded shape, slightly unequal in size, generally symmetric
- **Male:**
- Breasts are even with the chest, if obese may be similar to female breasts
- Skin is uniform in color, smooth and intact, some Striae (stretch marks), moles and nevi considered normal

Normal Findings of Breast Examination

(skill 30-14)

- Areola : round or oval, bilaterally the same
- Color varies greatly from light pink to dark brown
- Nipples Are round, everted and equal in size, similar in color, soft and smooth, point in the same direction (out in young women and men, downwards in older women)
- No discharge, except for lactation
- Inversion of one or both nipples that is present from puberty
- On palpation-no tenderness, masses, or nodules or nipple discharge

Palpation of Axilla and Lymph Nodes

- Palpate lymph nodes
  - Axillary
  - Subclavicular
  - Supraclavicular
- Malignant cells from a breast cancer may spread directly into nodes

91

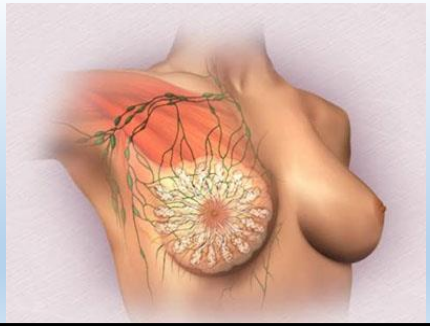

92

Abnormal Findings of Breast Examination

(skill 30-14)

- Recent change in breast size, swelling(pig skin or orange peel), marked asymmetry
- Localized discoloration or pigmentation
- Retraction or dimpling of the skin
- Unilateral localized, hyper-vascular areas
- Any asymmetry, mass, or lesion
- Asymmetrical size and color, presence of discharge, crusts, or cracks on areolas/ nipples
- Recent nipple (one or both)inversion

Detected Mass

- Document
  - Location
  - Size (cm)
  - Shape
  - Consistency (hard or soft)
  - Mobility
  - Skin over the lump (reddened, dimpled)
  - Nipple (displaced/ retracted)
  - Tenderness

94

Genetic mutations

- Mutations of BRCA1 & BRCA2 (most common)
  - Women with these mutations have up to an 80% risk of developing breast cancer during their lifetime
  - Men 1 in 10 breast Ca are believed to be due to BRCA2 mutations
  - Breastcancer.org 2012

95

Genetic Abnormalities

- Only 5-10% of cancers are due to a genetic abnormality **inherited**
- Approx. 90% of breast Cancer are due to genetic abnormalities that happen **as a result of the aging process** & "wear and tear" of life
- Breastcancer.org 2012

96

Lifespan Considerations

- Infants
  - Newborns up to 2 weeks old may have breast enlargement and white discharge from the nipples

97

Lifespan Considerations

- Children/ Adolescent
  - Female breast development occurs in 5 stages
    - Tanner's stages
  - Male
    - Gynecomastia (breast enlargement)
    - May occur in males during puberty

98

Lifespan Considerations

- Pregnant females
  - ↑ Breast size
  - Superficial veins become more prominent
  - Linear stretch marks occur
  - Colostrum
    - A thick yellow fluid may be expressed from the nipples after the first trimester

99

Lifespan Considerations

- Elderly
  - General breast size remains the same
  - Breasts change in shape
    - Become flaccid, lack firmness
  - ↓ Connective tissue
  - Glandular tissue atrophies
  - Fat tissue increases in most women

100

Cultural Considerations

- Incidence of breast cancer
  - ↑ United States, Britain & Netherlands
  - ↓ Japan, Peru, Singapore & Romania
- Research: ↑ fat diet
  - Migratory studies show when women move to US they adapt to Western diet- ↑ risk factors

101

Assessment Questions?

- Perform a breast exam monthly?
- Technique? (teaching opportunity)
- History of breast lumps, tenderness, discharge?
- Family history of breast cancer?
- Risk factors?
  - Age, diet high in fat, obesity, oral contraceptives

102

Do you have any questions so far?